Reducing Functional MR Imaging Acquisition Times by Optimizing Workflow[1]

Wilson B. Chwang, MD, PhD
Michael Iv, MD
Jason Smith, BSRT
Aleksandrs Kalnins, MD
Jake Mickelsen, BS
Roland Bammer, PhD
Dominik Fleischmann, MD
David B. Larson, MD, MBA
Max Wintermark, MD, MBA
Michael Zeineh, MD, PhD

RadioGraphics 2017; 37:316–322

Published online 10.1148/rg.2017160035

Content Code: SQ

[1]From the Department of Radiology, Stanford Health Care, Lucas Center for Imaging, 1201 Welch Rd, Room P271, Stanford, CA 94305. Presented as an education exhibit at the 2015 RSNA Annual Meeting. Received March 1, 2016; revision requested May 23 and received June 30; accepted July 27. D.B.L. and M.Z. have provided disclosures (see end of article); all other authors have disclosed no relevant relationships. **Address correspondence to** M.Z. (e-mail: *mzeineh@stanford.edu*).

Functional magnetic resonance (MR) imaging is a complex, specialized examination that is able to noninvasively measure information critical to patient care such as hemispheric language lateralization (1). Diagnostic functional MR imaging requires extensive patient interaction as well as the coordinated efforts of the entire health care team. We observed in our practice at an academic center that the times to perform functional MR imaging examinations were excessively lengthy, making scheduling of the examination difficult. The purpose of our project was to reduce functional MR imaging acquisition times by increasing the efficiency of our workflow, using specific quality tools to drive improvement of functional MR imaging. We assembled a multidisciplinary team and retrospectively reviewed all functional MR imaging examinations performed at our institution from January 2013 to August 2015. We identified five key drivers: *(a)* streamlined protocols, *(b)* consistent patient monitoring, *(c)* clear visual slides and audio, *(d)* improved patient understanding, and *(e)* minimized patient motion. We then implemented four specific interventions over a period of 10 months: *(a)* eliminating intravenous contrast medium, *(b)* reducing repeated language paradigms, *(c)* updating technologist and physician checklists, and *(d)* updating visual slides and audio. Our mean functional MR imaging acquisition time was reduced from 76.3 to 53.2 minutes, while our functional MR imaging examinations remained of diagnostic quality. As a result, we reduced our routine scheduling time for functional MR imaging from 2 hours to 1 hour, improving patient comfort and satisfaction as well as saving time for additional potential MR imaging acquisitions. Our efforts to optimize functional MR imaging workflow constitute a practice quality improvement project that is beneficial for patient care and can be applied broadly to other functional MR imaging practices.

Introduction

Background

Many quality tools can be used for the purpose of driving improvement in a diagnostic radiology department. Quality improvement can be accomplished by decreasing report turnaround times, decreasing wait times, and eliminating unnecessary steps in a workflow. Here, we report our experience using quality tools to improve functional magnetic resonance (MR) imaging workflow in our department, and we hope our model may be used in other MR imaging practices.

Functional MR imaging is a specialized, noninvasive examination of brain function that is performed clinically for preoperative neurosurgical planning (2). Brain activation is measured using blood oxygen level–dependent (BOLD) contrast, which relies on regional differences in cerebral blood flow (3). Typically, functional MR imaging is per-

TEACHING POINTS

- Functional magnetic resonance (MR) imaging is a complex, specialized examination that is able to noninvasively measure information critical to patient care such as hemispheric language lateralization. Diagnostic functional MR imaging requires extensive patient interaction as well as the coordinated efforts of the entire health care team.
- Our efforts to optimize functional MR imaging workflow constitute a practice quality improvement project that is beneficial for patient care and can be applied broadly to other functional MR imaging practices.
- The purpose of our project was to reduce functional MR imaging acquisition times by increasing the efficiency of our workflow. Our specific goal was to reduce those acquisition times from a baseline of a mean of 76 minutes to one of 60 minutes or less without sacrificing the diagnostic quality of the examinations.
- Our project was focused on reducing functional MR imaging acquisition times while maintaining diagnostic image quality, which has many potential direct and indirect benefits for patient care.
- Optimizing MR imaging workflow is an important part of our health care mission in diagnostic radiology.

formed in patients with epilepsy to determine language lateralization or in patients with structural brain lesions, such as brain tumors, to identify adjacent eloquent areas for presurgical planning (2). Extensive patient interaction is required before and during the examination; the patient is required to perform a number of motor and language tasks while inside the MR imaging unit (4).

Specific Problem

Performing a functional MR imaging examination is a complex undertaking requiring the coordinated efforts of an entire health care team. Detailed planning, preparation, and task monitoring are needed, and a protocol can be highly individualized to the needs of the patient and referring provider. The success of the examination depends on many factors, including efficient preparation and monitoring, adequate patient understanding, and the ability of the patient to follow instructions and respond appropriately during the examination. Thus, conducting this examination is more complicated than conducting a routine brain or body MR imaging examination.

Once a need for functional MR imaging is determined by the patient's neurologist or neurosurgeon (typically as a consensus recommendation by a multidisciplinary team), a neuroradiologist overseeing the study determines the protocol on the basis of the patient's lesion and the clinical information desired. Schedulers then make the appointment for an appropriate time slot (before our project, all patients were booked automatically for 2 hours). When the patient arrives for the appointment, the neuroradiologist orients the patient, and subsequently monitors the study in conjunction with a technologist. When performed optimally, functional MR imaging can produce reliable functional maps that aid greatly in planning surgery and predicting the course of recovery for these patients (5). A visual representation of our functional MR imaging workflow is shown in Figure 1.

Process That Triggered the Decision to Implement Change

In our practice, we noticed inefficiencies in our functional MR imaging workflow, which could lead to lengthy acquisition times of 2 hours or more. An excessively lengthy acquisition presents potential issues with patient cooperation, comfort, and satisfaction; the longer an acquisition runs, the greater the chance that the patient may lose focus or not be able to hold still. Also, functional MR imaging examinations that occupy a 2-hour time slot are more difficult to schedule than shorter examinations.

Purpose of This Study

The purpose of our project was to reduce functional MR imaging acquisition times by increasing the efficiency of our workflow. Our specific goal was to reduce those acquisition times from a baseline of a mean of 76 minutes to one of 60 minutes or less without sacrificing the diagnostic quality of the examinations. This was undertaken as part of a systematic quality improvement project in our department.

Methods

Ethical Compliance

Our project was submitted to our Institutional Review Board (IRB), which determined that this quality improvement project did not meet the federal definitions of "research" or "clinical investigation," and therefore did not require formal IRB review.

Study Setting

To analyze our current state, we retrospectively reviewed all functional MR imaging examinations performed at our institution from January 2013 to August 2015. All examinations were conducted on a General Electric Discovery MR750 (GE Healthcare, Waukesha, Wis) and included a structural T1-weighted inversion-recovery fast spoiled gradient-echo sequence (axial 3D BRAVO [Brain Volume Imaging] [GE Healthcare], repetition time [TR] 9.2 msec, echo time [TE] 3.7 msec, inversion time [TI] 400 msec, matrix 256 × 256 × 164, field of view 24 cm × 24 cm × 16.4 cm, 4 min 13 sec), as well as several functional MR imaging acquisitions using gradient-echo imaging (axial two-dimensional echo-planar, TR 2500

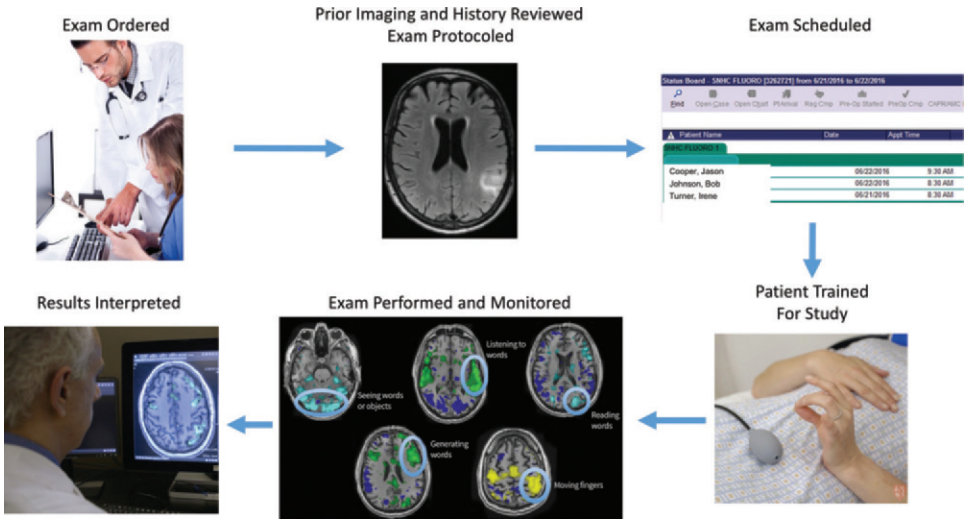

Figure 1. Visual representation of our functional MR imaging workflow. After the ordering physician enters the examination, a radiologist reviews the prior imaging and indications, and determines the best protocol to identify clinically relevant areas of brain activation so the examination can be appropriately scheduled. The patient trains with a technologist to properly perform the tasks (eg, finger tapping) immediately before the functional MR imaging. During the acquisition, the activation maps are monitored to ensure compliance and adequate performance of the tasks. Afterward, high-quality results can be interpreted.

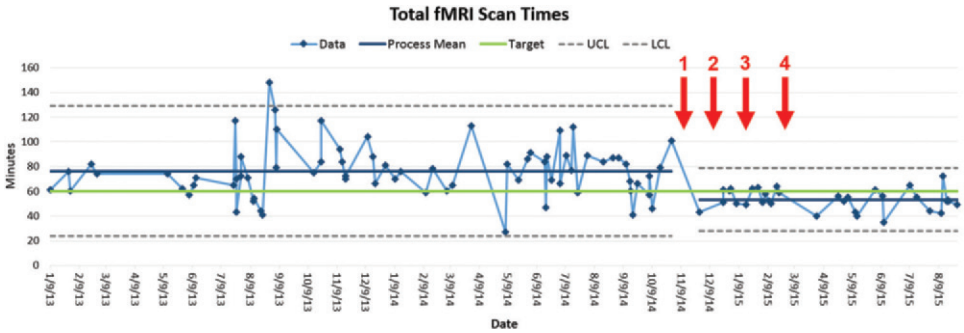

Figure 2. Annotated control chart (individual chart, or I-chart). Each individual point represents an imaging examination performed, with date on the x-axis and acquisition length in minutes on the y-axis. The preintervention and postintervention mean acquisition times (horizontal blue lines) and the goal (horizontal green line) are shown. Each of the four interventions is indicated by the time (arrows) of their implementation. *1* = eliminating intravenous contrast medium, *2* = reducing repeated language paradigms, *3* = updating technologist and physician checklist, *4* = updating visual slides and audio, *LCL* = lower control limit, *UCL* = upper control limit.

msec, TE 35 msec, matrix 64 × 64, field of view 20 cm, 3-mm section thickness, approximately 50 sections for whole-brain coverage, flip angle 83°, 4 min 5 sec). We calculated the acquisition time of each examination using acquisition times recorded in the Digital Imaging and Communications in Medicine (DICOM) header of the first image of the first sequence and last image of the last sequence, and plotted the acquisition times on a statistical process control chart (Fig 2). If additional sequences were performed as part of a research protocol, these were excluded from our calculation of the acquisition time.

Multidisciplinary Study Team

We assembled a multidisciplinary team of radiologic faculty, fellows, technologists, administrators, and quality improvement managers. The team had regular biweekly to monthly meetings from October 2014 to August 2015. Multiple cycles of *plan, do, study, act* (PDSA) (6) were conducted using standard quality improvement tools and metrics. Team members were each assigned a specific task as part of the overall project goals. Volunteers were also recruited to assist with specific project tasks.

At each meeting, progress was discussed, and group brainstorming and feedback occurred in a "culture of safety" in which collaboration and input from all members were validated and encouraged (7).

Planning

We performed a root-cause analysis using a cause-and-effect diagram (Fig 3) to visualize

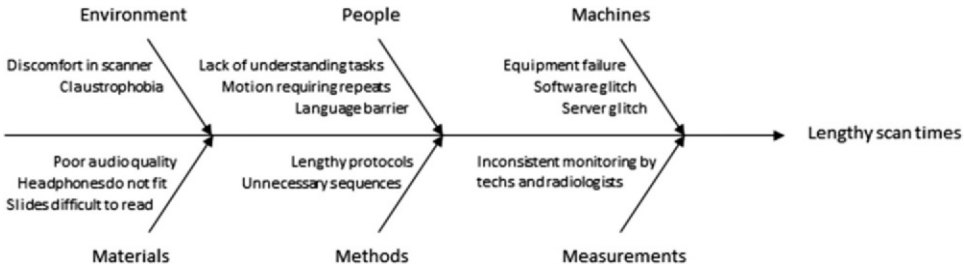

Figure 3. Cause-and-effect diagram (also known as a *fishbone diagram*) listing factors that contribute to lengthy functional MR imaging acquisition times.

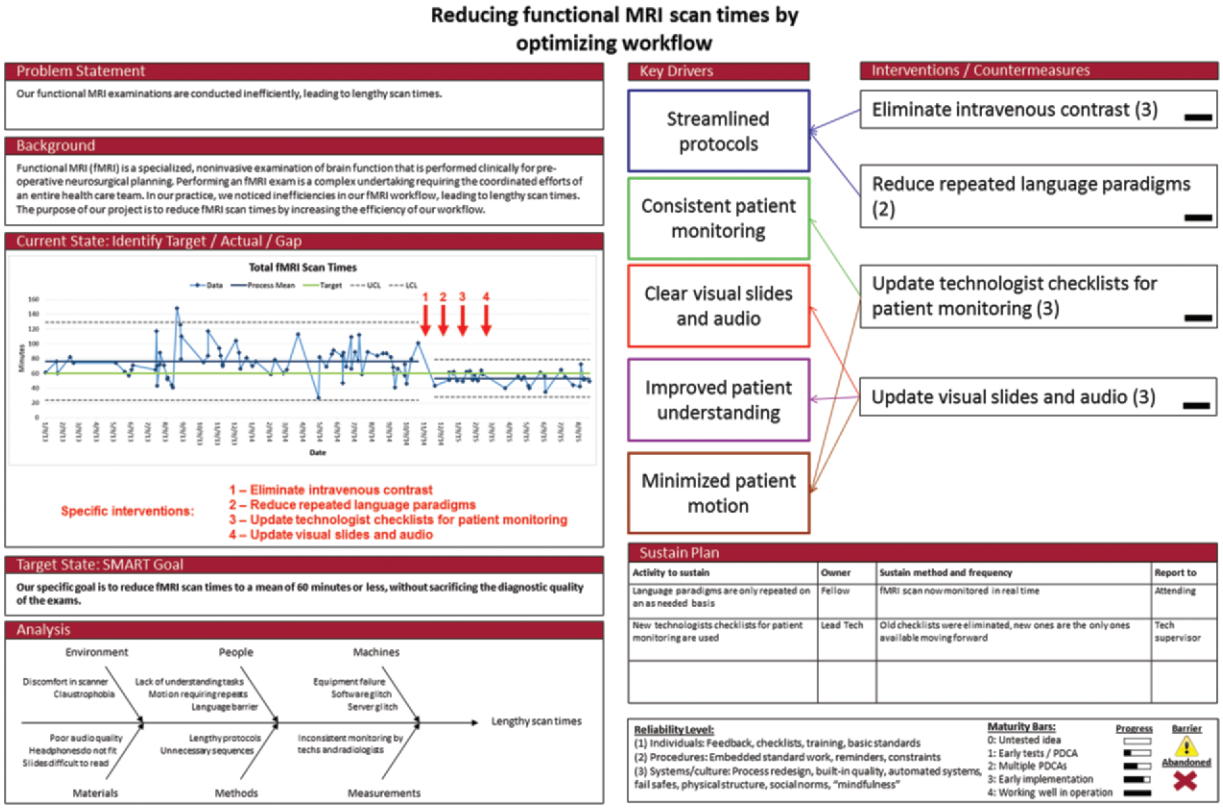

Figure 4. A3-size template diagramming the entire quality improvement process. The number in parentheses under Interventions/Countermeasures corresponds to the Reliability Level described at bottom right.

factors contributing to lengthy functional MR imaging acquisition times. The cause-and-effect diagram was derived from multiple roundtable discussion sessions in which team members made observations about the current workflow, grouping them into separate categories.

We identified five key drivers, or intermediate goals, to help guide specific interventions. These were *(a)* streamlined protocols, *(b)* consistent patient monitoring, *(c)* clear visual slides and audio, *(d)* improved patient understanding, and *(e)* minimized patient motion. To address these drivers, we performed the following specific interventions: *(a)* eliminating intravenous contrast medium, *(b)* reducing repeated language paradigms by using real-time monitoring, *(c)* updating technologist and physician checklists, and *(d)* updating visual slides and audio. Our process was diagrammed using an A3-size template (Fig 4).

Evaluation and Data Analysis

Process data were evaluated in real time using statistical process control methods to evaluate for a statistically significant change in the process mean (8). Comparison of the means and standard deviations of acquisition times before and after the interventions was performed using the Student *t* test and Bonett method, respectively. A comparison of the proportion of examinations meeting diagnostic criteria was performed using a Fisher exact test. All comparative statistical analysis was performed using Minitab statistical software (Minitab, State College, Pa).

As we implemented each of our specific interventions, we continued to track our functional MR imaging acquisition times, plotting these on our annotated control chart (Fig 2). As a balancing measure, we reviewed each examination to determine whether it was of diagnostic

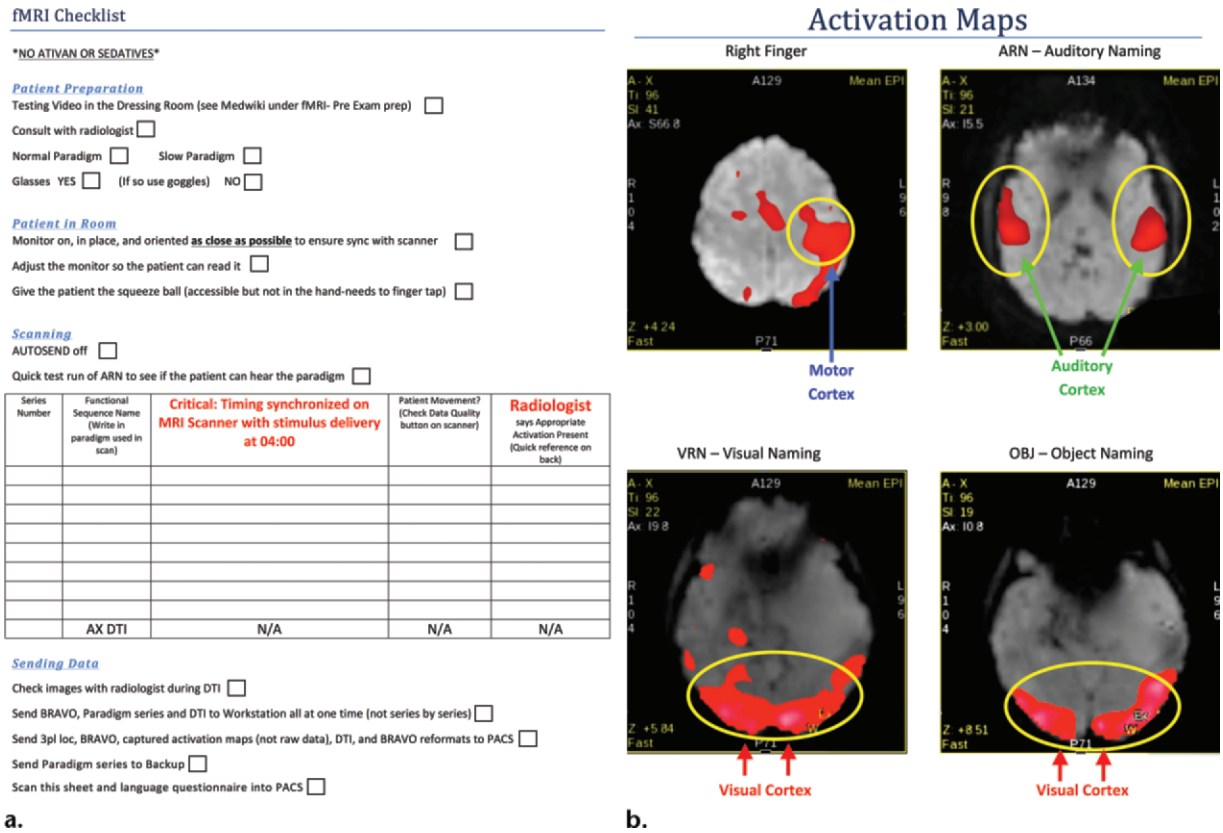

Figure 5. **(a)** Updated technologist and physician checklist, with step-by-step checkboxes. **(b)** Examples of activation maps for each of the patient tasks. *3pl loc* = three-plane localizer, *DTI* = diffusion-tensor imaging, *EPI* = echo-planar imaging, *PACS* = picture archiving and communication system.

quality, defined as whether the examination answered the primary clinical question. This was done to ensure that the quality of the examinations was not being sacrificed as acquisition times were reduced.

Implementing Interventions

Each of the interventions is described in detail in the following paragraphs.

Eliminating Intravenous Contrast Medium.—Previously, our functional MR imaging protocols had routinely included contrast medium–enhanced sequences of the brain. Although these were helpful for structural characterization, they rarely added useful information to the functional portion of the examination, as brain lesions were all generally visible without contrast medium. We eliminated postcontrast sequences from our functional protocol, opting instead to include contrast medium as part of a dedicated structural brain MR imaging examination separate from the functional imaging.

Reducing Repeated Language Paradigms by Using Real-Time Monitoring.—Previously, our functional MR imaging protocols had included visual, auditory, and object naming tasks, which were each repeated for a total of six language paradigms. We decided to reduce the number of repeat paradigms by monitoring the language maps in real time to ensure that they were of diagnostic quality. The monitoring was done by a technologist in conjunction with a physician, either a neuroradiology fellow or attending physician. The monitoring of activation maps occurred directly at the imaging unit console in real time, and was also done by having the activation maps sent to the picture archiving and communication system (PACS) in real time as each series was completed. The time for monitoring was planned at the beginning of every workday. The protocol was changed such that each patient would receive three total language paradigms, with at most one being repeated if necessary, further saving acquisition time.

Updating Technologist/Physician Checklists.—As functional MR imaging is not performed with a high frequency at our institution, parts of the radiology team may be unfamiliar with what is needed during patient monitoring, and time may be spent in looking up each of the tasks. We updated the technologist and physician checklists (Fig 5) so that the monitoring process could run more smoothly,

including checkboxes and examples of activation patterns for each task that could be checked in real time by the technologist and physician.

Updating Visual Slides and Audio.—The patient is required to read visual slides and listen to audio recordings during the functional MR imaging. If the slides or audio are unclear, the quality of the examination is compromised and time may be wasted in repeating paradigms unnecessarily. We updated the visual slides (using large font size for text) so they would be easily readable; we also rerecorded and edited the audio files to make sure they could be heard easily.

Results

Data Analysis and Outcomes

Our specific goal was to consistently reduce functional MR imaging acquisition times to less than 60 minutes. We performed 106 examinations from January 2013 to August 2015. One examination was excluded because the patient was unable to complete any of the functional tasks. For the remaining 105 examinations, the mean and median acquisition times were 69 minutes and 65 minutes, respectively, with a standard deviation of 21 minutes and a range of 27–148 minutes.

We implemented four specific interventions, which are indicated on our control chart (Fig 2). The outcomes data met criteria to indicate a shift in the process mean on November 28, 2014. Before this date, there were 72 functional MR imaging examinations, which had a mean acquisition time of 76.3 minutes and a standard deviation of 21.5 minutes. After this date, there were 33 functional MR imaging examinations, which had a mean acquisition time of 53.2 minutes and a standard deviation of 8.4 minutes. Thus, we accomplished a 30% reduction in mean acquisition time ($P < .01$) after our interventions. The standard deviation also decreased by 61% ($P < .01$).

In terms of reaching our goal of acquisition times less than 60 minutes, of the first group of 72 examinations, 13 (18%) were within our goal. Of the second group of 33 examinations, 24 (73%) were within our goal.

Of the first group of 72 examinations, 26 (36%) had contrast medium–enhanced sequences and 33 (46%) had every language paradigm repeated. Fifty-seven examinations (79%) were of diagnostic quality. The 15 nondiagnostic examinations were due to patient motion, inability to cooperate with instructions, or communication barrier. Of the second group of 33 examinations, none had contrast medium–enhanced sequences, and none had every language paradigm repeated. However, 14 (42%) had at least one paradigm repeated for either technical or diagnostic reasons. Twenty-eight examinations (85%) were of diagnostic quality. The five nondiagnostic examinations were due to patient motion, difficulty performing the tasks, or artifact from braces. The difference in the proportion of nondiagnostic quality examinations was not statistically significant ($P = .60$).

Assessment of Interventions

All of our interventions worked in concert. Although the aggregate benefit is clear, it is difficult to attribute any single reduction in acquisition time to one specific intervention. However, the elimination of intravenous contrast medium and avoidance of methodically repeating all language paradigms has clear timing benefits. Updating checklists, slides, and audio (interventions 3 and 4) presumably reduces the need for further repeats of any given paradigm, although we still repeated paradigms as needed to yield a diagnostic study.

Discussion

Summary of the Improvement, Importance, and Relevance

Efficiency in health care has been defined by the U.S. Institute of Medicine as "avoiding waste, including waste of equipment, supplies, ideas, and energy" (9). Typically, this is accomplished in a workflow by standardizing procedures and decreasing unnecessary steps, resulting in decreased time and variation in procedure length (10,11). Our project was focused on reducing functional MR imaging acquisition times while maintaining diagnostic image quality, which has many potential direct and indirect benefits for patient care. Our schedulers have reduced the allotted time for functional imaging acquisitions from 2 hours to 1 hour or 1.5 hours depending on the number of sequences protocoled and any cognitive or functional impairment of the patient, thereby making scheduling of examinations easier and leaving more time for additional potential acquisitions.

An important direct benefit is the increase in workflow efficiency. Less time is spent by radiologic personnel in conducting and monitoring the examination if there is greater familiarity with the tasks required. Patient comfort and satisfaction are increased by not having to lie in the imaging unit for an unnecessarily lengthy period. With improved training materials and guidelines, both patients and technologists begin the examination better prepared. Other potential direct benefits include increased consistency and improved image quality with less chance of patient motion.

An indirect benefit is that conducting shorter functional MR imaging acquisitions results in cost

savings. The cost of operating an MR imaging unit can be reduced if the acquisitions performed are shorter, provided the same diagnostic information is obtained. This opens the imaging unit for more examinations that can be performed in the same amount of time. Taking the results of our study, a mean time savings of 23 minutes per examination could potentially result in 19 additional hours of acquisition time over 1 year (assuming that 50 examinations are performed). Although these numbers are hypothetical, we hope that this provides a perspective on how to quantify the effect of improving efficiency, using our project as an example.

Limitations and Tradeoffs

Although our results lead us to believe that our interventions led to direct and indirect benefits for the patient, it is difficult to prove direct causality in our outcomes. Furthermore, our calculation of acquisition time does not reflect all of the time that the patient is occupying the MR imaging unit; setup and positioning time for the patient were not included, as they were not accessible from the imaging data. Additionally, the diagnostic quality of functional MR imaging as measured in this study is a subjective judgment. Finally, monitoring of the functional MR imaging real-time activation maps requires training and availability of personnel (commonly an M.D., as the examinations are billed as M.D.-present).

Plans for Sustaining and Spreading the Change

Our interventions are now being implemented permanently in our functional MR imaging workflow. The reduction of repeated paradigms will be an ongoing effort by physicians and technologists as the acquisitions are being monitored in real time. Going forward, this will be supervised by the neuroradiology attending physician and lead technologist on site for each examination.

Future directions of the project include the development of a patient training video, development of multilingual capabilities, and improving efficiency of examination monitoring, data processing, and interpretation. These can further improve our functional MR imaging pipeline from the initial order to the final report, and help maintain success toward keeping our goal of examinations less than 60 minutes. Finally, we will work with the American Society for Neuroradiology and the American Society for Functional Neuroradiology to offer our tasks and training materials for general utilization.

Conclusion

Optimizing MR imaging workflow is an important part of our health care mission in diagnostic radiology. By implementing specific interventions to improve our workflow, we reduced our mean functional MR imaging acquisition times from 76.3 to 53.2 minutes, representing a 30% reduction. At the same time, the majority of our functional MR imaging examinations remained of diagnostic quality. Although cognizant of the limitations of our study, we believe that these interventions can be sustained over time and that the process of workflow optimization can be applied broadly to other diagnostic MR imaging practices. In addition, we believe that our experience and strategy can be applied to other MR imaging efficiency aspects in general, as changes that help reduce acquisition time while maintaining diagnostic quality can help improve efficiency and success in any radiology department.

Acknowledgments.—The authors would like to acknowledge Susan Bookheimer, PhD, Darryl Costales, RT, and Teresa Nelson, RT, as significant contributors to this project.

Disclosures of Conflicts of Interest.—**D.B.L.** *Activities related to the present article:* disclosed no relevant relationships. *Activities not related to the present article:* patent licensed to GE Healthcare with potential for royalties. *Other activities:* disclosed no relevant relationships. **M.Z.** *Activities related to the present article:* disclosed no relevant relationships. *Activities not related to the present article:* grant from GE Healthcare. *Other activities:* disclosed no relevant relationships.

References

1. Bookheimer S. Pre-surgical language mapping with functional magnetic resonance imaging. Neuropsychol Rev 2007;17(2):145–155.
2. Pillai JJ. The evolution of clinical functional imaging during the past 2 decades and its current impact on neurosurgical planning. AJNR Am J Neuroradiol 2010;31(2):219–225.
3. Ogawa S, Lee TM, Kay AR, Tank DW. Brain magnetic resonance imaging with contrast dependent on blood oxygenation. Proc Natl Acad Sci U S A 1990;87(24):9868–9872.
4. Bizzi A, Blasi V, Falini A, et al. Presurgical functional MR imaging of language and motor functions: validation with intraoperative electrocortical mapping. Radiology 2008;248(2):579–589.
5. Belyaev AS, Peck KK, Brennan NM, Holodny AI. Clinical applications of functional MR imaging. Magn Reson Imaging Clin N Am 2013;21(2):269–278.
6. Moen RD, Norman CL. Circling back: clearing up myths about the Deming cycle and seeing how it keeps evolving. Qual Prog 2010;43(11):22–28.
7. Larson DB, Kruskal JB, Krecke KN, Donnelly LF. Key concepts of patient safety in radiology. RadioGraphics 2015;35(6):1677–1693.
8. Provost LP, Murray SK. The health care data guide: learning from data for improvement. San Francisco, Calif: Jossey-Bass, 2011.
9. Institute of Medicine (U.S.). Committee on Quality of Health Care in America. Crossing the quality chiasm: a new health system for the 21st century. Washington, DC: National Academies Press, 2001.
10. Shah CJ, Sullivan JR, Gonyo MB, Wadhwa A, DuBois MS. Practice policy and quality initiatives: using lean principles to improve screening mammography workflow. RadioGraphics 2013;33(5):1505–1517.
11. Kruskal JB, Reedy A, Pascal L, Rosen MP, Boiselle PM. Quality initiatives: lean approach to improving performance and efficiency in a radiology department. RadioGraphics 2012;32(2):573–587.