Utility of C-arm CT in Patients with Hepatocellular Carcinoma undergoing Transhepatic Arterial Chemoembolization

Alessia Tognolini, MD, John D. Louie, MD, Gloria L. Hwang, MD, Lawrence V. Hofmann, MD, Daniel Y. Sze, MD, PhD, and Nishita Kothary, MD

PURPOSE: To evaluate the utility of C-arm computed tomography (CT) on treatment algorithms in patients undergoing transhepatic arterial chemoembolization for hepatocellular carcinoma (HCC).

MATERIALS AND METHODS: From March 2008 to July 2008, 84 consecutive patients with HCC underwent 100 consecutive transhepatic arterial chemoembolizations with iodized oil. Unenhanced and iodinated contrast medium–enhanced C-arm CT with planar and three-dimensional imaging were performed in addition to conventional digital subtraction angiography (DSA) in all patients. The effect on diagnosis and treatment was determined by testing the hypotheses that C-arm CT, in comparison to DSA, provides (*a*) improved lesion detection, (*b*) expedient identification and mapping of arterial supply to a tumor, (*c*) improved characterization of a lesion to allow confident differentiation of HCC from pseudolesions such as arterioportal shunts, and (*d*) an improved evaluation of treatment completeness. The effect of C-arm CT was analyzed on the basis of information provided with C-arm CT that was not provided or readily apparent at DSA.

RESULTS: C-arm CT was technically successful in 93 of the 100 procedures (93%). C-arm CT provided information not apparent or discernible at DSA in 30 of the 84 patients (36%) and resulted in a change in diagnosis, treatment planning, or treatment delivery in 24 (28%). The additional information included, amongst others, visualization of additional or angiographically occult tumors in 13 of the 84 patients (15%) and identification of incomplete treatment in six (7.1%).

CONCLUSIONS: C-arm CT is a useful collaborative tool in patients undergoing transhepatic arterial chemoembolization and can affect patient care in more than one-fourth of patients.

J Vasc Interv Radiol 2010; 21:339–347

Abbreviations: DSA = digital subtraction angiography, HCC = hepatocellular carcinoma, 3D = three-dimensional

THE incidence of hepatocellular carcinoma (HCC) in North America has doubled during the past 2 decades and now accounts for approximately 18,000 deaths per year (1). The overwhelming majority of patients cannot undergo resection due to advanced disease or poor liver function (2,3). Surgical resection in patients with early-stage disease provides 5-year survival rates of 50%–70% (2,3), but the recurrence rate is high. Liver transplantation can both eradicate the tumor and treat the underlying liver disease. However, even in patients suitable for liver transplantation, tumor progression and scarcity of donor organ supply lead to a dropout rate of 20%–50% (3–5). Local-regional therapies such as ethiodized oil-based transhepatic arterial chemoembolization (chemoembolization) can delay tumor progression in patients awaiting transplantation (6,7) or increase survival in patients not suitable for transplantation (8,9).

With increased awareness of HCC, at-risk patients are being screened early and often (10,11). Treatment is offered earlier in the disease process, often for focal disease (12,13). The technique for chemoembolization has also evolved, resulting in increased utilization of targeted selective catheterization and drug delivery to maximize response and minimize collateral damage (12–16). With the adoption of catheter-based techniques requiring technically difficult catheterization, the need for hybrid angiographic imaging platforms that exploit the advantages of other modalities such as computed tomography (CT) and positron emission tomography has correspondingly increased. C-arm CT is one such modality.

From the Division of Interventional Radiology, Stanford University Medical Center, 300 Pasteur Dr, H3652, Stanford, CA 94305-5642. Received April 19, 2009; final revision received November 5, 2009; accepted November 6, 2009. **Address correspondence to** N.K.; E-mail: kothary@stanford.edu

From the 2009 SIR annual meeting.

A.T. and N.K. have research grants from Siemens Healthcare. None of the other authors have identified a conflict of interest.

© SIR, 2010

DOI: 10.1016/j.jvir.2009.11.007

Table 1
Summary of Patient Demographics

Parameter	Value
No. of patients	84
No. of chemoembolizations with C-arm CT	100
Mean patient age (y)	61.1 (18–88)
Sex	
M	74
F	10
No. of patients with a history of chemoembolization	23
Mean no. of prior chemoembolizations	2.3 (1–6)
Mean interval between diagnostic CT/MR imaging and study chemoembolization (d)	28.8 (4–67)

Note.—Numbers in parentheses are ranges.

Digital subtraction angiography (DSA) remains the default modality for guidance of chemoembolization, but the use of cross-sectional technology such as cone-beam CT mounted on an angiography unit, hence termed C-arm CT, is rapidly increasing (17–19). With use of the principles of cone-beam CT, C-arm CT has the ability to acquire three-dimensional (3D) volume-rendered images with soft tissue contrast as well as multiplanar or maximum intensity projection reconstructions of the hepatic arteries that provide crucial navigational information for superselective catheterization (20–22). C-arm CT was first developed for application in neurointerventional procedures (23,24). With improvements in technology, availability of flat-panel detectors, and improvements in image quality, C-arm CT has found applications for abdominal interventions (17–19,25,26). In particular, the ability to discern hypervascular and some hypovascular lesions in multiple planes and the ability to reconstruct a 3D anatomic roadmap of the vascular supply to a tumor(s) has proved to be of benefit in treating hepatic malignancies (18,20,21,27).

On the basis of the early published data from our institution and others, we decided to evaluate the utility of C-arm CT in a large cohort of patients undergoing chemoembolization for HCC, studying 100 consecutive procedures to overcome selection bias. We investigated a standardized chemoembolization protocol that included C-arm CT and chronicled the complementary and additive information provided with C-arm in addition to that provided with DSA.

MATERIALS AND METHODS

This was a retrospective, single-institution study that was compliant with the Health Insurance Portability and Accountability Act. Institutional review board exemption was obtained.

From March 2008 to July 2008, 84 consecutive patients with unresectable HCC underwent 100 consecutive chemoembolization procedures at our institution. Patient demographics are summarized in **Table 1**. The cohort included 74 men and 10 women aged 18–84 years (mean age, 61.1 years). All patients were suspected of having or confirmed to have HCC on the basis of clinical history, underlying liver disease and/or viral infection, characteristic cross-sectional imaging findings of enhancement of the tumor at the arterial phase and wash-out at the venous phase of a contrast medium–enhanced diagnostic cross-sectional study such as a triphasic CT or multiphasic magnetic resonance (MR) imaging, and/or elevated α-fetoprotein level. Pretreatment cross-sectional imaging included multiphasic MR imaging in 14 patients, triphasic CT in 83, and both in three. Before treatment, patients were discussed at a multidisciplinary liver tumor board, and baseline laboratory data and images were reviewed.

Tumors were characterized as "focal" if the patient had a single tumor less than or equal to 6.5 cm in the greatest axial diameter or three or fewer tumors with a total tumor diameter of less than or equal to 8 cm, with the largest tumor less than or equal to 4.5 cm in the greatest axial diameter. Patients with more than three tumors were considered to have multifocal disease. Patients with tumor(s) larger than 6.5 cm, although technically stage A with the Barcelona Clinic Liver Cancer Staging Classification, can often present like patients with multifocal disease, with several segmental arteries supplying the tumor, and they often need nonsuperselective, lobar chemoembolizations. Hence, this patient population was grouped along with patients with multifocal disease for the purposes of data analysis. Of the 100 procedures, 70 (62 patients) were performed for focal disease (mean tumor size, 2.5 cm; range, 1–6.3 cm) and 30 (26 patients) were performed for multifocal disease or tumors larger than 6.5 cm. In four patients, the disease progressed from focal disease at the time of the initial chemoembolization to multifocal disease at the subsequent chemoembolization. The interval between the most recent diagnostic cross-sectional study and chemoembolization was recorded (mean, 28.9 days; range, 4–67 days). The number of previous chemoembolizations was also recorded and is listed in **Table 1**.

All chemoembolization procedures were performed by board-certified interventional radiologists using a standardized protocol in a C-arm CT–capable uniplanar interventional suite (Siemens AXIOM Artis Dta ceiling mounted system; Siemens AG, Healthcare Sector, Forchheim, Germany) with a 30 × 40-cm flat-panel detector. C-arm CT scan acquisition and 3D image rendering were performed by using commercially available software (DynaCT, Siemens AG, Healthcare Sector). Image processing and 3D rendering were performed at the time of the procedure on a Syngo-X Workstation using Syngo InSpace 3D and Syngo DynaCT algorithms (Siemens AG, Healthcare Sector).

Patients underwent moderate sedation with intravenous midazolam and fentanyl, monitored by a registered nurse. Antiemetics and contrast medium–related prophylactic medications (corticosteroids, antihistamines, bicarbonate infusions) were administered as needed.

Abdominal aortography was performed in all patients by using a pigtail or Omniflush catheter (AngioDynamics, Queensbury, New York) positioned in the lower thoracic aorta (approximately T8 level) to facilitate complete hepatic angiography, including identification of extrahepatic supply to the hepatic tu-

mor(s) (eg, via inferior phrenic, omental, or intercostal arteries). A 4- or 5-F Cobra catheter or a reversed curve catheter such as a Simmons or Sos Omni catheter (AngioDynamics) was used to select the common or the proper hepatic artery. Complete hepatic arteriography with DSA was performed at standardized obliquities (anteroposterior and 30° right anterior oblique) with adequate contrast medium boluses to maximize the parenchymal enhancement of malignancies. In patients with complex or tortuous vascular anatomy, additional obliquities were obtained at the operator's discretion. Replaced or accessory hepatic arteries as well as extrahepatic supply were identified and selectively imaged when present.

After DSA, iodinated contrast–enhanced C-arm CT with injection into the common or proper hepatic artery (or into the main right or left hepatic artery in variant anatomy) was performed in all patients. Twelve-second injections were performed at a rate low enough to prevent reflux, with a 4-second imaging delay. Images were sent to a dedicated workstation for 3D image reconstructions, which were analyzed in real time. If a patient had a history of chemoembolizations, unenhanced C-arm CT was performed before the contrast–enhanced study to allow the operator to differentiate areas of residual ethiodized oil uptake from areas of tumor enhancement.

Subsequently, a coaxial microcatheter was advanced through the 4- or 5-F catheter with a micro-guide wire. In patients with focal tumors, the microcatheter was advanced into segmental or subsegmental branches to perform superselective chemoembolization. DSA images and contrast-enhanced C-arm CT scans were obtained to verify maximally selective arterial catheterization and to confirm supply to the target tumor, at the operator's discretion. For tumors that were supplied by more than one segmental or subsegmental artery, multiple superselective catheterizations were performed to achieve complete treatment. Similarly, extrahepatic vessels that looked suspicious for supplying the tumor(s) were selected and imaged. In patients with multifocal disease or single massive tumors, a microcatheter was advanced into the lobar branch and lobar treatment performed.

Chemoembolization was performed as previously described (15,16) by using an emulsion consisting of ethiodol (Savage Laboratories, Melville, New York) and cisplatinum and/or doxorubicin suspended in contrast medium (Omnipaque 300; Amersham/GE Healthcare, Fairfield, Connecticut). A maximum of 20 mL of ethiodized oil, 50 mg of cisplatinum, and 50 mg of doxorubicin were administered at any single session. The emulsion was injected through the microcatheter until uptake in the tumor was complete or stasis in the feeding vessel was achieved.

After the administration of the chemotherapeutic agents, unenhanced C-arm CT scans were obtained in all patients to assess the pattern and completeness of ethiodized oil uptake in the target tumors. Additional unenhanced C-arm CT scans to monitor ethiodized oil uptake during drug delivery were obtained at the operator's discretion in situations where there was uncertainty of targeted delivery. Incomplete uptake of ethiodized oil by the tumor demonstrated at unenhanced C-arm CT was suggestive of more than one arterial feeder and prompted additional selective catheterizations of other possible feeding vessels.

Image Acquisition

The C-arm CT acquisition protocol included an 8-second rotational scan of 210° and 26° rotation per second, image acquisition every 0.5° for a total of 419 images, 512 × 512-voxel matrix, source power of 125 kVp, and receiver dose of approximately 0.36 μGy per frame. Contrast-enhanced acquisitions were obtained by using dilute iodinated contrast medium (Omnipaque 300 or Visipaque 320; Mallinckrodt, St Louis, Missouri) diluted to 150 or 160 mg/mL iodine concentration (50% concentration) with an equal volume of normal saline solution. Initial contrast-enhanced images with injection of the common or proper hepatic artery were acquired by injecting 2 mL/sec for a fixed duration of 12 seconds (total, 24 mL) with an x-ray delay of 4 seconds. Injection rates for subsequent enhanced acquisitions from more selective catheterizations varied according to vessel caliber and flow from 0.1 to 1.5 mL/sec, with a fixed injection duration of 12 seconds and an x-ray delay of 4 seconds.

Projectional images were sent to a dedicated Syngo-X workstation for 3D image reconstruction using Syngo InSpace (3D volume rendering) and Syngo DynaCT (cone-beam CT) options. Image correction algorithms were applied for scatter, beam hardening, ring artifact, and truncation. Images were manipulated by the operator by adjusting slab thickness, obliquity, segmentation, and window and level and by using surface-rendering or maximal intensity projection reformations. An in-depth description of the technical details has been previously reported (17,22).

In addition to real-time image interpretation, all C-arm CT scans and corresponding DSA images were retrospectively reviewed by an author (N.K.). Thee-dimensional mapping and cross-sectional image manipulation were recreated and re-analyzed for each study and cross-checked with the original reported procedural sequence and decision-making algorithm.

Image and Outcome Analysis

Lesion detection was based on visual interpretation. On the basis of our clinical experience with transarterial hepatic interventions, our previous data about the effect of CT hepatic arteriography (28) on the detection of angiographically occult HCC, and our initial experience with C-arm CT, we developed four hypotheses describing how imaging data obtained with C-arm CT could provide additional information to that obtained with DSA alone and directly affect treatment planning and treatment delivery.

These hypotheses are as follows:

1. C-arm CT increases the sensitivity of the detection of occult lesions, including (*a*) lesions unidentified at preprocedural cross-sectional imaging and intraprocedural DSA, and (*b*) lesions previously identified at preprocedural cross-sectional imaging but not apparent at DSA.
2. C-arm CT improves identification and characterization of arterial supply to a tumor, including (*a*) recognizing parasitized extrahepatic vessels supplying the tumor(s) (eg, inferior phrenic artery); (*b*) revealing perfusion of a nontarget vascular bed such as the stomach, duodenum, pancreas, diaphragm, or omentum, the treatment of which would result in nontarget embolization; (*c*) providing 3D mapping and navigation to allow accurate catheterization of branches supplying the tumor in sit-

uations where DSA was disadvantaged by tortuous and/or overlapping branches; and (*d*) isolating viable regions of contrast enhancement within previously treated areas obscured by ethiodized oil retention and depicting branch vessels leading to these isolated regions.

3. C-arm CT is a problem-solving tool that can help differentiate pseudolesions (eg, arterioportal shunts) from HCC. With the present platform, arterial contrast-enhanced C-arm CT uses the combination of 3D spatial resolution and high contrast resolution to help the operator discern between pseudolesions and HCCs.
4. C-arm CT provides superior assessment of completeness of treatment, including(*a*) identifying tumors that had multiple segmental arteries supplying them due to the location of the tumor in "watershed" regions such as segments I, IV, VIII, and V. Even though these tumors were small (≤4 cm), the location of the tumor itself resulted in shared arterial supply; and (*b*) depicting an incomplete 3D uptake pattern of chemoembolic material not detected with projectional imaging.

The utility of C-arm CT was determined by comparing the information provided with C-arm CT to that available with DSA and/or preprocedural cross-sectional imaging. Although pathologic correlation would be ideal for lesion characterization with absolute certainty, this is frequently impossible in patients with HCC. Hence, for lesions that were visualized at C-arm CT but not apparent on the preprocedural cross-section images or the DSA images, the following methods were used to confirm the nature of the lesion. Spherical, nonperipheral lesions that enhanced at C-arm CT were either treated with chemoembolization or monitored with short-interval follow-up cross-sectional imaging. Treated lesions that demonstrated dense accumulation of ethiodized oil during chemoembolization were considered to be HCCs. Lesions monitored with short-interval follow-up imaging (within 8 weeks) were considered to be HCCs if they demonstrated arterial enhancement and washout in the venous phase, increased in size on the follow-up cross-sectional images, or confirmed at biopsy.

Information provided with C-arm CT was considered significant only if it was unique and exclusive of information derived from DSA. In patients in whom C-arm CT provided information to support multiple hypotheses, details were recorded for each. In addition to measuring utility by each one of the above hypotheses, we analyzed the data to report the number of patients in whom C-arm CT resulted in the following: (*a*) information that was actionable and had a direct effect on diagnosis and/or treatment planning and/or treatment delivery (referred to as "essential"), and (*b*) information that was useful but did not change the outcome or treatment delivery (referred to as "useful").

Table 2
Information Provided with C-arm CT

Information	No. of Procedures (n = 100)	No. of Patients (n = 84)
Tumor detection (additional/angiographically occult)	14	14 (17)
Extrahepatic supply	2	2 (2.4)
Identification of nontarget perfusion	1	1 (1.2)
Identification of viable portions in tumors with dense ethiodized oil	2	2 (2.4)
Navigation	8	8 (9.5)
Characterization of pseudolesions	2	2 (2.4)
Evaluating dual supply in watershed tumors and/or complete geographic uptake in the tumor	6	6 (7.1)

Note.—In six procedures (six patients), C-arm CT provided information in two areas. Numbers in parentheses are percentages.

RESULTS

C-arm CT was technically successful in 93 of the 100 procedures. In two patients, C-arm CT could not be performed due to a software malfunction, and in five patients the quality of the C-arm CT scans was poor due to respiratory motion artifacts. DSA images were also suboptimal, but due to the modality's capability of remasking and reregistering images to a certain extent, it provided more information than C-arm CT in these patients.

Data analysis based on the abovementioned four criteria demonstrated that C-arm CT provided additional information that was not available at DSA in 30 of the 100 procedures (30%) (30 of 84 patients, 36%). Information supporting two or more hypotheses during a single procedure (eg, additional lesion and vascular anatomy) was provided in six of these 30 procedures (20%). The following are details regarding the testing of the hypotheses, which are also summarized in **Table 2**:

1. Detection of occult lesions: Overall, C-arm CT resulted in an increased detection rate in 14 of the 84 patients (17%). C-arm CT depicted additional lesions in eight of the 84 patients (9.5%) that were not apparent on the intraprocedural DSA images or the preprocedural cross-sectional images (**Fig 1**). In another six patients (7.1%), C-arm CT was able to depict and localize tumors that were visible at preprocedural cross-sectional imaging but not at DSA (angiographically occult) (**Fig 2**).
2. Identification and characterization of arterial supply to a tumor: Overall, C-arm CT provided unique vascular anatomic information in 13 of the 84 patients (15%). C-arm CT depicted a parasitized extrahepatic vessel supplying the tumors in two of the 84 patients (2.4%). In one additional case (1.2%), C-arm CT enabled the operator to recognize an extrahepatic, nontarget region of perfusion (small area of gastric wall) that was supplied by a branch of the vessel supplying the tumor. Recognition of this branch and the resultant further superselectivity of catheterization reduced the risk of nontarget embolization. In eight of the 84 patients (9.5%), identification of the origin of the branch vessel supplying the tumor was not possible with the two DSA views obtained due to tortuous and/or overlapping branches. In these cases, 3D mapping facilitated

a. b. c. d.

Figure 1. Angiographically occult tumor in a 75-year-old man with HCC secondary to hepatitis C. **(a)** Preprocedureal contrast-enhanced CT scan obtained in the arterial phase demonstrates a hypervascular tumor in segment VIII (arrow) but does not demonstrate any clear evidence of a hypervascular tumor in segment III. **(b)** DSA image (anteroposterior projection) obtained during contrast medium injection into the common hepatic artery demonstrates the hypervascular tumor in segment VIII (arrow). No lesions are detected in the left lobe. **(c)** Late-phase DSA image (right anterior oblique projection) obtained after common hepatic artery injection confirms the same (arrow). **(d)** C-arm CT scan obtained during injection of the common hepatic artery demonstrates a segment III lesion (large arrow) that was not visualized at DSA. The segment VIII lesion is also seen (small arrow).

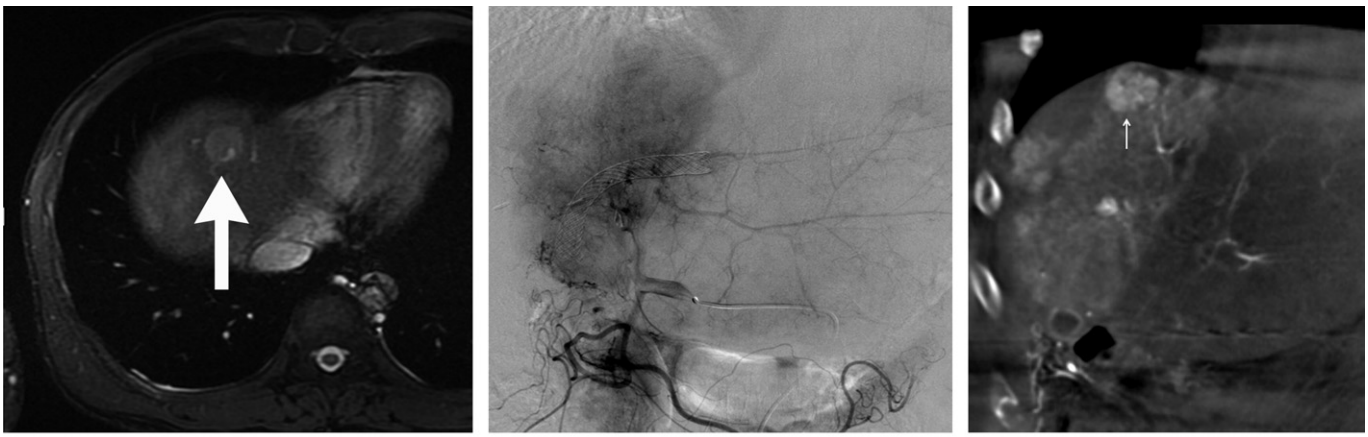

a. b. c.

Figure 2. Angiographically occult tumor in a 39-year-old with HCC secondary to hepatitis B. **(a)** T2-weighted preprocedural contrast-enhanced MR image reveals a hypervascular tumor (arrow) in segment IV. **(b)** DSA image during proper hepatic artery injection fails to demonstrate the segment IV tumor. **(c)** Coronal reformatted image from C-arm CT performed during injection of the proper hepatic artery clearly demonstrates the segment IV lesion (arrow) as well as another hypervascular lesion in the right lobe.

navigation and selective catheterization, decreasing the amount of contrast medium injected and the multiple obliquities that would have otherwise been required to obtain the same information with DSA alone (**Fig 3**). In two of the 84 patients (2.4%), C-arm CT helped identify viable portions of a tumor and the vascular supply to that part of the tumor in patients who had undergone prior chemoembolization and whose tumors were characterized by dense but incomplete ethiodized oil retention (**Fig 4**).

3. Pseudolesions: In one case (1.2%), C-arm CT was able to demonstrate that a lesion believed to be a tumor on the preprocedural cross-sectional images was in fact an arterioportal shunt. In one other patient (1.2%), C-arm CT was able to help differentiate a small lesion that densely accumulated ethiodized oil (interpreted to be HCC) from an adjacent area of arterioportal shunting, although this did not affect the technique or outcome.
4. Last, although C-arm CT was helpful in assessing completeness of treatment in all technically successful patients, this information proved crucial in six of the 84 patients (7.1%). In these six patients, the tumors were in watershed regions and C-arm CT either was able to two or more segmental branches supplying the tumor or helped identify an incomplete 3D uptake pattern of chemoembolic material not detected with projectional imaging, triggering additional selective catheterizations and chemoembolization.

We further analyzed the data to determine how the information derived from C-arm CT affected diagnosis, treatment planning, or treatment delivery and whether this information was essential or useful as defined above. For patients in whom information from C-arm CT contributed in multiple ways (eg, lesion detection and navigation), only the most valuable information was tallied. Details are summarized in **Table 3**. C-arm CT provided essential information in 24 of the 100 procedures (24%) in 24 of the 84 patients (28%). In brief, these included 13 patients (15%) with additional tumors or angiographically occult tumors and six (7.1%) with watershed lesions where C-arm CT identified additional tumor supply. Other patients in whom

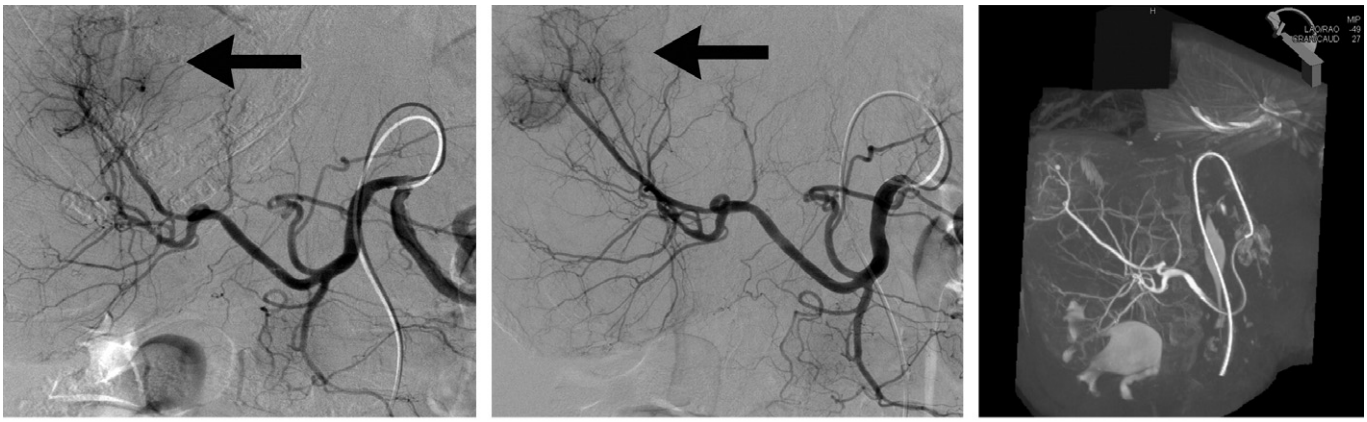

a. b. c.

Figure 3. C-arm CT is used to guide selection of a segment VII vessel feeding a solitary tumor in a 78-year-old woman with HCC secondary to hepatitis C. **(a,b)** C-arm CT scans obtained during injection of the common hepatic artery in the anteroposterior **(a)** and right anterior oblique **(b)** projections demonstrate tortuosity of the origin of the vessel feeding the tumor (arrow indicates the tumor). **(c)** Maximum intensity projection image from C-arm CT with right hepatic artery injection reveals the steep oblique and craniocaudal angulation that best lays out the vessel.

C-arm CT provided essential information included one with parasitized extrahepatic supply, one with an angiographically obscured accessory gastric vessel, one in whom the lesion in question was proved to be an arterioportal shunt, and two patients with prior dense ethiodized oil staining in whom C-arm CT helped identify enhancing portions of the tumor.

C-arm CT provided useful but not essential information in six of the 100 procedures (6%) in six of the 84 patients (7.1%). These included confirming navigational plans in five patients and identification of an occult lesion in one patient in whom the procedural techniques and outcomes were not substantially changed.

DISCUSSION

DSA is capable of unsurpassed temporal resolution and in-plane spatial resolution but is limited by the lack of soft tissue contrast and also by its projectional, non-3D images. CT offers the advantages of producing a 3D dataset of higher contrast resolution. To obtain the best arterial phase images with CT, contrast medium must be injected directly into the hepatic artery, a technique called CT hepatic arteriography (28–31). In a study published by Sze et al (28), CT hepatic arteriography performed at chemoembolization was shown to change the diagnosis, procedure planning, and/or delivery in 30% of patients. This technique required transport of patients between DSA and CT suites, was time-intensive and cumbersome, and did not allow iteration. With the development of C-arm CT technology where DSA and CT images can be produced with the same hardware, CT hepatic arteriography can now be performed without moving the patient (21,27,32).

The present study was undertaken to evaluate the role C-arm CT can play in this complex patient group when used with conventional DSA. The results of our study support earlier findings on CT hepatic arteriography (28) and C-arm CT applied to hepatic interventions (27). C-arm CT provided essential information not available with DSA in 24% of chemoembolizations in 28% of our patients, similar to that reported by Wallace et al (27). In our study, C-arm CT had a substantial effect on the identification of additional lesions or angiographically occult lesions not identified at DSA, underscoring the advantage of C-arm CT's ability to provide CT-like soft tissue images with high soft tissue and contrast resolution. Present day conventional cross-sectional imaging has high sensitivity; however, it is limited for small lesions that are difficult to characterize in patients with cirrhosis, in obese patients, and in patients that have abdominal hardware that causes streak artifact. Although, the spatial and contrast resolution of C-arm CT is inferior to that of conventional multidetector CT, it offers the advantage of imaging during a hepatic arterial injection without the necessity of moving the patient. Similarly, some lesions may be hard to visualize at DSA if they are hypovascular or are in patients with advanced cirrhosis who often have patchy perfusion and arterioportal shunts that make it difficult to identify the tumor itself confidently. Contrast–enhanced C-arm CT plays an important problem-solving role in such cases due to its high spatial resolution in three dimensions.

A second advantage of C-arm CT is the acquisition of a volumetric dataset, resulting in the ability to reconstruct images in multiple planes. The 3D dataset is of particular importance in patients with tumors that lie on major segmental boundaries such as where segment IV meets the medial portion of segment VIII, which we have given the term "watershed" region tumors. These tumors, even if small in size, are often supplied by multiple segmental branches from the right, left, and/or middle hepatic arteries and sometimes even directly from the common or proper hepatic artery (33,34). The multiplanar view as well as the 3D image rendering of the hepatic vasculature can help identify and display the multisegmental blood supply to these tumors. More important, unenhanced C-arm CT can help identify an incomplete 3D uptake pattern of chemoembolic material not detected with projectional imaging, triggering additional selective catheterizations and chemoembolization. Comparison of the prechemoembolization contrast–

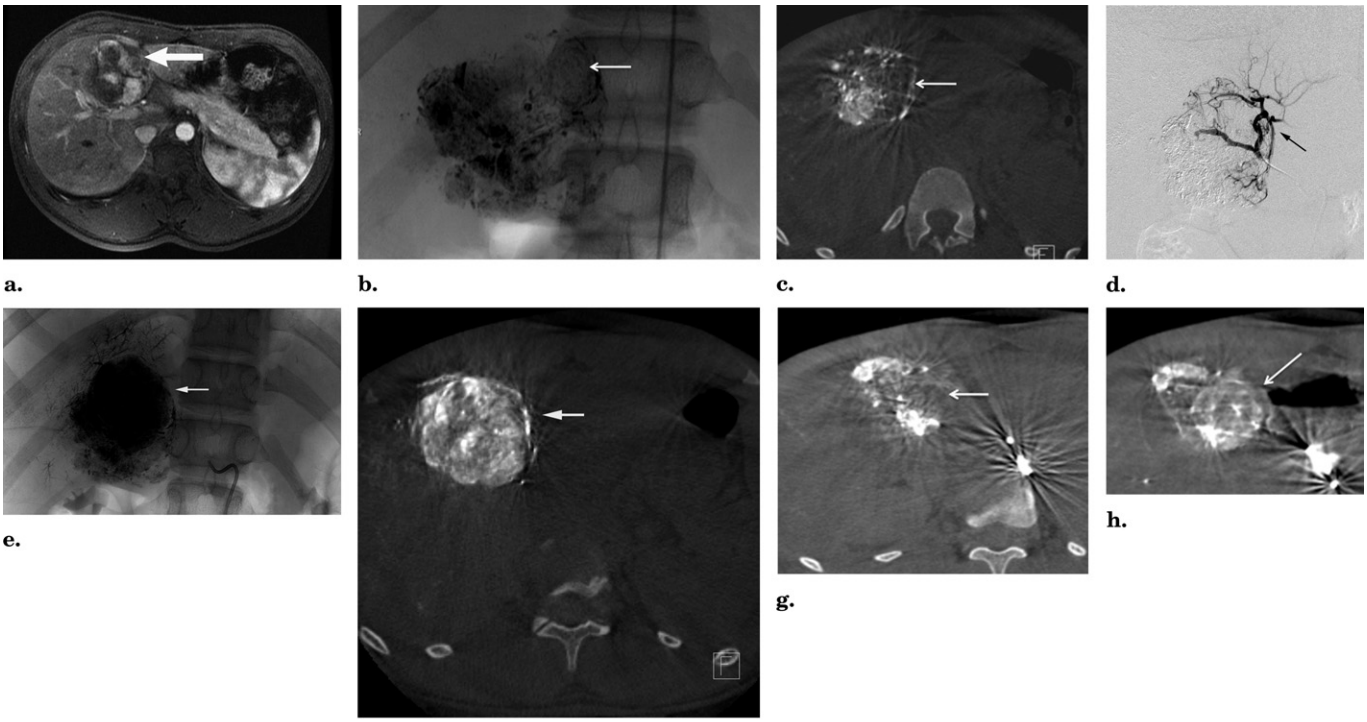

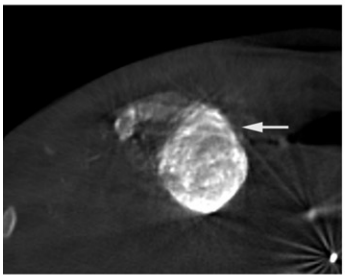

Figure 4. C-arm CT demonstrates an area of incomplete chemoembolization in an 18-year-old man who had undergone multiple prior chemoembolizations for a large solitary HCC. **(a)** Single image from the arterial phase of preprocedural MR imaging demonstrates nodular areas of residual enhancement (arrow) in the tumor. **(b,c)** Digital image **(b)** and unenhanced C-arm CT scan **(c)** obtained before catheterization of the hepatic artery demonstrate retained ethiodized oil from two previous chemoembolizations with paucity of staining in the medial aspects of the tumor (arrow). **(d)** Selective arteriogram of the segment IV branch demonstrates enhancing residual tumor along the medial aspect (arrow). **(e,f)** After selective chemoembolization to a branch of the segment IV artery, a single digital image **(e)** and an unenhanced C-arm CT scan **(f)** demonstrate dense accumulation of ethiodized oil in the superior portion of the tumor (arrow). **(g)** The relative lack of staining along the inferomedial aspect of the tumor (arrow) was better depicted on the postchemoembolization unenhanced C-arm CT scan. **(h,i)** An additional arterially contrast-enhanced C-arm CT scan obtained after superselective catheterization **(h)** reveals residual tumor enhancement in the inferomedial aspect (arrow), leading to additional treatment to completeness as demonstrated by the dense accumulation of ethiodized oil (arrow) on the final unenhanced C-arm CT scan **(i)**.

enhanced C-arm CT scans with the postchemoembolization unenhanced C-arm CT scans can increase operator confidence in the adequacy of spatially targeted therapy. This advantage is accentuated in patients who have undergone previous chemoembolization treatments and have dense ethiodized oil retention, obscuring areas of contrast enhancement at projectional imaging that represent residual viable tumor.

The third advantage of using C-arm CT is the navigational tool provided with 3D volumetric mapping to allow accurate superselective catheterization in situations where DSA is disadvantaged by tortuous and/or overlapping branches. Although the data provided with this tool are not necessarily unique, this tool may reduce the need for multiple DSA acquisitions in multiple projections in an attempt to lay out the vessels and may therefore reduce the total amount of radiation exposure, procedural time, and contrast medium utilization.

The advantages of C-arm CT come with their own caveats: potentially increased radiation dose, contrast medium volume, and procedural time and the need for patient cooperation for a longer breath-hold. The radiation dose delivered during a single C-arm CT acquisition is greater than that delivered during a single DSA acquisition. However, unlike DSA, the skin dose of C-arm CT is distributed over 200° because of the rotational nature of the acquisition. Moreover, a single C-arm CT has the possibility of yielding the same information as multiple DSA acquisitions in technically challenging cases. C-arm CT, when performed in addition to standard DSA, adds to the total volume of contrast medium administered. However, as is true with radiation dose arguments, a single C-arm CT may offer equivalent or even more information than multiple DSA acquisitions. In addition, the contrast medium used for C-arm CT is diluted to 50% concentration to decrease streak artifact and, hence, is responsible for a fractional increase in

Table 3
Essential Information Provided with C-arm CT that Had a Direct Effect on Diagnosis and/or Treatment Planning and Delivery

Information	No. of Patients (n = 84)
Tumor detection (additional/angiographically occult)	13 (15)
Extrahepatic supply	1 (1.2)
Identification of nontarget perfusion	1 (1.2)
Identification of viable portions in tumors with dense ethiodized oil	2 (2.4)
Characterization of pseudolesions	1 (1.2)
Evaluating dual supply in watershed tumors and/or complete geographic uptake in the tumor	6 (7.1)
Total	24 (28)

Note.—Numbers in parentheses are percentages.

the overall volume administered. Last, previous reports found that the use of C-arm CT can increase the procedural time (27). With the increase in the number of C-arm CT acquisitions performed at our institution, we have developed a standard patient set-up to simplify and expedite the steps necessary to switch between DSA and C-arm CT acquisitions. Newer versions of software have also resulted in significantly improved reconstruction times, and increasing familiarity with postprocessing tools has resulted in improved physician efficiency at image processing and analysis. Although we did not record the procedural time data for this retrospective study, presently the average amount of time required to set up the acquisition, obtain the rotational run, and reconstruct the data is about 3 minutes.

A major limitation of this study is that it was structured to analyze the advantage of C-arm CT over DSA and not vice versa. We strongly believe that DSA and C-arm CT are complementary to each other and that each modality has its own advantages that can be used collaboratively to problem solve in complex cases. Because DSA is an established modality, the purpose of our study was to understand the role of C-arm CT in these cases. Another limitation is the lack of pathologic correlation in patients where additional lesions or pseudolesions were noted. Unfortunately, obtaining pathologic verification in this patient population is often difficult; hence, we used ethiodized oil accumulation or short-term follow-up imaging to determine the nature of the lesion. Other limitations of this study include its retrospective nature, the interoperator variations, the heterogeneity of the patient/tumor population, and the time lapse between the diagnostic cross-sectional study and the treatment delivery.

To overcome a selection bias, we analyzed the data in 100 consecutive procedures that included patients with focal and multifocal disease. However, the utility of C-arm CT in patients with multifocal disease is limited because of the decreased need for catheter superselectivity and for future studies; we will study the two groups separately. In addition, the utility of C-arm CT specifically in patients listed for liver transplantation should also be evaluated because of its greater sensitivity and its potential effect on candidacy assessment. We are also now in the process of prospectively collecting data regarding radiation dose and procedure duration.

Despite these limitations, we have established that C-arm CT can provide crucial information during hepatic chemoembolizations that may not be available at DSA and can lead to a change in diagnosis, treatment planning, and/or treatment delivery. Further studies will lead to a better understanding of patient selection, radiation dose minimization, and DSA substitution for this modality that is becoming an integral part of hepatic interventions.

References

1. American Cancer Society. Cancer facts and figures 2008: American Cancer Society. 2008 [updated 2008; cited]; Available from: http://www.cancer.org/downloads/STT/2008CAFFfinalsecured.pdf. Accessed April 21, 2008.
2. Bruix J, Llovet JM. Prognostic prediction and treatment strategy in hepatocellular carcinoma. Hepatology 2002; 35:519–524.
3. Llovet JM, Fuster J, Bruix J. Intention-to-treat analysis of surgical treatment for early hepatocellular carcinoma: resection versus transplantation. Hepatology 1999; 30:1434–1440.
4. Yao FY, Bass NM, Nikolai B, et al. Liver transplantation for hepatocellular carcinoma: analysis of survival according to the intention-to-treat principle and dropout from the waiting list. Liver Transpl 2002; 8:873–883.
5. Llovet JM, Mas X, Aponte JJ, et al. Cost effectiveness of adjuvant therapy for hepatocellular carcinoma during the waiting list for liver transplantation. Gut 2002; 50:123–128.
6. Majno PE, Adam R, Bismuth H, et al. Influence of preoperative transarterial lipiodol chemoembolization on resection and transplantation for hepatocellular carcinoma in patients with cirrhosis. Ann Surg 1997; 226:688–701, discussion 701–683.
7. Graziadei IW, Sandmueller H, Waldenberger P, et al. Chemoembolization followed by liver transplantation for hepatocellular carcinoma impedes tumor progression while on the waiting list and leads to excellent outcome. Liver Transpl 2003; 9:557–563.
8. Lo CM, Ngan H, Tso WK, et al. Randomized controlled trial of transarterial lipiodol chemoembolization for unresectable hepatocellular carcinoma. Hepatology 2002; 35:1164–1171.
9. Llovet JM, Real MI, Montana X, et al. Arterial embolisation or chemoembolisation versus symptomatic treatment in patients with unresectable hepatocellular carcinoma: a randomised controlled trial. Lancet 2002; 359:1734–1739.
10. Zhang BH, Yang BH, Tang ZY. Randomized controlled trial of screening for hepatocellular carcinoma. J Cancer Res Clin Oncol 2004; 130:417–422.
11. Arguedas MR, Chen VK, Eloubeidi MA, Fallon MB. Screening for hepatocellular carcinoma in patients with hepatitis C cirrhosis: a cost-utility analysis. Am J Gastroenterol 2003; 98:679–690.
12. Murakami R, Yoshimatsu S, Yamashita Y, Sagara K, Arakawa A, Takahashi M. Transcatheter hepatic subsegmental arterial chemoembolization therapy using iodized oil for small hepatocellular carcinomas: correlation between lipiodol accumulation pattern and local recurrence. Acta Radiol 1994; 35:576–580.
13. Takayasu K, Muramatsu Y, Maeda T, et al. Targeted transarterial oily chemoembolization for small foci of hepatocellular carcinoma using a unified helical CT and angiography system: analysis of factors affecting local recurrence and survival rates. AJR Am J Roentgenol 2001; 176:681–688.

14. Kothary N, Weintraub JL, Susman J, Rundback JH. Transarterial chemoembolization for primary hepatocellular carcinoma in patients at high risk. J Vasc Interv Radiol 2007; 18:1517–1526, quiz 1527.
15. Ha BY, Ahmed A, Sze DY, et al. Long-term survival of patients with unresectable hepatocellular carcinoma treated with transcatheter arterial chemoinfusion. Aliment Pharmacol Ther 2007; 26:839–846.
16. Kim P, Prapong W, Sze DY, So SK, Razavi MK. Treatment of hepatocellular carcinoma with sub-selective transcatheter arterial oily chemoinfusion. Tech Vasc Interv Radiol 2002; 5:127–131.
17. Wallace MJ, Kuo MD, Glaiberman C, Binkert CA, Orth RC, Soulez G. Three-dimensional C-arm cone-beam CT: applications in the interventional suite. J Vasc Interv Radiol 2008; 19: 799–813.
18. Hirota S, Nakao N, Yamamoto S, et al. Cone-beam CT with flat-panel-detector digital angiography system: early experience in abdominal interventional procedures. Cardiovasc Intervent Radiol 2006; 29:1034–1038.
19. Meyer BC, Frericks BB, Albrecht T, Wolf KJ, Wacker FK. Contrast-enhanced abdominal angiographic CT for intra-abdominal tumor embolization: a new tool for vessel and soft tissue visualization. Cardiovasc Intervent Radiol 2007; 30:743–749.
20. Wallace MJ. C-arm computed tomography for guiding hepatic vascular interventions. Tech Vasc Interv Radiol 2007; 10:79–86.
21. Virmani S, Ryu RK, Sato KT, et al. Effect of C-arm angiographic CT on transcatheter arterial chemoembolization of liver tumors. J Vasc Interv Radiol 2007; 18:1305–1309.
22. Fahrig R, Dixon R, Payne T, Morin RL, Ganguly A, Strobel N. Dose and image quality for a cone-beam C-arm CT system. Med Phys 2006; 33:4541–4550.
23. Missler U, Hundt C, Wiesmann M, Mayer T, Bruckmann H. Three-dimensional reconstructed rotational digital subtraction angiography in planning treatment of intracranial aneurysms. Eur Radiol 2000; 10: 564–568.
24. Benndorf G, Strother CM, Claus B, et al. Angiographic CT in cerebrovascular stenting. AJNR Am J Neuroradiol 2005; 26:1813–1818.
25. Kakeda S, Korogi Y, Ohnari N, et al. Usefulness of cone-beam volume CT with flat panel detectors in conjunction with catheter angiography for transcatheter arterial embolization. J Vasc Interv Radiol 2007; 18:1508–1516.
26. Sze DY, Strobel N, Fahrig R, Moore T, Busque S, Frisoli JK. Transjugular intrahepatic portosystemic shunt creation in a polycystic liver facilitated by hybrid cross-sectional/angiographic imaging. J Vasc Interv Radiol 2006; 17:711–715.
27. Wallace MJ, Murthy R, Kamat PP, et al. Impact of C-arm CT on hepatic arterial interventions for hepatic malignancies. J Vasc Interv Radiol 2007; 18:1500–1507.
28. Sze DY, Razavi MK, So SK, Jeffrey RB Jr. Impact of multidetector CT hepatic arteriography on the planning of chemoembolization treatment of hepatocellular carcinoma. AJR Am J Roentgenol 2001; 177:1339–1345.
29. Hori M, Murakami T, Kim T, Nakamura H. Diagnosis of hepatic neoplasms using CT arterial portography and CT hepatic arteriography. Tech Vasc Interv Radiol 2002; 5:164–169.
30. Hori M, Murakami T, Oi H, et al. Sensitivity in detection of hypervascular hepatocellular carcinoma by helical CT with intra-arterial injection of contrast medium, and by helical CT and MR imaging with intravenous injection of contrast medium. Acta Radiol 1998; 39:144–151.
31. Kanematsu M, Hoshi H, Murakami T, et al. Detection of hepatocellular carcinoma in patients with cirrhosis: MR imaging versus angiographically assisted helical CT. AJR Am J Roentgenol 1997; 169:1507–1515.
32. Orth RC, Wallace MJ, Kuo MD. C-arm cone-beam CT: general principles and technical considerations for use in interventional radiology. J Vasc Interv Radiol 2008; 19:814–820.
33. Rhee TK, Omary RA, Gates V, et al. The effect of catheter-directed CT angiography on yttrium-90 radioembolization treatment of hepatocellular carcinoma. J Vasc Interv Radiol 2005; 16: 1085–1091.
34. Lewandowski RJ, Sato KT, Atassi B, et al. Radioembolization with ^{90}Y microspheres: angiographic and technical considerations. Cardiovasc Intervent Radiol 2007; 30:571–592.