



<http://dx.doi.org/10.1016/j.jemermed.2017.01.002>

## **Ultrasound in Emergency Medicine**

### **ULTRASOUND-ASSISTED REMOVAL OF A FISHBONE STUCK IN A TONGUE IN THE EMERGENCY DEPARTMENT**

David Kanon, MD,\* Paige Skinner, BS,\* William A. Kennedy III, MD,† and Angela R. Cirilli, MD\*

\*Department of Emergency Medicine and †Ear, Nose and Throat, Long Island Jewish Medical Center, New Hyde Park, New York  
 Corresponding Address: Angela R. Cirilli, MD, Department of Emergency Medicine, Long Island Jewish Medical Center, 270-05 76th Avenue,  
 New Hyde Park, NY 11040

□ **Abstract—Background:** Foreign body (FB) impaction in the oropharyngeal region—and specifically the tongue—is a common problem in the emergency department that often requires specialty consultation and admission for operative intervention. Over the years, the use of point of care ultrasound (POCUS) has increased ease and success of FB removal in other anatomic regions, but is only rarely reported for extraction of FB from the tongue outside of the operating room. **Case Report:** This case demonstrates a unique case of ultrasound-guided removal of a fishbone from the tongue in the emergency department after blind attempts failed. Operative intervention and admission were initially avoided; however, because of initial failed attempts and blind dissection before the use of POCUS, the patient presented a day later requiring admission for postprocedural tongue swelling and edema. **Why Should an Emergency Physician Be Aware of This?:** Emergency physicians should be aware that POCUS may assist in FB localization in the tongue. © 2017 Elsevier Inc. © 2017 Elsevier Inc. All rights reserved.

□ **Keywords—**emergency medicine; emergency ultrasound; foreign bodies; point of care ultrasound

### **INTRODUCTION**

Impacted foreign bodies (FBs) in the oropharyngeal region are common in the emergency department and can present challenges in accurate localization for removal. Point of care ultrasound (POCUS) assistance for FB identification and removal in other areas of the body has grown over the more traditional methods of radiography and computed tomography (CT) because of the many advantages in soft-tissue FB detection and improved ability to detect radiolucent FBs (1–3). Although superior to radiography, ultrasound (US) has a wide range of reported sensitivities from 30% to 95% for detecting nonradiopaque foreign bodies with 50% to 90% specificity in studies looking at animal model chicken thighs and hand FBs (1,2,4,5). Extraction of FBs from the oropharyngeal region, however—especially the tongue—faces unique challenges compared to other anatomic regions because of the proximity to vital structures and limited access points during extraction, in addition to concerns for postprocedural swelling, edema, and even subsequent airway compromise (6).

POCUS is unique in that it is portable, does not expose the patient to radiation, and can be used for real-time localization of a FB at the time of removal (7). POCUS can provide intraprocedural guidance that CT and radiography cannot (8). This case shows the expanded use of POCUS for FB removal to include fishbone removal from the tongue. This case highlights potential

Reprints are not available from the authors.

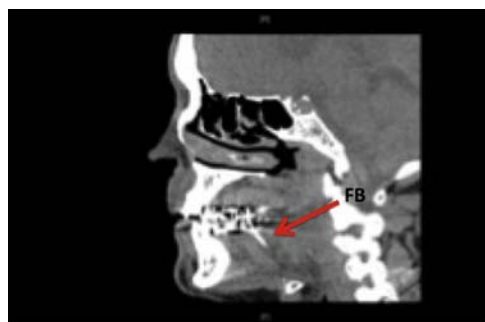RECEIVED: 22 September 2016; FINAL SUBMISSION RECEIVED: 13 December 2016;  
 ACCEPTED: 4 January 2017

complications unique to extraction of FBs from the tongue, and emphasizes the potential for POCUS to decrease this risk.

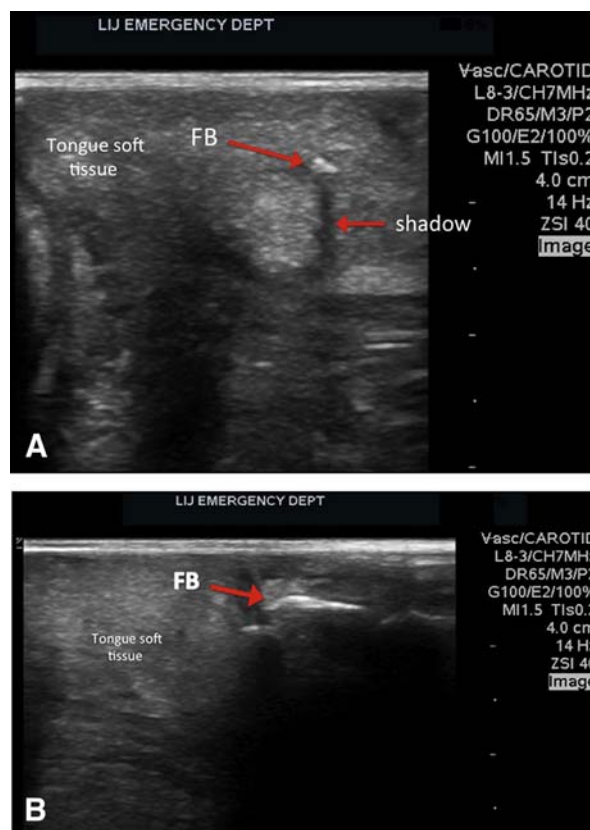
### CASE REPORT

A 62-year-old man presented to the emergency department with the complaint of a FB stuck in the tongue. The patient was eating a bony fish when a piece of bone stuck into his tongue, and then broke while he was trying to remove it. Because of persistent FB sensation, he presented to the emergency department (ED). In the ED, his physical examination was significant for mild swelling to the tongue, but no visualized FB and an otherwise normal oropharyngeal examination. A CT scan was performed that did show a FB body in the shape of a small bone lodged in the tongue (Figure 1). An ear, nose and throat (ENT) physician was called to evaluate the patient at the bedside for FB removal. In an attempt to avoid admission and operative scheduling, initial blind attempts were made to extract the FB in the ED. Although CT had confirmed the presence of a FB, attempts at blunt dissection failed to localize the FB. It was then that the emergency physician using a Zonare ultrasound machine and a L8-3 MHz, high-frequency linear transducer performed POCUS to assist in the extraction. Together, a two-physician technique with the emergency physician holding the US probe was used to localize the fishbone. The fishbone appeared as a hyperechoic, linear structure with posterior shadowing, as seen in Figure 2A (transverse view) and 2B (long view) about 1 cm below the superior surface of the tongue.

With POCUS, the fishbone was localized in a different region from the initial superior surface incision and dissection area. A new incision was made under dynamic US guidance with a more lateral and inferior approach. The ENT physician was able to locate the fishbone and remove it at the ED bedside on first attempt with POCUS. After the procedure, the patient was successfully discharged home with instructions for close follow-up.



**Figure 1.** Computed tomography scan showing a foreign body (FB) fishbone appearing vertically, embedded in the tongue.



**Figure 2.** Within the soft tissue of the tongue, a hyperechoic foreign body (FB)—in this case, a fishbone—is seen showing posterior shadowing approximately 1 cm from the surface of the tongue in both (A) transverse and (B) sagittal views.

One day after discharge, the patient returned to the ED with significant swelling to the tongue, poor ability to tolerate food or liquids, and was subsequently admitted for observation. He required no further intervention, however, other than fluids, pain control, and steroids to help reduce swelling, and he was discharged after 24 hours without airway compromise and was feeling much better.

### DISCUSSION

This is a unique case report using ED POCUS to facilitate removal of a small fishbone from a tongue. POCUS is well established for FB removal from other anatomic locations. There are only a few cases, however, describing intraoperative US guidance for FB removal from the oropharyngeal region, and only one prior published report of POCUS to guide removal of a metallic wire from the tongue while in the ED (9–12). Although many types of FBs can become impacted in the oropharyngeal region, such as wires, air gun pellets, teeth, and pipe material, fish bones are the most commonly reported tongue FBs (13). Most are superficial, but occasionally they may be embedded deep into the tongue and nonpalpable as seen in this case.

Postoperative swelling and inflammation or hematoma is a known potential complication of tongue FB extraction because of the type of tissue, number of attempts and incisions made, and the necessary blunt dissection used for localization when POCUS is not used. Although this patient was discharged home after successful extraction using US, he returned with tongue swelling on day 2. It is unclear whether the use of US at the initiation of the procedure could have decreased the number of blind attempts and further decreased the amount of postprocedural edema.

Although CT or radiography is often used to detect oropharyngeal FBs, this case highlights the ease of detection of a small intralingual fishbone on US, and demonstrates the superiority of US to CT for its ability to guide intraprocedural extraction in the ED.

### WHY SHOULD AN EMERGENCY PHYSICIAN BE AWARE OF THIS?

POCUS can successfully detect and help localize a small impacted tongue fishbone and provide intraprocedural guidance for extraction in the ED.

### REFERENCES

1. Aras MH, Miloglu O, Barutcugil C, Kantarci M, Ozcan E, Harorli A. Comparison of the sensitivity for detecting foreign bodies among conventional plain radiography, computed tomography and ultrasonography. *Dentomaxillofac Radiol* 2010;39:72–8.
2. Manthey DE, Storrow AB, Milbourn JM, Wagner BJ. Ultrasound versus radiography in the detection of soft-tissue foreign bodies. *Ann Emerg Med* 1996;28:7–9.
3. Ginsburg MJ, Ellis GL, Flom LL. Detection of soft-tissue foreign bodies by plain radiography, xerography, computed tomography, and ultrasonography. *Ann Emerg Med* 1990;19:701–3.
4. Turkuerc I, Atilla R, Topacoglu H, et al. Do we really need plain and soft-tissue radiographies to detect radiolucent foreign bodies in the ED? *Am J Emerg Med* 2006;24:763–8.
5. Bradley M, Kadzombe E, Simms P, Eyes B. Percutaneous ultrasound guided extraction of non-palpable soft tissue foreign bodies. *Emerg Med J* 1992;9:181–4.
6. de Santana Santos T, Avelar RL, Melo AR, de Moraes HHA, Dourado E. Current approach in the management of patients with foreign bodies in the maxillofacial region. *J Oral Maxillofac Surg* 2011;69:2376–82.
7. Lucas E, Ruiz-Delgado M, García-Barón P, Sádaba P, Pagola MA. Foreign esophageal body impaction: multimodality imaging diagnosis. *Emerg Radiol* 2004;10:216–7.
8. Ng SY, Songra AK, Bradley PF. A new approach using intraoperative ultrasound imaging for the localization and removal of multiple foreign bodies in the neck. *Int J Oral Maxillofac Surg* 2003;32:433–6.
9. Smith ME, Riffat F, Berman LH, et al. Intraoperative ultrasound to facilitate removal of a submucosal foreign body. *J Clin Ultrasound* 2014;42:565–8.
10. Nariai Y, Yanai C, Kondo S, et al. A fish bone in the tongue: a report of a case. *J Oral Maxillofac Surg* 2010;22:30–2.
11. Sharma PK, Songra AK, Ng SY. Intraoperative ultrasound-guided retrieval of an airgun pellet from the tongue: a case report. *Br J Oral Maxillofac Surg* 2002;40:153–5.
12. Pigott DC, Buckingham RB, Eller RL, Cox AJ. Foreign body in the tongue: a novel use for emergency department ultrasonography. *Ann Emerg Med* 2005;45:677–9.
13. Jones NS, Lannigan FJ, Salama NY. Foreign bodies in the throat: a prospective study of 388 cases. *J Laryngol Otol* 1991;105:104–8.