

A Systematic Approach to the Evaluation and Management of the Failed Artificial Urinary Sphincter

Amy D. Dobberfuhr¹ · Craig V. Comiter¹

Published online: 23 February 2017
© Springer Science+Business Media New York 2017

Abstract In men with post-prostatectomy incontinence, persistent or recurrent urinary leakage following artificial urinary sphincter placement is a frustrating complaint. Surgical failure can be classified as occurring early in the post-operative period vs. late—following a period of established continence—and should be managed according to the time course and severity of urinary leakage. We present a systematic approach for the evaluation and treatment of the failed artificial urinary sphincter. After considering the patient's individualized treatment goals and impact on quality of life, the clinician can more appropriately advise patients on a management strategy for their recurrent or persistent urinary incontinence following artificial urinary sphincter placement.

Keywords Artificial urinary sphincter · Equipment failure · Incidence · Overactive urinary bladder · Prostatectomy · Prostatic neoplasms

Abbreviations

AUS Artificial urinary sphincter
ISD Intrinsic sphincter deficiency
PPI Post-prostatectomy incontinence
PRB Pressure regulating balloon
SUI Stress urinary incontinence

This article is part of the Topical Collection on *Female Urology*

✉ Craig V. Comiter
ccomiter@stanford.edu

Amy D. Dobberfuhr
adobber@stanford.edu

¹ Department of Urology, Stanford University School of Medicine, 300 Pasteur Drive, S-287, Stanford, CA 94305, USA

Introduction

The artificial urinary sphincter and the male sling are the two most common procedures for treating male intrinsic sphincter deficiency (ISD) in men with post-prostatectomy (PPI) urinary incontinence [1]. If a patient has persistently bothersome stress urinary incontinence (SUI) due to ISD despite 12 months of active conservative management, then operative intervention is indicated. When contemplating surgery, the risks of surgery must be considered against the severity of leakage, the magnitude of the adverse effect on the patient's quality of life, and the ability of the patient to conservatively manage incontinence (with penile clamp, incontinence pads, condom catheter, lifestyle modification, etc.).

Both the artificial urinary sphincter (AUS) and the male sling function by addressing the underactive outlet via increased resistance to urinary flow during storage. The two procedures, however, are not necessarily interchangeable. Both the male sling and the AUS share a common mechanism of action: resistance to leakage is created by applying pressure on a length of urethra, distal to the sphincter, and by either the sling mesh or the AUS cuff. As these forces are applied, compression can embarrass blood supply to that urethral segment, and urethral ischemia may result—especially with the application of circumferential compression. Therefore, it is important to consider how to optimize urethral compression while minimizing the risk of urinary retention or compromising urethral viability. Given the mechanical limitations of non-circumferential compression, the male sling tends to be indicated for patients with more mild to moderate leakage. Compressive slings (whether adjustable or non-adjustable) should be offered only to those with preserved bladder contractility, which is necessary to overcome the fixed resistance of the device. In patients with mild to moderate

degrees of leakage but with detrusor underactivity, a non-compressive repositioning (retroluminal/ transobturator) sling would be more appropriate. In patients with more severe leakage, or in those who have had external beam radiation or failed prior incontinence surgery, regardless of bladder contractility, the AUS is often a more efficacious treatment option.

As expected with any mechanical device, long-term success of the AUS is dependent on both the device and the surrounding tissue. Efficacy of the AUS is finite and subject to both atrophy and even breakdown of the urethral tissue. Component failure is not rare and can include loss of elasticity of the pressure regulating balloon (PRB) and fluid leak from the PRB, tubing (including connections), cuff, or pump. Additional complications include device infection and erosion into the lower urinary tract. Failure of the AUS can be divided into early, which is occurring less than 30 days following implantation vs. late.

Incidence and Etiology of AUS Revision Surgery

Just as reported rates of incontinence following prostate cancer surgery depend on the definition of incontinence and method of evaluation, continence rates with the AUS can vary with the definition of continence and the method of evaluation. While pad-free rates following AUS implantation can range from 10 to 72% [2–7], higher satisfaction rates of 87 to 90% are consistently reported, even in the absence of achieving total continence [3, 8, 9]. When based upon a social continence definition of zero to one pad per day, the success rates for AUS generally ranges from 59 to 90% [2, 8–17].

In contrast to the high initial success rate of the AUS, one should expect the need for periodic revisions in a substantial minority of patients. Revision and explantation rates due to mechanical failure or urethral atrophy and infection or erosion vary considerably among studies, with reports of 8 to 45% and 7 to 17%, respectively. In a large cohort reported by Lai and colleagues, non-mechanical failure has decreased from 17 to 9% and mechanical failure from 21 to 8% following introduction of the narrow back cuff in the late 1980s, with a mean time to reoperation of 26.2 months (range 2 to 68 months) [18]. On Kaplan-Meier analysis, the overall 5-year expected product survival was 75%. Only 6% of devices failed mechanically, at an average of 68.1 months, with 75% of patients requiring no revisions at 5 years. Actuarial freedom from revision at 5 years was estimated at 50 to 75%. Whereas the male sling has been shown to have inferior success rates in patients with severe leakage [19], the AUS has been reported to have predictable success regardless of the degree of incontinence and regardless of detrusor hypocontractility, detrusor overactivity, low abdominal leak point pressure, or diminished

compliance. And while the success of the AUS in treating incontinence is not adversely affected by preoperative detrusor overactivity, the rate of persistent overactive bladder symptoms may be high (71%), and patients must be counseled accordingly [18].

The long-term efficacy of the AUS was demonstrated by Fulford et al. who reported that at 10 to 15 years of follow-up, 75% of patients with an implanted AUS either still had or died with a functioning device [20]. Revisions include replacement of the malfunctioning part, cuff replacement, repositioning or downsizing due to urethral atrophy, a second or tandem cuff [21, 22], or transcorporal cuff placement [23]. Transcorporal cuff placement, which involves inserting the cuff through the corporal bodies to avoid perforating the dorsal aspect of the urethra, can be particularly useful for patients with prior radiation or urethral erosion; however, potency, if present, may be compromised. Some have advocated tandem cuffs not only as a salvage procedure but also as a primary procedure for men with severe incontinence [24, 25]. However, O'Connor et al. reported no difference in continence outcome and a higher revision rate in patients undergoing double-cuff implant compared to single-cuff after longer follow-up [26].

There are specific urodynamic risk factors for sling failure, including the presence of a short functional urethral length, a low maximal urethral closure pressure, and a low abdominal leak point pressure [27]. In contrast, there do not appear to be any urodynamic factors that predict AUS failure in men with ISD. Prior radiation treatment, however, may indeed predict a higher need for surgical revision [2, 11, 28]. A recent report demonstrated that the relative risk of erosion is significantly higher in those who had radiotherapy compared to those who did not (RR 4.05, 95% CI 1.1–15.3) [29]. Despite improvements in radiation technique and equipment, this risk of erosion has not diminished [29]. Continence results in radiated patients reported in the literature are variable with some studies showing lower success rates [10, 28] while others do not [6]. A recent report on AUS implantation in patients with a “fragile urethra” (history of radiation, prior urethroplasty or prior AUS) noted that outcomes are similar to those reported for low-risk patients—with continence achieved in 77%, improvement in 97%, and explantation secondary to erosion in only 7% [30]. For those patients, however, it is generally recommended that a lower pressure reservoir is implanted and/or a longer period of deactivation is employed [2].

Thus, the AUS remains the most predictably successful surgery for the treatment of PPI secondary to sphincteric insufficiency in patients with severe incontinence and in those who have had external beam radiation treatment or other risk factors for urethral fibrosis. The long-term success rates and high patient satisfaction seem to outweigh the need for periodic revisions in a substantial minority of patients.

Evaluation and Management

Early Failure

While the success rate for AUS placement is generally quite high, there are occasional instances where adequate continence is not achieved upon device activation. Early failure or persistent incontinence may result from several causes (Table 1).

Cuff Size Is Too Large

If the urethral cuff placed initially is too large, then insufficient coaptation of the urethra under the AUS cuff will result in persistent incontinence [31]. The rate of persistent incontinence has decreased substantially since the introduction of the 3.5 cm cuff in 2010. Simhan et al. from the University of Texas demonstrated a decrease in persistent leakage from 22% in the 3 years prior to 2010, down to 3.2% in the 3 years after 2010 [32••]. Nationally, early revision rates decreased from 16.2% in 2008–2009, down to 7.5% in 2010–2012 with the availability of a small urethral cuff, allowing more precise cuff-sizing in men with urethral circumference less than 4.0 cm [32••].

Insufficient Reservoir Pressure

Occasionally, the PRB may provide insufficient pressure to facilitate adequate urethral coaptation. Incomplete coaptation may be visualized cystoscopically. Alternatively, urethral pressure profilometry or perfusion sphincterometry may be useful in diagnosing a loose-fitting cuff. Urethral pressure profile study should demonstrate a closing urethral pressure differential of 40 to 50 cmH₂O with the cuff open and then closed [33]. Perfusion sphincterometry using a flexible

cystoscope [34] or foley catheter in the distal urethra [35] should demonstrate a retrograde leak point pressure greater than 60 cm water with the AUS device activated. When the cuff is appropriately sized, but insufficient urethral coaptation is diagnosed, then consideration should be given to increasing the pressure in the balloon reservoir. Selection of the 61–70 cm water PRB is generally efficacious in a non-radiated patient. Of course, underfilling of the reservoir (less than 22 cc fluid) can contribute to sub-optimal reservoir pressure, and adding 1 to 2 cc of fluid will often remedy that situation. Alternatively, a high pressure reservoir (71–80 cm water) may be considered.

System Leak

Fluid loss from the system can present with persistent incontinence. Sites of fluid loss may include the urethral cuff, any area of tubing, the tubing connections, the PRB, or rarely the control pump. Introduction of a fluoro-silicone layer between the two cuff leaflets and kink-resistant tubing has reduced the majority of fluid leaks [33, 36], but surgical error with faulty tubing connections or accidental needle puncture of the device or tubing can still occur.

Plain abdominal radiography can exclude loss of fluid from the PRB if contrast solution was used as a filling medium [37]. However, as several specific contrast media have been tested for use, each requires dilution with sterile water that is specific to each agent—thereby introducing the possibility of human error [38]. The manufacturer therefore recommends that the AUS system be filled with only sterile saline [39]. As abdominal radiography may not be useful in assessing the fluid status of system filled with plain saline, abdominal ultrasound or non-contrast CT of the abdomen and pelvis can assist to assess the volume in the PRB and diagnose fluid loss. Precise localization of the site of leakage is discussed later in the “[Device Malfunction—Fluid Leak](#)” section.

Table 1 Causes of AUS failure stratified by timing (early vs. late)

Early AUS failure—persistent incontinence after device activation

- Cuff size is too large
- Insufficient reservoir pressure
- System leak
- Detrusor overactivity
- Overflow incontinence/urinary retention
- Inadvertent device deactivation
- Early cuff erosion

Late AUS failure—recurrent incontinence

- Device malfunction—fluid leak
- Urethral atrophy
- Urethral erosion
- Detrusor overactivity/decreased bladder compliance

Detrusor Overactivity

Persistent or de novo detrusor overactivity can present as persistent urinary incontinence. A history of urge urinary incontinence that predated AUS implantation may assist in diagnosing detrusor overactivity. However, in the patient with severe PPI, the bladder may have been chronically under filled, preventing the patient and physician from being able to diagnose detrusor overactivity at the higher storage volumes that are typically realized after SUI surgery.

Many cases can be managed conservatively with first-line behavior modification and second-line pharmacotherapy. Management should be similar to that of any patient with overactive bladder, including ruling out urinary tract infection and giving a trial of fluid restriction, caffeine restriction, pelvic floor exercises, and antimuscarinic or beta-3 agonists. Each of

AUS artificial urinary sphincter

these treatments may be prescribed empirically, without the need for invasive urodynamic testing. However, in the case of refractory symptoms, further investigation may be warranted. It is vital to determine whether the cause of persistent leakage is due to the bladder (overactivity vs. poor compliance) or the outlet (residual ISD). When the pathophysiology remains in doubt, urodynamic evaluation is indicated to guide treatment [40]. In the case of confirmed detrusor overactivity, patients may be offered onabotulinumtoxin A chemodenervation of the detrusor or sacral neuromodulation [41, 42], with the caveat that chemodenervation requires cystoscopy and the associated transurethral instrumentation to allow for detrusor injection. In men with both impaired contractility and detrusor overactivity, chemodenervation should not be feared, as these men may still easily void to completion using valsalva to expel urine from the bladder, given the exceptionally low bladder outlet resistance following radical prostatectomy.

Overflow Incontinence/Urinary Retention

In the case of a urethral stricture or implantation of an undersized urethral cuff, urinary retention may manifest as overflow incontinence. The former may be diagnosed cystoscopically, while the latter can be diagnosed by inability to pass a urethral catheter following AUS placement, despite cuff deactivation in a patient in whom the catheter was passed with ease prior to AUS implantation. While a post-operative stricture is quite rare (as the recent implantation requires passage of a urethral catheter during surgery), this complication may be managed cystoscopically. It is vital that the AUS cuff is deactivated during endoscopic manipulation and that the stricture is ablated through the smallest possible cystoscope (17 Fr) staying as far away from the cuff as possible. An improperly sized cuff, however, cannot be dilated, nor is clean intermittent catheterization a reasonable option due to the risk of cuff erosion. While early urinary retention can occur in 8 to 31% of patients in the peri-operative period [43, 44], this is typically managed with clean intermittent catheterization with a 10 or 12 Fr catheter, passed with minimal resistance through the deactivated urethral cuff. However, prolonged retention/overflow incontinence (beyond the first 1 to 2 weeks following surgery) must be managed with upsizing of the AUS cuff, as prolonged urethral ischemia can lead to accelerated atrophy or cuff erosion. Overflow incontinence secondary to mechanical failure of the AUS cuff “locked on” is quite rare. More likely, failure of the urethral cuff to temporarily deactivate is due to insufficient compression of the scrotal pump by the patient.

Inadvertent Device Deactivation

Accidental deactivation can also present with urinary incontinence. A poorly placed control pump in the posterior aspect of the scrotum or even in the perineum can be accidentally

compressed and cause unintentional cuff deflation and urinary leakage. Typically, the patient will complain of incontinence only with certain body positions. Behavioral modification or revision of the cuff can remedy this occurrence. Sitting directly on the urethral cuff may also trigger cuff opening (via direct compression of the device). Avoidance of sitting on hard or pointed seats should remedy this situation.

Early Cuff Erosion

Finally, early cuff erosion can manifest as urinary incontinence. Early erosion is believed to result from unrecognized injury to the urethra during cuff placement, typically on the dorsal side of the urethra. Bleeding around the catheter during the surgical dissection or hematuria following catheter removal may often provide a clue that urethral injury has occurred [45]. Diagnosis may be confirmed cystoscopically, and this must be then managed by removal of the cuff (Fig. 1).

Late Failure

Device Malfunction—Fluid Leak Following a prolonged period of adequate continence, recurrent leakage (late device failure) must be evaluated in a systematic fashion to distinguish among the following causes (Table 1).

Device Malfunction— Fluid Leak

Loss of fluid due to device malfunction typically presents with sudden return of urinary continence. Fluid loss is suspected if the scrotal pump remains dimpled or if there is a sensation of air bubbles within the pump upon device cycling. Fluid loss can be definitively diagnosed using abdominal ultrasound or CT scan, noting an under-filled PRB. If the balloon reservoir was filled with radiopaque contrast at the time of initial

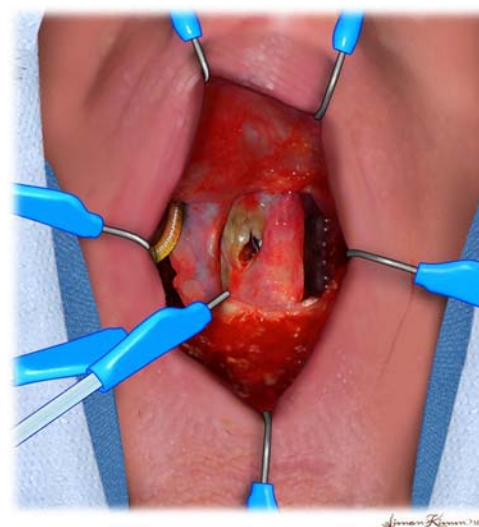


Fig. 1 Urethral erosion noted at time of cuff removal.

surgery, simple plain film radiography of the abdomen may be all that is needed. When the cuff is closed, a circumferential ring of contrast should be visible at the cuff site. When the cuff is open, the pump and PRB should contain some fluid, and the cuff should have minimal fluid. If the radiographic contrast is absent, a leak has occurred [45].

If fluid loss has occurred, then surgical exploration is necessary. A recent consensus panel report suggested that the entire AUS device be removed if fluid loss is evident [46]. However, there is a general lack of high-level evidence that complete replacement is indeed necessary if a single component is found to be the site of leakage. It has generally been recommended that a device be entirely removed and replaced if it is at least 3 years old. This threshold is based on the median time to device malfunction [47, 48]. Linder et al. recently showed that there was no statistically significant difference in 3-year device survival after replacement of a single component if a single component was identified as the source of leakage vs. replacement of the entire device [49••].

In a device that is less than 3 years old, when loss of fluid is suspected, high success rates have been realized with replacement of only the defective component [50]. Site of fluid loss can be determined with the intra-operative use of an ohmmeter. After sterilizing the ohmmeter leads, the tubing to each part of the sphincter can be interrogated by placing one electrode on a needle that is passed into tubing and grounding the other electrode to the patient. Any deflection of the needle signifies a leak. In one series of 20 revision surgeries, the ohmmeter correctly identified the site of fluid loss in 18 (90%) [50]. In this cohort, the most common sites of fluid loss were the PRB (70%) and urethral cuff (20%).

Urethral Atrophy

Sub-cuff urethral atrophy results in progressive recurrence of SUI after AUS implantation. Atrophy is diagnosed only in the absence of erosion, leak, or mechanical malfunction. When the patient presents with gradual recurrence of SUI, the urologist must rule out urethral erosion (via cystoscopy) and fluid leak (via radiography), making the diagnosis of atrophy one of exclusion [46]. Often, there is a history of needing to compress the scrotal pump with more squeezes than was required initially [51]. Sub-cuff atrophy can be treated in a variety of ways. The authors recommend that the most conservative and least risky method be tried first (cuff downsizing, PRB replacement with a higher pressure reservoir), and more complex reconstructive techniques (new cuff site, tandem cuff placement, transcervical cuff placement, or urethral wrap) should only be used when necessary. The literature is inconsistent regarding which method of cuff revision is most efficacious. For example, a recent retrospective study reported that double-cuff placement was more efficacious than either cuff downsizing (with respect to mechanical failure) or

replacement at a new site (with respect to continence) [52•]. On the other hand, O'Connor et al. demonstrated a general lack of efficacy of double-cuff AUS placement, and this technique has generally fallen out of favor as a primary salvage technique [26].

Urethral Erosion

Unlike early urethral erosion, late erosion does not typically present with incontinence. The capsule around the cuff is well established, so extravasation through the urethra with voiding is unlikely. Rather, the presentation is typically characterized by hematuria or by irritative voiding symptoms including dysuria. Risk factors for delayed cuff erosion include initial placement of an undersized cuff or inappropriate endourologic surgery or urethral catheterization without sufficient device deactivation [53, 54]. In addition, erosion of a bulbar urethral cuff is more common than erosion of a bladder neck cuff [55, 56]. And while clean intermittent catheterization may be required in patients with neurogenic bladder, it is associated with a higher rate of erosion compared to those patients who do not perform self-catheterization [57, 58]. The diagnosis of cuff erosion is readily made cystoscopically. Surgical removal of the cuff is necessary (Fig. 1). However, there are instances where the cuff alone may be removed, instead of the entire device. It is generally agreed that in the setting of frank purulence, the entire AUS must be explanted, as infection is likely to track along the entire device, following the tubing capsule to the scrotal pump and balloon reservoir. In the case of an erosion without evidence of infection, consideration can be given to removing the cuff only, capping the tubing, and replacing the cuff only after adequate urethral healing [59].

If the area of erosion is small, then simple suturing of the urethral defect should suffice, with short-term (2 to 4 weeks) urethral catheterization to promote healing. In the setting of circumferential urethral loss, urethroplasty is indicated [60, 61] with early repair advocated as a method to decrease stricture formation [62•]. Secondary re-implantation of a new device should be deferred for 3 to 6 months. It is necessary to confirm (cystoscopically) adequate healing and absence of a clinically significant urethral stricture prior to re-implantation. However, it must be noted that previous erosion is associated with an increased risk of future erosion compared to virgin implantation [31, 63, 64•].

Detrusor Overactivity/Decreased Bladder Compliance

Delayed onset detrusor overactivity is rarely related to the AUS surgery itself, but nevertheless can cause urinary incontinence. In the absence of radiation therapy or neurogenic voiding dysfunction, decreased bladder compliance is unlikely, but when present, it can adversely affect both continence and renal function. Both conditions are readily identifiable on

Table 2 Success of treatment options for the failed sphincter stratified by mode of failure

Author	Cohort (N)	Follow-up (median)	Objective success (%)	Subjective success (%)	Device survival/revision
Device failure					
Pressure regulating balloon revision					
Singla (2015)	140 vs. 154 (Retzius vs. submuscular)	23 months (mean)	81 vs. 88% (0–1 pad)	NR	No difference in revisions (13 vs. 8%)
Chung (2014)	65 high submuscular	6 months (mean)	NR	97% satisfied	4.6% cuff erosion
Component replacement					
Linder (2016)	125	4.2 years	NR	NR	76 vs. 60% survival (at 3 years, entire vs. single component revision)
Viers (2016)	229 vs. 49 (primary vs. secondary AUS)	8.3 years	56 vs. 55%	NR	NR
Eswara (2015)	90 revision cases	34 months	NR	NR	Time to revision (months): 26 downsize, 38 reposition, 29 tandem
Linder (2014)	69 prior explant (out of 138)	34 months	NR	NR	Reimplant at 9 months if prior revision, 68% survival (at 5 years)
McGeady (2014)	67 (out of 86)	39 months	NR	NR	34% failure in compromised urethra (hazard ratio: 4.8 radiation, 8.6 urethroplasty, 8.6 3.5 cm cuff)
Wang (2012)	149 primary failures	52 months	NR	NR	34% survival (at 5 years), 22-month median time to explant
Tissue failure—atrophy					
Cuff downsize					
Kretschmer (2016)	10 (out of 84)	40 months (mean)	NR	60% continent	80% survival (20% revision rate)
Rivera (2016)	181 radiation (out of 489)	4.3 years	NR	NR	77 vs. 74% survival (at 5 years), no difference in survival if avoid 3.5 cm cuff in radiated patients
Brant (2014)	386	2.3 years (mean)	NR	NR	27 vs. 12% explanted for 3.5 cm cuff (high vs. low risk patients)
Simhan (2014)	88 received 4 cm cuff (out of 170)	34 months (mean)	NR	NR	22 vs. 5% revision (before vs. after 3.5 cm cuff introduction 2010)
Hudak (2011)	45 (out of 67)	12 months (mean)	NR	NR	9% explanted
Transcorporal cuff					
Le Long (2016)	37	32 months	70% (0–1 pad)	88% satisfied	51% survival (at 5 years)
Hoy (2015)	13 (out of 30, fragile urethra)	42 months	NR	85% satisfied	7% explanted
Mock (2015)	37	8.5 months	NR	43% continent	17.3 months survival (of 18.9% explanted)
Urethral wrap					
Trost (2012)	8 patients (19 procedures)	12 months	38% (0 pad)	38% dry	38% revision rate (80% of failures after radiation)
Rehder (2007)	6	23 to 26 months	100% (0–1 pad)	100% continent	No revisions
Tandem (double) cuff					
Kretschmer (2016)	12 (out of 84)	40 months (mean)	NR	NR	25% survival (75% revision rate and 58% explant rate)
Pressure regulating balloon replacement (also see above: Pressure regulating balloon revision)					
Bugeja (2016)	50 (14 of 19 same cuff/PRB)	25 months (mean)	NR	86% (12/14) continent	NR
Tissue failure—infection/erosion					
Delayed complete replacement (see above: Component replacement)					
Non-surgical management					
Singla and Singla (2015)	2 non-surgical (out of 79)	5 and 15 years	NR	100% (2/2) continent	Both erosions into bladder neck, never explanted, 1 required stone removal
Immediate urethroplasty					
Rozanski (2014)	13 erosions (out of 26)	24 months (mean)	NR	NR	38% stricture (vs. 85% foley)

Most recent literature reported since 2010 (where available). Reference list: [65•] Singla (2015), [66] Chung (2014), [49••] Linder (2016), [64•] Viers (2016), [52•] Eswara (2015), [67•] Linder (2014), [68•] McGeady (2014), [54] Wang (2012), [69•] Rivera (2016), [70•] Kretschmer (2016), [71•] Brant (2014), [32••] Simhan (2014), [72] Hudak (2011), [73] Le Long (2016), [30] Hoy (2015), [74] Mock (2015), [60] Trost (2012), [61] Rehder (2007), [70•] Kretschmer (2016), [75] Bugeja (2016), [76] Singla and Singla (2015), [62•] Rozanski (2014), [18] Lai (2011)

AUS artificial urinary sphincter, NR not reported, PRB pressure regulating balloon, QOL quality of life

urodynamic testing and can be treated in stepwise fashion, with behavioral modification and pharmacotherapy as indicated. Refractory cases can be addressed with chemodenervation or neuromodulation [41, 42]. Augmentation cystoplasty or urinary diversion is rarely necessary even in cases of diminished compliance, as frequent voiding (to minimize bladder volume) or simple deactivation of the AUS will prevent high-pressure storage. Obviously, device deactivation will result in recurrence of stress incontinence but may be indicated if the risk of upper tract deterioration is otherwise unavoidable.

Inadvertent device deactivation can be managed with behavioral modification or surgical revision of the pump as described above in the “[Inadvertent Device Deactivation](#)” section.

Summary of Treatment Options

The current urologic literature suggests that treatment success for the failed sphincter is dependent on the timing (early vs. late) and mode of failure (device vs. tissue). Absence of continence in the immediate post-operative period as a result of simple mechanical device failure from surgical technical error (i.e., fluid leak, punctured tubing, under-filled system) should be recognized early, treated with immediate AUS revision, and have no long-term consequence on success. If a tissue failure as a result of erosion or infection is the cause for the failed sphincter, either partial or complete excision of the AUS components is advocated, depending on the duration of device implantation (less or greater than 3 years, respectively). In the case of tissue failure as a result of urethral atrophy, treatment options include cuff downsizing, cuff repositioning, urethral wrap, transcorporal cuff placement, and tandem cuff; with tandem cuff showing no improvement in leak point compared to a properly sized single cuff. A summary of the current literature regarding success of each treatment option is provided (Table 2).

Conclusions

The evaluation of recurrent or persistent incontinence in the setting of prior AUS placement in the male with post-prostatectomy incontinence should take into account the timing of the incontinence (early vs. late). In the case of early AUS failure, the pressure regulating balloon should be evaluated, and after excluding leak, erosion, or mechanical device failure, further investigation should be directed at evaluating the bladder (detrusor overactivity) or outlet (cuff size too large or small). In the case of late AUS failure, evaluation should begin with an evaluation of device function to rule out leak and a higher index of suspicion to evaluate for erosion in the setting of infection. In the absence of obvious mechanical failure, urethral atrophy is considered a diagnosis of exclusion. Management should take into account the patient’s treatment goals and expectations for a satisfactory outcome.

Replacement of the entire device, with a properly sized urethral cuff and appropriate PRB, is generally successful. In the case of extreme urethral atrophy, additional maneuvers including tandem cuff, transcorporal cuff placement, or urethral wrap may be necessary.

Compliance with Ethical Standards

Conflict of Interest Amy D. Dobberfuhl is a Principle Investigator for SUFU Foundation Study of Chemodenervation funded by the Allergan Foundation.

Craig V. Comiter is a consultant and clinical investigator for Coloplast.

Human and Animal Rights and Informed Consent This article does not contain any studies with human or animal subjects performed by any of the authors.

References

Papers of particular interest, published recently, have been highlighted as:

- Of importance
- Of major importance

1. Kim PH, Pinheiro LC, Atonia CL, Eastham JA, Sandhu JS, Elkin EB. Trends in the use of incontinence procedures after radical prostatectomy: a population based analysis. *J Urol*. 2013;189(2):602–8.
2. Martins FE, Boyd SD. Artificial urinary sphincter in patients following major pelvic surgery and/or radiotherapy: are they less favorable candidates? *J Urol*. 1995;153(4):1188–93.
3. Litwiller SE, Kim KB, Fone PD, White RW, Stone AR. Post-prostatectomy incontinence and the artificial urinary sphincter: a long-term study of patient satisfaction and criteria for success. *J Urol*. 1996;156(6):1975–80.
4. Kuznetsov DD, Kim HL, Patel RV, Steinberg GD, Bales GT. Comparison of artificial urinary sphincter and collagen for the treatment of postprostatectomy incontinence. *Urology*. 2000;56(4):600–3.
5. Elliott DS, Barrett DM. Mayo Clinic long-term analysis of the functional durability of the AMS 800 artificial urinary sphincter: a review of 323 cases. *J Urol*. 1998;159(4):1206–8.
6. Clemens JQ, Schuster TG, Konnak JW, McGuire EJ, Faerber GJ. Revision rate after artificial urinary sphincter implantation for incontinence after radical prostatectomy: actuarial analysis. *J Urol*. 2001;166(4):1372–5.
7. Gousse AE, Madjar S, Lambert MM, Fishman IJ. Artificial urinary sphincter for post-radical prostatectomy urinary incontinence: long-term subjective results. *J Urol*. 2001;166(5):1755–8.
8. Fleshner N, Herschorn S. The artificial urinary sphincter for post-radical prostatectomy incontinence: impact on urinary symptoms and quality of life. *J Urol*. 1996;155(4):1260–4.
9. Haab F, Trockman BA, Zimmern PE, Leach GE. Quality of life and continence assessment of the artificial urinary sphincter in men with minimum 3.5 years of followup. *J Urol*. 1997;158(2):435–9.
10. Pérez LM, Webster GD. Successful outcome of artificial urinary sphincters in men with post-prostatectomy urinary incontinence despite adverse implantation features. *J Urol*. 1992;148(4):1166–70.
11. Gomha MA, Boone TB. Artificial urinary sphincter for post-prostatectomy incontinence in men who had prior radiotherapy: a risk and outcome analysis. *J Urol*. 2002;167(2 Pt 1):591–6.

12. Montague DK. The artificial urinary sphincter (AS 800): experience in 166 consecutive patients. *J Urol.* 1992;147(2):380–2.
13. Mottet N, Boyer C, Chartier-Kastler E, Ben Naoum K, Richard F, Costa P. Artificial urinary sphincter AMS 800 for urinary incontinence after radical prostatectomy: the French experience. *Urol Int.* 1998;60 Suppl 2:25–9. discussion 35.
14. Klijn AJ, Hop WC, Mickisch G, Schröder FH, Bosch JL. The artificial urinary sphincter in men incontinent after radical prostatectomy: 5 year actuarial adequate function rates. *Br J Urol.* 1998;82(4):530–3.
15. Goldwasser B, Furlow WL, Barrett DM. The model AS 800 artificial urinary sphincter: Mayo Clinic experience. *J Urol.* 1987;137(4):668–71.
16. Kim SP, Sarmast Z, Daignault S, Faerber GJ, McGuire EJ, Latini JM. Long-term durability and functional outcomes among patients with artificial urinary sphincters: a 10-year retrospective review from the University of Michigan. *J Urol.* 2008;179(5):1912–6.
17. Lai HH, Hsu EI, Teh BS, Butler EB, Boone TB. 13 years of experience with artificial urinary sphincter implantation at Baylor College of Medicine. *J Urol.* 2007;177(3):1021–5.
18. Lai HH, Boone TB. Implantation of artificial urinary sphincter in patients with post-prostatectomy incontinence, and preoperative overactive bladder and mixed symptoms. *J Urol.* 2011;185(6):2254–9.
19. Comiter C. Surgery for postprostatectomy incontinence: which procedure for which patient? *Nat Rev Urol.* 2015;12(2):91–9.
20. Fulford SC, Sutton C, Bales G, Hickling M, Stephenson TP. The fate of the “modern” artificial urinary sphincter with a follow-up of more than 10 years. *Br J Urol.* 1997;79(5):713–6.
21. Brito CG, Mulcahy JJ, Mitchell ME, Adams MC. Use of a double cuff AMS800 urinary sphincter for severe stress incontinence. *J Urol.* 1993;149(2):283–5.
22. DiMarco DS, Elliott DS. Tandem cuff artificial urinary sphincter as a salvage procedure following failed primary sphincter placement for the treatment of post-prostatectomy incontinence. *J Urol.* 2003;170(4 Pt 1):1252–4.
23. Guralnick ML, Miller E, Toh KL, Webster GD. Transcorporal artificial urinary sphincter cuff placement in cases requiring revision for erosion and urethral atrophy. *J Urol.* 2002;167(5):2075–8. discussion 2079.
24. Kowalczyk JJ, Spicer DL, Mulcahy JJ. Erosion rate of the double cuff AMS800 artificial urinary sphincter: long-term followup. *J Urol.* 1996;156(4):1300–1.
25. O’Connor RC, Gerber GS, Avila D, Chen AA, Bales GT. Comparison of outcomes after single or DOUBLE-CUFF artificial urinary sphincter insertion. *Urology.* 2003;62(4):723–6.
26. O’Connor RC, Lyon MB, Guralnick ML, Bales GT. Long-term follow-up of single versus double cuff artificial urinary sphincter insertion for the treatment of severe postprostatectomy stress urinary incontinence. *Urology.* 2008;71(1):90–3.
27. Barnard J, van Rij S, Westenberg AM. A Valsalva leak-point pressure of >100 cmH₂O is associated with greater success in AdVance™ sling placement for the treatment of post-prostatectomy urinary incontinence. *BJU Int.* 2014;114 Suppl 1:34–7.
28. Manunta A, Guillé F, Patard JJ, Lobel B. Artificial sphincter insertion after radiotherapy: is it worthwhile? *BJU Int.* 2000;85(4):490–2.
29. Hird AE, Radomski SB. Artificial urinary sphincter erosion after radical prostatectomy in patients treated with and without radiation. *Can Urol Assoc J.* 2015;9(5–6):E354–8.
30. Hoy NY, Rourke KF. Artificial urinary sphincter outcomes in the “fragile urethra.”. *Urology.* 2015;86(3):618–24.
31. Raj GV, Peterson AC, Toh KL, Webster GD. Outcomes following revisions and secondary implantation of the artificial urinary sphincter. *J Urol.* 2005;173(4):1242–5.
32. Simhan J, Morey AF, Zhao LC, Tausch TJ, Scott JF, Hudak SJ, et al. Decreasing need for artificial urinary sphincter revision surgery by precise cuff sizing in men with spongiosal atrophy. *J Urol.* 2014;192(3):798–803. **In a sample of 236 men who underwent AUS at one institution, 4.0 cm cuff revisions improved from 22.2% down to 4.7% after introduction of the 3.5-cm cuff, consistent with a national sample demonstrating a decrease in early revision rate from 16.2% in 2008–2009, down to 7.5% in 2010–2012, allowing for more precise cuff sizing in men with urethral circumference less than 4.0 cm.**
33. Chung E, Ranaweera M, Cartmill R. Newer and novel artificial urinary sphincters (AUS): the development of alternatives to the current AUS device. *BJU Int.* 2012;110 Suppl 4:5–11.
34. Choe JM, Battino BS, Bell TE. Retrograde perfusion sphincterometry with a flexible cystoscope: method of troubleshooting the AMS 800. *Urology.* 2000;56(2):317–9.
35. Leach GE, Raz S. Perfusion sphincterometry. Method of intraoperative evaluation of artificial urinary sphincter function. *Urology.* 1983;21(3):312–4.
36. Hajivassiliou CA. The development and evolution of artificial urethral sphincters. *J Med Eng Technol.* 1998;22(4):154–9.
37. Rose SC, Hansen ME, Webster GD, Zakrzewski C, Cohan RH, Dunnick NR. Artificial urinary sphincters: plain radiography of malfunction and complications. *Radiology.* 1988;168(2):403–8.
38. Brucker BM, Demirtas A, Fong E, Kelly C, Nitti VW. Artificial urinary sphincter revision: the role of ultrasound. *Urology.* 2013;82(6):1424–8.
39. AMS 800 Urinary Control System for Male Patients. Operating room manual. Minnetonka: American Medical Systems, Inc; 2014. p. 40.
40. Winters JC, Dmochowski RR, Goldman HB, Herndon CDA, Kobashi KC, Kraus SR, et al. Urodynamic studies in adults: AUA/SUFU guideline. *J Urol.* 2012;188(6 Suppl):2464–72.
41. Gormley EA, Lightner DJ, Burgio KL, Chai TC, Clemens JQ, Culkun DJ, et al. Diagnosis and treatment of overactive bladder (non-neurogenic) in adults: AUA/SUFU guideline. *J Urol.* 2012;188(6 Suppl):2455–63.
42. Gormley EA, Lightner DJ, Faraday M, Vasavada SP. American Urological Association, Society of Urodynamics, Female Pelvic Medicine. Diagnosis and treatment of overactive bladder (non-neurogenic) in adults: AUA/SUFU guideline amendment. *J Urol.* 2015;193(5):1572–80.
43. Smith PJ, Hudak SJ, Scott JF, Zhao LC, Morey AF. Transcorporal artificial urinary sphincter cuff placement is associated with a higher risk of postoperative urinary retention. *Can J Urol.* 2013;20(3):6773–7.
44. Linder BJ, Piotrowski JT, Ziegelmann MJ, Rivera ME, Rangel LJ, Elliott DS. Perioperative complications following artificial urinary sphincter placement. *J Urol.* 2015;194(3):716–20.
45. Chung E, Cartmill R. Diagnostic challenges in the evaluation of persistent or recurrent urinary incontinence after artificial urinary sphincter (AUS) implantation in patients after prostatectomy. *BJU Int.* 2013;112 Suppl 2:32–5.
46. Biardeau X, Aharony S, AUS Consensus Group, Campeau L, Corcos J. Artificial urinary sphincter: report of the 2015 Consensus Conference. *Neurourol Urodyn.* 2016;35 Suppl 2:S8–24.
47. Peterson AC, Webster GD. Artificial urinary sphincter: lessons learned. *Urol Clin North Am.* 2011;38(1):83–8. vii.
48. Maillet F, Buzelin J-M, Bouchot O, Karam G. Management of artificial urinary sphincter dysfunction. *Eur Urol.* 2004;46(2):241–5. discussion 246.
49. Linder BJ, Viers BR, Ziegelmann MJ, Rivera ME, Rangel LJ, Elliott DS. Artificial urinary sphincter mechanical failures—is it better to replace the entire device or just the malfunctioning component? *J Urol.* 2016;195(5):1523–8. **Out of 1082 primary AUS placements, 125 demonstrated mechanical failure at a median follow-up of 4.2 years. The authors found no statistically significant difference in 3-year device survival after replacement of a single component if a single component was identified as the source of leakage vs. replacement of the entire device.**

50. Selph JP, Belsante MJ, Gupta S, Ajay D, Lentz A, Webster G, et al. The ohmmeter identifies the site of fluid leakage during artificial urinary sphincter revision surgery. *J Urol*. 2015;194(4):1043–8.
51. Webster GD, Sherman ND. Management of male incontinence following artificial urinary sphincter failure. *Curr Opin Urol*. 2005;15(6):386–90.
52. Eswara JR, Chan R, Vetter JM, Lai HH, Boone TB, Brandes SB. Revision techniques after artificial urinary sphincter failure in men: results from a multicenter study. *Urology*. 2015;86(1):176–80.
53. Bryan DE, Mulcahy JJ, Simmons GR. Salvage procedure for infected noneroded artificial urinary sphincters. *J Urol*. 2002;168(6):2464–6.
54. Wang R, McGuire EJ, He C, Faerber GJ, Latini JM. Long-term outcomes after primary failures of artificial urinary sphincter implantation. *Urology*. 2012;79(4):922–8.
55. Spiess PE, Capolicchio JP, Kiruluta G, Salle JP, Berardinucci G, Corcos J. Is an artificial sphincter the best choice for incontinent boys with Spina Bifida? Review of our long term experience with the AS-800 artificial sphincter. *Can J Urol*. 2002;9(2):1486–91.
56. Castera R, Podestá ML, Ruarte A, Herrera M, Medel R. 10-Year experience with artificial urinary sphincter in children and adolescents. *J Urol*. 2001;165(6 Pt 2):2373–6.
57. Simeoni J, Guys JM, Mollard P, Buzelin JM, Moscovici J, Bondonny JM, et al. Artificial urinary sphincter implantation for neurogenic bladder: a multi-institutional study in 107 children. *Br J Urol*. 1996;78(2):287–93.
58. Holmes NM, Kogan BA, Baskin LS. Placement of artificial urinary sphincter in children and simultaneous gastrocystoplasty. *J Urol*. 2001;165(6 Pt 2):2366–8.
59. Motley RC, Barrett DM. Artificial urinary sphincter cuff erosion. Experience with reimplantation in 38 patients. *Urology*. 1990;35(3):215–8.
60. Trost L, Elliott D. Small intestinal submucosa urethral wrap at the time of artificial urinary sphincter placement as a salvage treatment option for patients with persistent/recurrent incontinence following multiple prior sphincter failures and erosions. *Urology*. 2012;79(4):933–8.
61. Rehder P, Pinggera G-M, Mitterberger M, Pelzer AE, Gozzi C, Herwig R. Urethral support with PelviSoft after artificial urinary sphincter erosion at revision procedures. *Wien Med Wochenschr*. 2007;157(7–8):170–2.
62. Rozanski AT, Tausch TJ, Ramirez D, Simhan J, Scott JF, Morey AF. Immediate urethral repair during explantation prevents stricture formation after artificial urinary sphincter cuff erosion. *J Urol*. 2014;192(2):442–6.
63. Lai HH, Boone TB. Complex artificial urinary sphincter revision and reimplantation cases—how do they fare compared to virgin cases? *J Urol*. 2012;187(3):951–5.
64. Viers BR, Linder BJ, Rivera ME, Rangel LJ, Ziegelmann MJ, Elliott DS. Long-term quality of life and functional outcomes among primary and secondary artificial urinary sphincter implantations in men with stress urinary incontinence. *J Urol*. 2016;196(3):838–43.
65. Singla N, Siegel JA, Simhan J, Tausch TJ, Klein A, Thoreson GR, et al. Does pressure regulating balloon location make a difference in functional outcomes of artificial urinary sphincter? *J Urol*. 2015;194(1):202–6.
66. Chung PH, Morey AF, Tausch TJ, Simhan J, Scott JF. High submuscular placement of urologic prosthetic balloons and reservoirs: 2-year experience and patient-reported outcomes. *Urology*. 2014;84(6):1535–40.
67. Linder BJ, de Cogain M, Elliott DS. Long-term device outcomes of artificial urinary sphincter reimplantation following prior explantation for erosion or infection. *J Urol*. 2014;191(3):734–8.
68. McGeedy JB, McAninch JW, Truesdale MD, Blaschko SD, Kenfield S, Breyer BN. Artificial urinary sphincter placement in compromised urethras and survival: a comparison of virgin, radiated and reoperative cases. *J Urol*. 2014;192(6):1756–61.
69. Rivera ME, Linder BJ, Ziegelmann MJ, Viers BR, Rangel LJ, Elliott DS. The impact of prior radiation therapy on artificial urinary sphincter device survival. *J Urol*. 2016;195(4P1):1033–7.
70. Kretschmer A, Buchner A, Grabbert M, Stief CG, Pavlicek M, Bauer RM. Risk factors for artificial urinary sphincter failure. *World J Urol*. 2016;34(4):595–602.
71. Brant WO, Erickson BA, Elliott SP, Powell C, Alsikafi N, McClung C, et al. Risk factors for erosion of artificial urinary sphincters: a multicenter prospective study. *Urology*. 2014;84(4):934–8.
72. Hudak SJ, Morey AF. Impact of 3.5 cm artificial urinary sphincter cuff on primary and revision surgery for male stress urinary incontinence. *J Urol*. 2011;186(5):1962–6.
73. Le Long E, Rebibo JD, Nouhaud FX, Grise P. Transcorporal artificial urinary sphincter in radiated and non-radiated compromised urethra. Assessment with a minimum 2 year follow-up. *Int Braz J Urol*. 2016;42(3):494–500.
74. Mock S, Dmochowski RR, Brown ET, Reynolds WS, Kaufman MR, Milam DF. The impact of urethral risk factors on transcorporeal artificial urinary sphincter erosion rates and device survival. *J Urol*. 2015;194(6):1692–6.
75. Bugeja S, Ivaz SL, Frost A, Andrich DE, Mundy AR. Urethral atrophy after implantation of an artificial urinary sphincter: fact or fiction? *BJU Int*. 2016;117(4):669–76.
76. Singla N, Singla AK. Review of single-surgeon 10-year experience with artificial urinary sphincter with report of sterile cuff erosion managed nonsurgically. *Urology*. 2015;85(1):252–6.