

Structural MRI correlates of recognition memory in Alzheimer's disease

DEBORAH A. CAHN,^{1,2} EDITH V. SULLIVAN,¹ PAULA K. SHEAR,¹ LAURA MARSH,¹
ROSEMARY FAMA,^{1,2} KELVIN O. LIM,^{1,2} JEROME A. YESAVAGE,^{1,2}
JARED R. TINKLENBERG,^{1,2} AND ADOLF PFEFFERBAUM^{1,3}

¹Department of Psychiatry and Behavioral Sciences, Stanford University School of Medicine, Stanford, CA

²Psychiatry Service, VA Palo Alto Health Care System, Palo Alto, CA

³Neuropsychiatry Program, SRI International, Menlo Park, CA

(RECEIVED December 23, 1996; REVISED April 29, 1997; ACCEPTED May 22, 1997)

Abstract

Neuroimaging and lesion studies have demonstrated that hippocampal volume correlates with memory performance, but material-specific lateralization of this structure-function relationship has been inconsistent. This MRI study examined the relative contributions of left and right temporal lobe volumes to verbal and nonverbal recognition memory in a group of 20 Alzheimer's disease (AD) patients. There was a significant relationship between extent of right hippocampal and right temporal gray matter tissue volume deficit and performance on the face recognition subtest of the Warrington Recognition Memory Test. The face recognition test correlated with right hemisphere volume but not to left, indicating a material-specific relationship between brain structure and function in this patient group. Right temporal horn volume did not account for a significant proportion of variance in face recognition memory. Although word recognition was not significantly correlated with either left or right hippocampal volume in the total group, there was a strong correlation between left hippocampal volume and word recognition memory in the female AD patients. Thus, face recognition shows a material specific relationship with select lateralized hippocampal and temporal cortical volumes in AD patients, regardless of gender, whereas the verbal recognition-left-hippocampal volume relationship may be mediated by gender. (*JINS*, 1998, 4, 106–114.)

Keywords: Memory, Alzheimer's disease, Neuroimaging

INTRODUCTION

The importance of the hippocampus and its adjacent structures to memory functioning has been clearly demonstrated in experimental lesion studies (Squire & Zola-Morgan, 1991) and in patients with focal brain damage in this region (Butters et al., 1987; Milner, 1965; Zola-Morgan et al., 1986). The type of memory subserved by these structures is explicit or declarative and is best demonstrated by performance on recognition tests based on nonstrategic retrieval processes. Relative to normal elderly individuals, patients with Alzheimer's Disease (AD) are severely impaired on tests of explicit memory (Butters et al., 1987; Cahn et al., 1995; Morris et al., 1989; Salmon et al., 1989), and their

deficits are thought to be attributable to the pathological processes that affect mesial temporal lobe structures (reviewed by Sullivan et al., in press).

Recent structural neuroimaging studies report that the degree of hippocampal volume shrinkage is significantly correlated with memory impairment in patients with AD. Deweer and colleagues (Deweer et al., 1995) analyzed the relationship between volumetric measures of the hippocampal formation, amygdala, and caudate nucleus and quantitative and qualitative indices of explicit memory and found that the volume of the hippocampal formation correlated significantly with both direct measures of memory, such as the memory quotient from the Wechsler Memory Scale (Wechsler, 1945), and indirect indices of memory performance, including extra list intrusions on the Grober and Buschke test (Grober & Buschke, 1987) and the California Verbal Learning Test (CVLT; Delis et al., 1987). The hippocampal formation also showed a strong relationship to memory sub-

Reprint requests to: Edith V. Sullivan, Department of Psychiatry & Behavioral Sciences, Stanford University School of Medicine, Stanford, CA 94305-5717, USA.

tests of dementia screening tests, such as the Mini Mental State Examination (MMSE; Folstein, 1975) and the Mattis Dementia Rating Scale (DRS; Mattis, 1976, 1988). Similar findings have been reported by Fama et al. (1997), who showed that hippocampal volume uniquely predicted performance on the memory subtest of the DRS in patients with AD and by Stout et al. (1996), who found a similar relationship in AD patients between the DRS and a measure of limbic cortical gray matter. An association between hippocampal volume and verbal memory scores in delayed recall paradigms has also been found in normal elderly adults (Golomb et al., 1993, 1994).

The relationship between lateralized brain damage and memory functioning has been studied extensively. In particular, investigations of patients who have undergone unilateral temporal lobectomies for the treatment of epilepsy have shown consistent relationships between material-specific memory deficits and lateralized temporal lobe lesions. Verbal memory is often found impaired following left temporal lobe resections, whereas right temporal lobectomies often produce deficits in nonverbal memory (Milner, 1970, 1971, 1972; Morris et al., 1995; Smith, 1989).

Selective contributions of lateralized medial temporal lobe structures to material-specific memory performance have not been clearly delineated, however. Demonstration of this specific structure–function relationship requires tests with adequate sensitivity and specificity as well as quantitative measurement of target brain structures. Numerous verbal recognition memory tests have been developed, but few nonverbal tests are available. The Warrington Recognition Memory Test (WRMT; Warrington, 1984) is an appropriate instrument for this purpose because it comprises both a word recognition test and a face recognition test. Both subtests of the WRMT have been shown to discriminate patients with diffuse atrophy from older normal subjects (Warrington, 1984). This finding was replicated by Diesfeldt (1990), who compared AD patients to controls on the WRMT and demonstrated that patients performed significantly worse than controls on both recognition memory for words (RMW) and recognition memory for faces (RMF). With regard to lateralizing effects, Warrington (1984) demonstrated that patients with right-sided lesions performed in the impaired range only on the RMF test, while patients with left-sided lesions performed poorly on both RMF and RMW. Thus, the WRMT appears to be sensitive to material specific deficits for patients with right-hemisphere lesions, but this relationship has not been consistent for patients with left-sided lesions (Lezak, 1995).

While a number of studies have demonstrated that hippocampal volume correlates with memory performance in AD patients, material-specific lateralization of this structure–function association has seldom been considered. The WRMT affords an opportunity to investigate this relationship. The purpose of the present study was to test the hypotheses that the volume of the left hippocampus, but not other left temporal regions, would uniquely predict performance on recognition memory for words, whereas the vol-

ume of the right hippocampus, but not other right temporal regions, would uniquely predict performance on recognition memory for faces.

METHODS

Research Participants

Participants included 20 AD patients (13 men and 7 women) recruited from the Geriatric Psychiatry Research Unit and National Institute of Mental Health Dementia Clinical Research Center of the Veterans Affairs Palo Alto Health Care System. All AD patients met the National Institute of Neurologic and Communicative Disease and Stroke–Alzheimer's Disease and Related Disorders Association criteria for probable AD (Khachaturian, 1985; McKhann et al., 1984). Normal control (NC) participants spanning the adult age range (20–84 years) were used as a reference group for the MRI volumetric measures. These participants or a subset of them have formed the norms for other studies from our laboratory (e.g., Lim et al., 1996; Pfefferbaum et al., 1994; Sullivan et al., 1995). Screening for all participants included a psychiatric interview and medical examination. Participants were excluded if they had any significant history of psychiatric or neurological disorder not related to their diagnosis (e.g., stroke, closed head injury), past or present alcohol abuse or dependence, or serious medical condition other than AD. Informed consent was obtained from all participants or their conservators.

Demographic information for the AD participants and an age-matched group of NC individuals ($N = 20$; 11 men, 9 women) is summarized in Table 1. The AD and NC patients did not differ significantly in terms of educational background ($p = .39$) or age ($p = .10$). The AD group had a significantly lower mean MMSE score than the NC group ($p < .0001$). The mean DRS (Mattis, 1976, 1988) score for the AD group was 110.9 ± 15.7 out of a possible 144 points.

Warrington Recognition Memory Test

The Warrington Recognition Memory Test (WRMT) comprises two subtests: forced-choice recognition memory for words (RMW) and forced-choice recognition memory for faces (RMF). A full description of the procedures is pro-

Table 1. Demographics for the 20 AD patients and 20 NC participants

Variable	AD		NC	
	<i>M</i>	(<i>SD</i>)	<i>M</i>	(<i>SD</i>)
Age	71.7	(7.1)	68.4	(5.4)
Education (years)	15.1	(3.8)	16.0	(2.5)
MMSE	19.2	(4.4)	28.8	(1.1)*

* $p < .0001$.

vided by Warrington (Warrington, 1984). Briefly, the RMW consists of 50 printed words presented at a rate of one item every 3 s. To ensure that each item is attended and processed, the patient is asked to judge whether the item is *pleasant* or *not pleasant*. This presentation phase is followed by a two-choice recognition memory test that includes 50 pairs of words presented on cards; the patient is asked to select the word on each card that was seen on the presentation list. The RMF test is similar, but photographs of men are used as the stimuli. All subjects were administered the WRMT within 2 months of the MRI study.

MRI procedures

MRI acquisition protocols, image analysis methods, and anatomical definitions for the measured brain regions are detailed elsewhere (Lim & Pfefferbaum, 1989; Lim et al., 1990; Pfefferbaum et al., 1994; Sullivan et al., 1995; Zipursky et al., 1994). In summary, a 1.5-T General Electric Signa MRI scanner (Milwaukee, WI) and a multiecho, flow compensated, cardiac gated pulse sequence (TE = 40, 80 ms; effective TR \approx 2800 ms; field of view = 24 cm, number of excitations = 1; 256×256 matrix) was used to acquire 22 contiguous 3-mm thick coronal images oriented perpendicular to the anterior commissure–posterior commissure (AC–PC) line. Based on a midline sagittal image, acquisition began 6 mm anterior to the AC and extended 66 mm posteriorly. Image analysis was performed on SUN Sparc Stations using customized software for manual point placement, semi-automated edge detection, manual fluid–tissue thresholding, and automated tissue segmentation into gray and white matter regions. Volumes were calculated by summing pixels corresponding to gray matter, white matter, or cerebrospinal fluid within each region. Measurements were performed blind to participant identity, diagnosis, and cerebral hemisphere.

The temporal lobe, hippocampus, and temporal horn were measured separately in each hemisphere (Figure 1). Inter- and intrarater reliability were calculated with intraclass correlations and for most measures were at least .90 (Sullivan et al., 1995). The temporal lobe measurement began at the temporal lobe stem. The posterior boundary for this region was one slice (3 mm) anterior to the slice showing the majority of three anatomical landmarks: (1) ascending portion of hippocampal tail, (2) absence of vertical fissures of the lateral sulcus, and (3) initial appearance of ventricular trigone, fornix in the wall of the lateral ventricle, and splenium of the corpus callosum. The temporal lobe gray matter measure equaled total temporal lobe gray matter volume minus the hippocampal volume.

Hippocampal measures began anteriorly where hippocampal tissue was clearly distinguished from amygdala. The temporal horn was measured on all sections where present. When both present, the temporal horn and hippocampal regions were delineated using a single outline, with thresholding and segmentation methods used to distinguish CSF and hippocampal tissue.

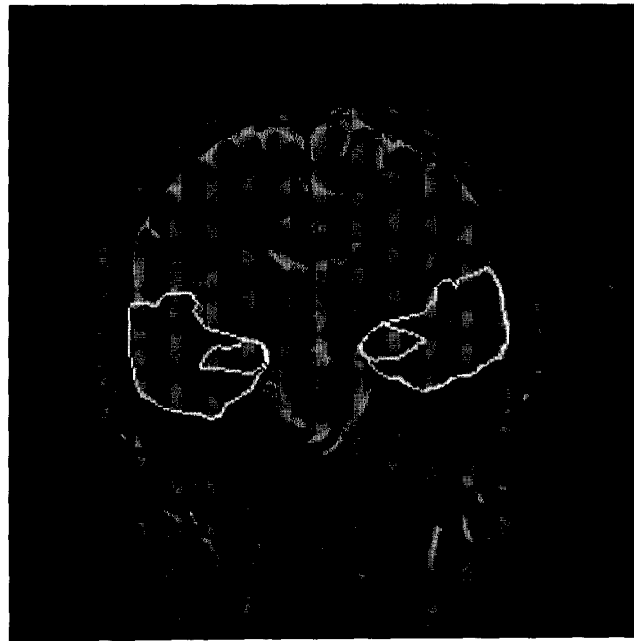

Fig. 1. Coronal image depicting the outline of regions of the two principal regions of interest: Temporal lobes and hippocampi.

Temporal horn measurements were made on all sections on which the structure was clearly present, beginning anterior to the hippocampus and lateral and inferior to the amygdala. The posterior limit corresponded to the hippocampal and temporal lobe measures.

Statistical analyses

A two-step regression analysis was used to correct the MRI volumes for normal variation attributable to intracranial volume (ICV) and age (Mathalon et al., 1993a; Pfefferbaum et al., 1994; Sullivan et al., 1995). The control group used for these corrections comprised 84 men and 28 women, ranging in age from 20 to 84 years. Group comparison in the present study employed the subgroup of control participants ($N = 20$) who spanned the age range of the 20 AD patients. This correction method allows for analysis of disease-related changes independent of the known effects of normal aging and head size (Mathalon et al., 1993a, 1993b). For AD patients, head size- and age-corrected z scores provide volume estimates relative to that which would be expected for normal control subjects of a particular head size and age. All measures were expressed as z scores, where the expected mean of the controls at any age was 0 ± 1 standard deviation. Lower z scores for tissue measures and higher z scores for CSF measures reflect greater abnormality in the direction expected for AD.

Correlational analyses were conducted using Pearson product-moment correlations. Multiple regression analyses examined the proportion of variance accounted for in the WRMT tests by each MRI volume, and subsequently, to

determine the incremental proportion of variance accounted for by one brain region over the other. In these models, the dependent variable was the WRMT raw score, and the independent variables were the left or right hippocampal volume, left or right temporal horn volume, and left or right temporal gray matter volume.

All multiple regression analyses were conducted twice: the first analyses used age- and head-size-corrected MRI volumes expressed as z scores; the second used head size residualized scores and corrected for age by entering age as a predictor into the multiple regression models.

RESULTS

Group Differences in MRI Volumes

A series of 2 (diagnosis) \times 2 (side) mixed-design ANOVAs revealed significant group effects for hippocampus [$F(1,38) = 9.6, p < .01$], temporal horn [$F(1,38) = 35.2, p < .0001$], and temporal gray matter [$F(1,38) = 34.4, p < .0001$], with the AD group showing significantly smaller hippocampal and gray matter volumes and significantly larger temporal horn volumes than the NC subjects. None of the ANOVAs revealed a significant effect of hemisphere or significant interaction. Figures 2a–c show the mean age- and head-size-corrected MRI volumes for AD patients and NC participants.

Group Differences in WRMT Scores

A 2 (diagnosis) \times 2 (Warrington task) mixed-design ANOVA revealed a significant effect of diagnosis [$F(1,37) = 163.0, p < .0001$], where the NC group performed better than the AD group (Figure 3). There was no effect of material (i.e., faces vs. words) and no significant interaction.

Bivariate Correlations Between WRMT Scores and MRI Volumes

Table 2 displays a correlation matrix for all WRMT raw scores and MRI z scores in the AD group. The relationship between RMW and left temporal horn volume only approached significance ($r = -.44, p < .06$; Figure 4a). A significant relationship was present between RMF and right hippocampal volume ($r = .51, p < .02$). As Figure 4b indicates, one participant scored substantially above the rest of the group on the RMF test. When this individual was excluded from the correlational analyses, only a slightly weaker relationship emerged between RMF score and right hippocampal volume ($r = .41, p = .08$). A significant correlation was also present between RMF and right temporal gray matter volume ($r = .49, p < .03$; Figure 4c). When the subject with a high RMF score was omitted, the relationship remained significant ($r = .47, p < .05$). No other relation-

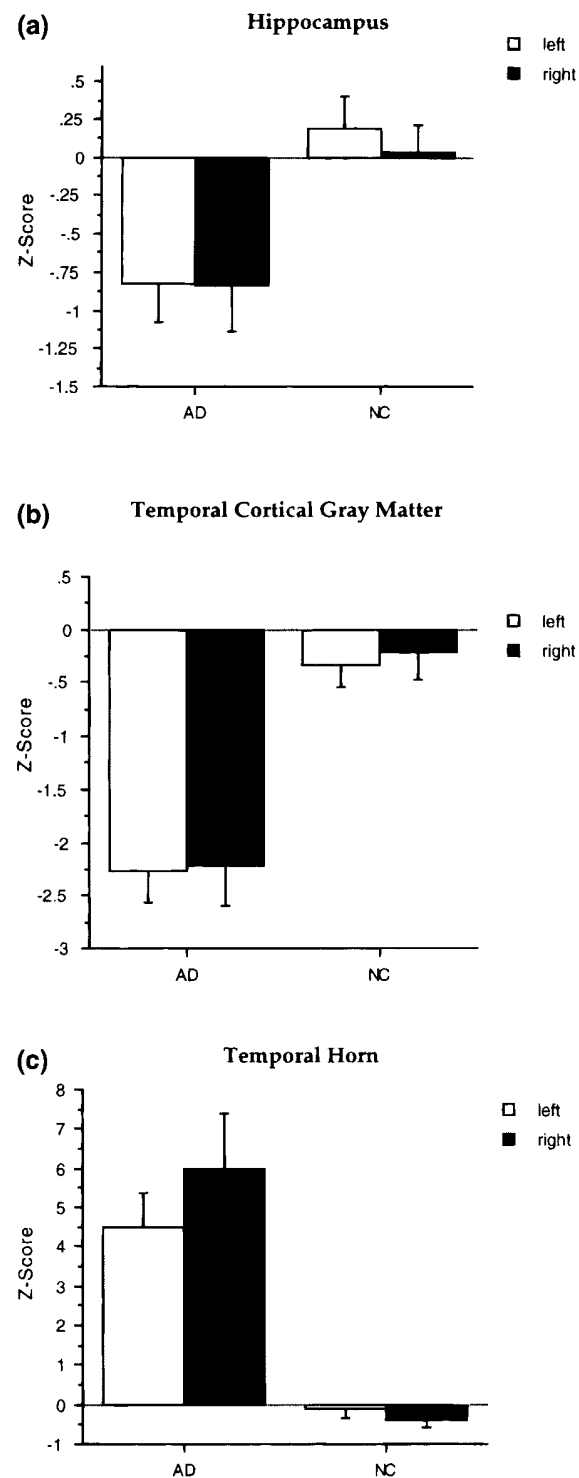


Fig. 2a–c. Mean age- and head-size-corrected temporal lobe (z scores) volumes of AD and NC groups. Low tissue scores (volumes) and high CSF scores are in the direction of abnormality. Error bars reflect SEs.

ships were statistically significant. A similar correlation matrix for NC subjects revealed no significant relationships, and hence no further statistical analyses were conducted in this group.

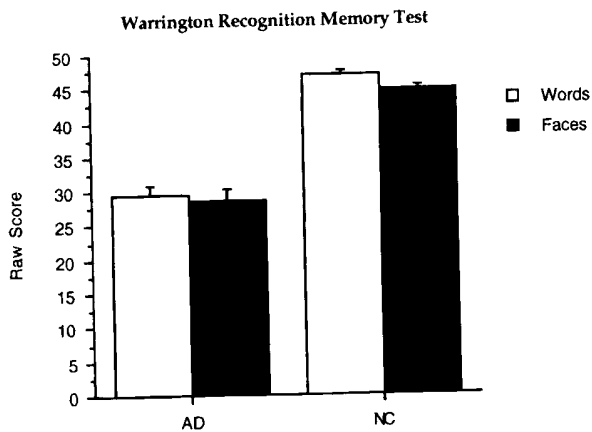


Fig. 3. Performance of AD and NC groups on the Warrington Recognition Memory Test. Maximum score = 50; chance = 25.

An additional analysis examined the effect of sex on the relationship between hippocampal volume and recognition memory for faces and words in the patients with AD because hemispheric specialization for language and verbal memory has been shown to be different in men and women (Gordon, 1983; Hiscock et al., 1995). The relationship between left hippocampal volume and RMW was significant for women ($r = .85, p < .05$) but not for men ($r = -.17, p = .59$), and the difference between these correlations was also significant ($p < .05$). There was no significant difference, however, between the men ($r = .52$) and women ($r = .58$) in the correlation between right hippocampal volume and RMF. The pattern of correlations was the same when reanalyzed with Spearman rank order tests.

Lateralized MRI Volume Predictors of WRMT Performance

The corresponding beta coefficients and R^2 change for each of these analyses are shown in Table 3.

Table 2. Correlation matrix for age- and head-size-corrected MRI volumes (expressed as z scores) and WRMT raw scores in patients with AD

MRI volume	Recognition Memory	
	(words)	(faces)
Hippocampus		
Left	.23	.23
Right	.26	.51*
Temporal gray matter		
Left	-.03	.06
Right	.38	.49*
Temporal horn		
Left	-.44	-.03
Right	-.33	-.31

* $p < .05$.

MRI Prediction of RMF

Because the bivariate correlations suggested some selective relationships between left and right temporal lobe measures and WRMT performance, we examined the unique contribution of each after removing their shared variance. A multiple regression analysis examining the contribution of left and right hippocampal volumes to RMF revealed that the incremental proportion of variance accounted for by right hippocampal volume, after accounting for the contribution of the left hippocampal volume, was significant ($p < .05$), but the incremental proportion of variance associated with left hippocampal volume over right hippocampal volume was not ($p = .34$). An analysis predicting RMF from right and left temporal gray matter volumes revealed that the incremental proportion of variance accounted for by the right temporal gray matter volume, after accounting for the contribution of left temporal gray matter volume, was significant ($p < .05$), whereas the opposite was not ($p = .38$). Neither the left nor the right temporal horn volumes were significant unique predictors of RMF scores.

To investigate the relative contributions of different temporal region volumes to performance on the RMF, a multiple regression analysis was conducted with right hippocampal volume, right temporal horn volume, and right temporal gray matter volume predicting RMF performance. The results, displayed in Table 3, reveal that both right hippocampal volume and right temporal gray matter volume were significant predictors of performance on the RMF ($ps < .05$), whereas right temporal horn volume was not.

MRI Predictors of RMW

None of the multiple regressions, which used pairs of lateralized brain structures as predictors, made significant unique contributions to RMW. To investigate the relative contributions of different temporal region volumes of the left hemisphere to performance on the RMW, a multiple regression analysis was conducted with left hippocampal volume, temporal horn volume, and temporal gray matter volume. Only left temporal horn accounted for a unique and significant proportion of variance in RMW ($p < .05$).

Multiple regression analyses based on head-size- (but not age-) corrected MRI scores and using age as a separate predictor yielded the same pattern of results as those reported above, which were based on head-size- and age-corrected z scores.

DISCUSSION

Right hippocampal and right temporal gray matter tissue volumes were significantly related to performance on the RMF subtest of the WRMT in patients with AD. The RMF test was sensitive to right hemisphere pathology but not to left, indicating a material-specific relationship between brain structure and function in this patient group. Although the

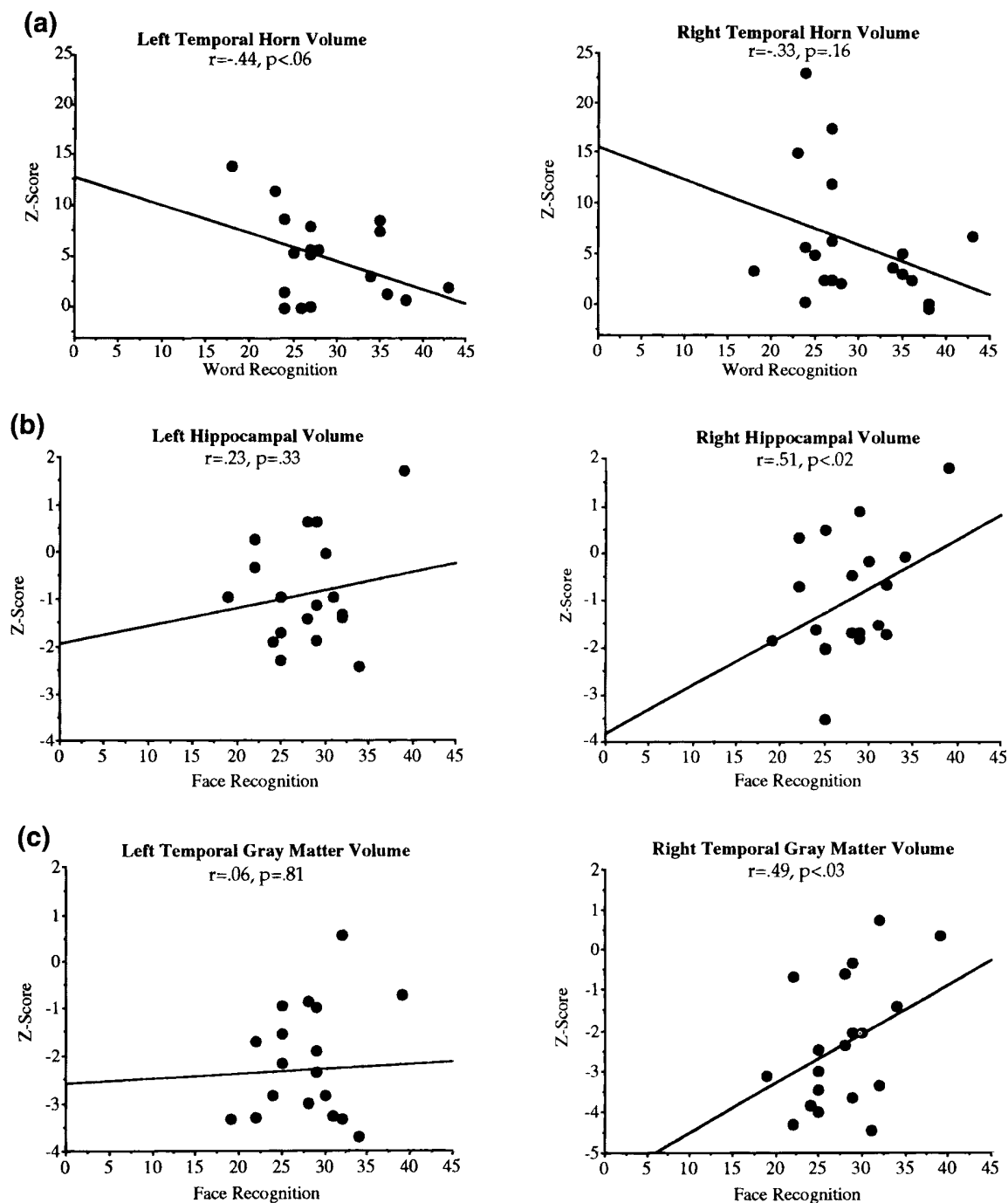


Fig. 4a–c. Scatterplots depicting the relationship between RMW and left and right temporal horn volumes (4a) and between RMF score and volumes of the left and right hippocampus (4b) and left and right temporal gray matter volumes (4c) in AD patients.

RMW did not show a similar relationship to left hippocampal or left temporal cortical gray matter volumes, there was a trend for RMW to be related to left, but not right, temporal horn enlargement. Although these discrepant findings cannot be explained by right-*versus*-left MRI volume differences in the AD group, they may be related to gender. Similarly,

performance by the AD group was virtually the same on both word and face recognition.

The data suggest that RMF is more sensitive to changes in the brain structures subserving nonverbal recognition than RMW is to structural change influencing verbal recognition. Previous studies of AD patients and other patient pop-

Table 3. Multiple regressions predicting WRMT scores from MRI regional brain volume *z* scores

Dependent measure	Predictors	Beta coefficient	R ² change
RMF			
Overall R ² = .30*	Left hippocampus	-1.80	.04
	Right hippocampus	3.50	.25*
Overall R ² = .28*	Left temporal gray matter	-1.10	.04
	Right temporal gray matter	2.40	.28*
Overall R ² = .10	Left temporal horn	0.07	.002
	Right temporal horn	-0.33	.09
	Right hippocampus	2.80	.10*
Overall R ² = .44*	Right temporal horn	0.31	.00
	Right temporal gray matter	1.90	.09*
RMW			
Overall R ² = .07	Left hippocampus	0.59	.01
	Right hippocampus	0.94	.02
Overall R ² = .18	Left temporal gray matter	-1.30	.05
	Right temporal gray matter	1.90	.18
Overall R ² = .24	Left temporal horn	-0.59	.13
	Right temporal horn	-0.24	.05
Overall R ² = .34	Left hippocampus	1.70	.15
	Left temporal horn	-0.94	.33*
	Left temporal gray matter	-2.10	.14

**p* < .05.

ulations support this possibility. Diesfeldt (1990) found that the RMF provided better sensitivity and specificity than did the RMW for discriminating AD patients from normal elderly people. Some authors have attributed this and similar findings to greater difficulty of the RMF than RMW test (Diesfeldt, 1990; Moss et al., 1986; Salmon et al., 1989). In a study of patients who underwent unilateral temporal lobectomy for the treatment of epilepsy, the RMF test was sensitive and specific in detecting right temporal lobe abnormality, whereas the RMW was less sensitive to abnormalities in the left temporal lobe (Morris et al., 1995). Taken together, these studies provide evidence that the RMF is a more sensitive measure for detecting right temporal lobe pathology than the RMW test is for detecting left temporal lobe pathology.

One explanation for the discrepancy between the material specific findings of these two tests is that word recognition memory relies on processes subserved by structures other than, or in addition to, the medial temporal lobe. Golomb et al. (1994), in a study of hippocampal volumes in normal elderly individuals, suggested that other structures such as the parahippocampal cortex may also contribute to memory processing and that hippocampal volume loss may reflect degeneration of other structures with which the hippocampus shares variance. In the present study, neither temporal horn enlargement nor temporal gray matter volume deficits added significantly to the prediction of word recognition, suggesting that structures outside the temporal region may play a role in the successful performance on this test.

The extent of hemispheric specialization for language and verbal memory may be different in men and women (Gordon, 1983; Hiscock et al., 1995). In patients with AD, cognitive asymmetry and anatomic asymmetry have been found to be more strongly associated in men than in women (Raz et al., 1987). This possibility may contribute to the lack of a selective relationship between word recognition and left hippocampal volume observed in the present study when men and women were combined. We performed an additional analysis to determine whether gender may affect the relationship between hippocampal volume and recognition memory performance. When men and women were analyzed separately, women but not men showed a predictable relationship between left hippocampal volume and RMW. The sample sizes in these *post-hoc* gender analyses were small, however, and require replication with larger samples and other patient populations.

The RMF is one of the few nonverbal recognition tests available. The finding of a specific relationship between right temporal lobe tissue volume deficit and poor face recognition by AD patients provides further validity for the test and underscores its importance in the assessment of patients with suspected right mesial and lateral temporal damage. The relationship between left temporal horn enlargement and performance on the RMW, while only approaching significance, suggests that RMW may be sensitive to extrahippocampal temporal and possibly nontemporal tissue volume loss.

ACKNOWLEDGMENTS

This research was supported by Grants MH40041 (J.A.Y.), AG11427 (A.P.), MH30854 (A.P.), MH18905 (J.A.Y.), AA05965 (A.P.), AA10723 (E.V.S.), and the Department of Veterans Affairs. Portions of this research were presented at the 25th Annual Meeting of the International Neuropsychological Society, Orlando, FL. We thank Kenneth Chow, M.A., for his statistical assistance and Brian Matsumoto, M.S. for image analysis. Deborah Cahn is now at the Department of Psychiatry & Human Behavior, Brown University. Paula Shear is now at the Department of Psychology, University of Cincinnati.

REFERENCES

- Butters, N., Granholm, E., Salmon, D., Grant, I., & Wolfe, J. (1987). Episodic and semantic memory: A comparison of amnesic and demented patients. *Journal of Clinical and Experimental Neuropsychology*, 9, 479–497.
- Cahn, D.A., Salmon, D.P., Butters, N., Wiederholt, W.C., Corey-Bloom, J., Edelstein, S.L., & Barrett-Connor, E. (1995). Detection of dementia of the Alzheimer type in a population-based sample: Neuropsychological test performance. *Journal of the International Neuropsychological Society*, 1, 252–260.
- Delis, D.C., Kramer, J.H., Kaplan, E., & Ober, B.A. (1987). *The California Verbal Learning Test*. New York: The Psychological Corporation.
- Deweert, B., Lehericy, S., Pillon, B., Baulac, M., Chiras, J., Marsault, C., Agid, Y., & Dubois, B. (1995). Memory disorders in probable Alzheimer's disease: The role of hippocampal atrophy as shown with MRI. *Journal of Neurology, Neurosurgery, and Psychiatry*, 58, 590–597.
- Diesfeldt, H.F. (1990). Recognition memory for words and faces in primary degenerative dementia of the Alzheimer's type and normal old age. *Journal of Clinical and Experimental Neuropsychology*, 12, 931–945.
- Fama, R., Sullivan, E.V., Shear, P.K., Marsh, L., Yesavage, J.A., Tinklenberg, J.R., Lim, K.O., & Pfefferbaum, A. (1997). Selective cortical and hippocampal volume correlates of Mattis Dementia Rating subscales in Alzheimer's disease. *Archives of Neurology*, 54, 719–728.
- Folstein, M.F., Folstein, S.E., & McHugh, P.R. (1975). "Minimal state": A practical method for grading the cognitive state of patients for the clinician. *Journal of Psychiatry Research*, 12, 189–198.
- Golomb, J., deLeon, M.J., Kluger, A., George, A.E., Tarshish, C., & Ferris, S.H. (1993). Hippocampal atrophy in normal aging: An association with recent memory impairment. *Archives of Neurology*, 50, 967–973.
- Golomb, J., Kluger, A., deLeon, M.J., Ferris, S.H., Convit, A., Mittelman, M.S., Cohen, J., Rusinek, H., DeSanti, S., & George, A.E. (1994). Hippocampal formation size in normal human aging: A correlate of delayed secondary memory performance. *Learning and Memory*, 1, 45–54.
- Gordon, D.P. (1983). The influence of sex on the development of lateralization of speech. *Neuropsychologia*, 21, 139–146.
- Grober, E. & Buschke, H. (1987). Genuine memory deficits in dementia. *Developmental Neuropsychology*, 3, 13–36.
- Hiscock, M., Israelian, M., Inch, R., Jacek, C., & Hiscock-Kalil, C. (1995). Is there a sex difference in human laterality? II. An exhaustive survey of visual laterality studies from six neuro-psychology journals. *Journal of Clinical and Experimental Neuropsychology*, 17, 590–610.
- Khachaturian, Z.S. (1985). Diagnosis of Alzheimer's disease. *Archives of Neurology*, 42, 1097–1105.
- Lezak, M.D. (1995). *Neuropsychological assessment* (3rd ed.). New York: Oxford University Press.
- Lim, K.O. & Pfefferbaum, A. (1989). Segmentation of MR brain images into cerebrospinal fluid spaces, white and gray matter. *Journal of Computer Assisted Tomography*, 13, 588–593.
- Lim, K.O., Zipursky, R.B., Murphy, G.M., & Pfefferbaum, A. (1990). In vivo quantification of the limbic system using MRI: Effects of normal aging. *Psychiatry Research: Neuroimaging*, 35, 15–26.
- Lim, K.O., Zipursky, R.B., Sullivan, E.V., & Pfefferbaum, A. (1996). Cortical gray matter deficits in schizophrenia: A replication. *Schizophrenia Research*, 20, 157–164.
- Mathalon, D.H., Sullivan, E.V., Rawles, J.M., & Pfefferbaum, A. (1993a). Correction for head size in brain imaging measurements. *Psychiatry Research: Neuroimaging*, 50, 121–139.
- Mathalon, D.H., Sullivan, E.V., Rawles, J.M., & Pfefferbaum, A. (1993b). Correction for head size in brain imaging measurements. [Letter to the editor]. *Psychiatry Research: Neuroimaging*, 50, 284.
- Mattis, S. (1976). Mental status examination for organic mental syndrome in the elderly patient. In L. Bellack & T.B. Karasu (Eds.), *Geriatric psychiatry* (pp. 77–120). New York: Grune & Stratton.
- Mattis, S. (1988). *Dementia Rating Scale (DRS) professional manual*. Odessa, FL: Psychological Assessment Resources, Inc.
- McKhann, G., Drachman, D., Folstein, M., & Katzman, R. (1984). Clinical diagnosis of Alzheimer's disease: Report of the NINCDS-ADRDA Work Group under the auspices of Department of Health and Human Services Task Force on Alzheimer's disease. *Neurology*, 37, 939–944.
- Milner, B. (1965). Memory disturbance after bilateral hippocampal lesions. In P.M. Milner & S. Glickman (Eds.), *Cognitive processes and the brain* (pp. 97–111). Princeton, NJ: Van Nostrand.
- Milner, B. (1970). Memory and the medial temporal regions of the brain. In K.H. Pribram & D.E. Broadbent (Eds.), *Biology of memory* (pp. 29–50). New York: Academic Press.
- Milner, B. (1971). Interhemispheric differences in the localization of psychological processes in man. *British Medical Bulletin*, 27, 272–277.
- Milner, B. (1972). Disorders of learning and memory after temporal lesions in man. *Clinical Neurosurgery*, 19, 421–446.
- Morris, J.C., Heyman, A., Mohs, R.C., Hughes, J.P., Belle, G.V., Fillenbaum, G., Mellits, E.D., & Clark, C. (1989). The Consortium to Establish a Registry for Alzheimer's disease (CERAD). Part I. Clinical and neuropsychological assessment of Alzheimer's disease. *Neurology*, 39, 1159–1165.
- Morris, R.G., Abrahams, S., & Polkey, C.E. (1995). Recognition memory for words and faces following unilateral temporal lobectomy. *British Journal of Clinical Psychology*, 34, 571–576.
- Moss, M.B., Albert, M.S., Butters, N., & Payne, M. (1986). Differential patterns of memory loss among patients with Alzheimer's disease, Huntington's disease, and alcoholic Korsakoff's syndrome. *Archives of Neurology*, 43, 239–246.
- Pfefferbaum, A., Mathalon, D.H., Sullivan, E.V., Rawles, J.M., Zipursky, R.B., & Lim, K.O. (1994). A quantitative magnetic resonance imaging study of changes in brain morphology from infancy to late adulthood. *Archives of Neurology*, 51, 874–887.

- Raz, N., Raz, S., Yeo, R.A., Turkheimer, E., Bigler, E.D., & Cullum, C.M. (1987). Relationship between cognitive and morphological asymmetry in dementia of the Alzheimer type: A CT scan study. *International Journal of Neuroscience*, *35*, 225–232.
- Salmon, D.P., Granholm, E., McCullough, D., Butters, N., & Grant, I. (1989). Recognition memory span in mildly and moderately demented patients with Alzheimer's disease. *Journal of Clinical and Experimental Neuropsychology*, *11*, 429–443.
- Smith, M.L. (1989). Memory disorders associated with temporal-lobe lesions. In F. Boller & J. Grafman (Eds.), *Handbook of neuropsychology*, Vol. 3 (pp. 91–106). Amsterdam: Elsevier.
- Squire, L.R. & Zola-Morgan, S. (1991). The medial temporal lobe memory system. *Science*, *253*, 1380–1386.
- Stout, J.C., Jernigan, T.L., Archibald, S.L., & Salmon, D.P. (1996). Association of dementia severity with cortical gray matter and abnormal white matter volumes in dementia of the Alzheimer type. *Archives of Neurology*, *53*, 742–749.
- Sullivan, E.V., Cahn, D.A., Fama, R., & Shear, P.K. (in press). Structural neuroimaging correlates of memory dysfunction in neurodegenerative disease. In A.I. Tröster (Ed.), *Memory in neurodegenerative disease*. New York: Cambridge University Press.
- Sullivan, E.V., Marsh, L., Mathalon, D.H., Lim, K.O., & Pfefferbaum, A. (1995). Age-related decline in MRI volumes of temporal lobe gray matter but not hippocampus. *Neurobiology of Aging*, *16*, 591–606.
- Warrington, E. (1984). *Recognition Memory Test manual*. Windsor, U.K.: Nelson Publishing Company.
- Wechsler, D. (1945). A standardized memory scale for clinical use. *Journal of Psychology*, *19*, 87–95.
- Zipursky, R.B., Marsh, L., Lim, K.O., DeMent, S., Shear, P.K., Sullivan, E.V., Murphy, G.M., Csernansky, J.G., & Pfefferbaum, A. (1994). Volumetric MRI assessment of temporal lobe structures in schizophrenia. *Biological Psychiatry*, *35*, 501–516.
- Zola-Morgan, S., Squire, L.R., & Amaral, D.G. (1986). Human amnesia and the medial temporal region: Enduring memory impairment following a bilateral lesion limited to field CA1 of the hippocampus. *Journal of Neuroscience*, *6*, 2950–2967.