

Short Communication

Maturation of medial temporal lobe response and connectivity during memory encoding

V. Menon^{a,b,c,*}, J.M. Boyett-Anderson^a, A.L. Reiss^a

^a*Department of Psychiatry and Behavioral Sciences, Stanford University School of Medicine, Stanford, CA 94305-5719, USA*

^b*Program in Neuroscience, Stanford University School of Medicine, Stanford, CA 94305, USA*

^c*Neuroscience Institute at Stanford, Stanford University School of Medicine, Stanford, CA 94305, USA*

Accepted 8 July 2005

Available online 24 August 2005

Abstract

The medial temporal lobe (MTL) plays an important role in memory encoding. The development and maturation of MTL and other brain regions involved in memory encoding are, however, poorly understood. We used functional magnetic resonance imaging to examine activation and effective connectivity of the MTL in children and adolescents during encoding of outdoor visual scenes. Here, we show that MTL response decreases with age whereas its connectivity with the left dorsolateral prefrontal cortex (PFC) increases with age. Our findings provide evidence for dissociable maturation of local and distributed memory encoding processes involving the MTL and furthermore suggest that increased functional interactions between the MTL and the PFC may underlie the development of more effective memory encoding strategies.

© 2005 Elsevier B.V. All rights reserved.

Theme: Neural basis of behavior

Topic: Cognition

Keywords: Medial temporal lobe; Prefrontal cortex; Hippocampus; Entorhinal cortex

1. Introduction

Episodic memory enables us to remember past experiences. Children as young as 3 to 4 years of age can form episodic memories for pictures [3]. Performance on episodic memory tasks improves until the age of 11, at which point memory abilities begin to resemble those of adults in several respects [26]. However, the capacity of memory systems, the speed of retrieval, and the strategies used to remember continue to develop into young adulthood [6,17,18]. Despite the relative wealth of knowledge about the development of memory abilities, little is known about the neural organization of memory in children and adolescents. In adults, a

wide range of electrophysiological, lesion and neuroimaging studies have shown the critical involvement of the MTL, including the hippocampal region, in memory encoding [12]. The limited neurodevelopmental data available to date suggest that prenatal hippocampal damage can lead to permanent impairment of episodic memory [17]. Furthermore, it has been argued that the malleability of brain systems in infants and 1- to 4-year-old children diminishes the ability to recall autobiographical information about this period [23]. Lesion studies in non-human primates have provided evidence that the hippocampus shows a developmental continuum that affects memory abilities from infancy to adulthood [5].

In this study, we examine the neural bases of memory encoding in children and adolescents, ages 11 to 19, using both functional and structural magnetic resonance imaging (fMRI). Functional brain images were acquired while subjects viewed pictures of outdoor scenes. This task was

* Corresponding author. Program in Neuroscience and Department of Psychiatry and Behavioral Sciences, Stanford University School of Medicine, Stanford, CA 94305-5719, USA. Fax: +1 650 498 6737.

E-mail address: menon@stanford.edu (V. Menon).

shown to elicit reliable responses of the MTL in a previous fMRI study of episodic encoding in adults [21]. In a subsequent recognition memory test, the accuracy (hit rate) was not significantly correlated with age ($F(1,13) = 4.18$; $R^2 = 0.24$; $P = 0.06$) (Fig. 1A) neither was discriminability (hits minus false alarms) ($F(1,13) = 4.22$; $R^2 = 0.24$; $P = 0.06$). Overall accuracy levels were similar to those observed in previous studies [6]. However, reaction time for correctly retrieved items was inversely correlated with age ($F(1,13) = 6.40$; $R^2 = 0.33$; $P < 0.03$) (Fig. 1B).

Analysis of brain activation during memory encoding in the entire group of subjects revealed widespread responses in the striate and extrastriate regions of the occipital cortex, as well as the hippocampus, entorhinal cortex, and parahippocampal gyrus of the MTL (Fig. 2A, with additional details in Supplementary Fig. 1). We then examined whether activation in these brain regions was correlated with age. None of these brain regions showed increased activation with age. Significant age-related decreases in activation were, however, observed in the left MTL (Fig. 2B). The primary and secondary activation peaks were located in the hippocampus and entorhinal cortex, respectively. The average activation in this cluster of left MTL voxels showed significant decreases with age ($F(1,13) = 14.09$; $R^2 = 0.52$; $P < 0.002$) (Fig. 2C).

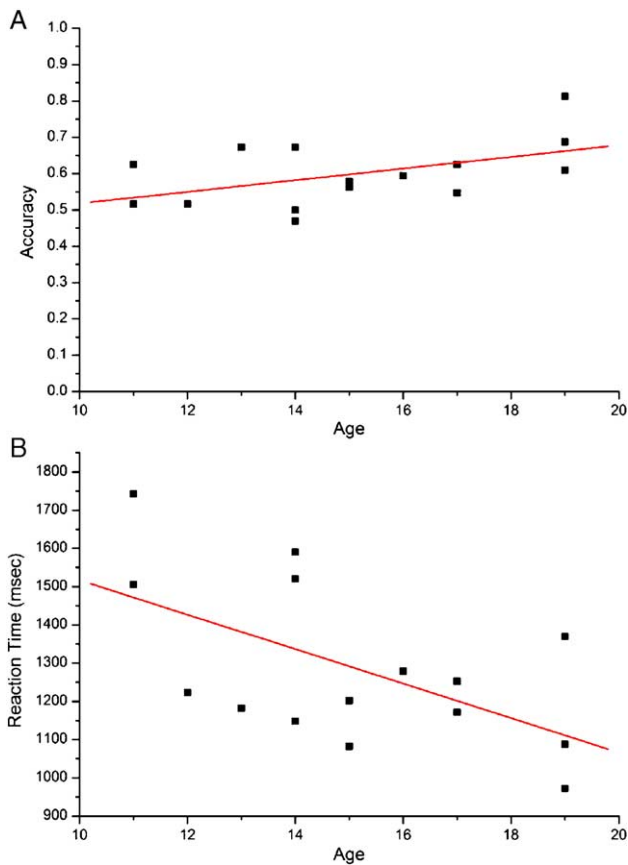


Fig. 1. Changes in subsequent memory performance with age. (A) Accuracy was not correlated with age, while (B) reaction time for correct responses was negatively correlated with age.

Because performance changes with age showed a trend towards significance, we reanalyzed the data looking for age-related changes after covarying out recognition accuracy. We obtained very similar results in this case, suggesting that most of the variance in the fMRI activation can be accounted for by age, analogous to our previous study of working memory development [19]. The issue of age-related changes in reaction time (RT) is more complex—across a range of fMRI tasks, we have observed that during both the experimental as well as very simple control conditions RT decreases with age [19,25], perhaps reflecting continued maturation of white matter tracts and signaling between various brain regions. In the present study, it is important to note that the RTs in question refer to the speed of subsequent retrieval processes, and the relationship with brain responses during memory encoding may be more tenuous. Taken together, these results suggest that increased activation seen in the hippocampus and the entorhinal cortex regions of the MTL in younger subjects may reflect the recruitment of greater processing resources to sustain appropriate memory representations [9].

We next examined whether the age-related fMRI activation changes observed in our study are a consequence of functional maturation alone or whether they might also reflect local changes in underlying gray matter. Gray matter density (GMD) in several brain regions is known to change with development [27] and with increased experience and expertise [8]. For example, Sowell et al. have reported age-related decreases in GMD within some of the MTL and PFC regions that are commonly activated during memory encoding [27]. To examine whether functional activation changes with age in our study are associated with anatomical changes, we examined changes in gray matter intensity within the MTL cluster identified in Fig. 2B. GMD in this MTL cluster was not correlated with age ($F(1,12) = 0.76$; $R^2 = 0.06$; $P > 0.30$) (Fig. 2D). These results indicate that age-related decreases in MTL activation during memory encoding do not arise from lower GMD in older subjects. Taken together with our fMRI findings, these results suggest a process of functional maturation and increased efficiency (i.e. less processing resources used for similar performance) in the MTL with development.

To further explore the idea of increased processing efficiency, we examined age-related changes in the effective connectivity of the hippocampus and entorhinal cortex. Effective connectivity is defined as the influence of one brain region upon another, after discounting the influence of task-related effects as well as the effects of a common driving input [11]. This analysis revealed significant age-related increases in connectivity of the left entorhinal cortex with the left dorsolateral PFC ($F(1,13) = 17.00$; $R^2 = 0.57$; $P < 0.001$), as shown in Fig. 3A and B. There were no increases with age in task-related activity in this PFC cluster ($F(1,13) = 0.01$; $R^2 = 0.006$; $P = 0.93$) (Fig. 3C). GMD in this cluster was also not significantly related to age ($F(1,12) = 0.24$; $R^2 = 0.02$; $P = 0.62$), (Fig. 3D). No brain

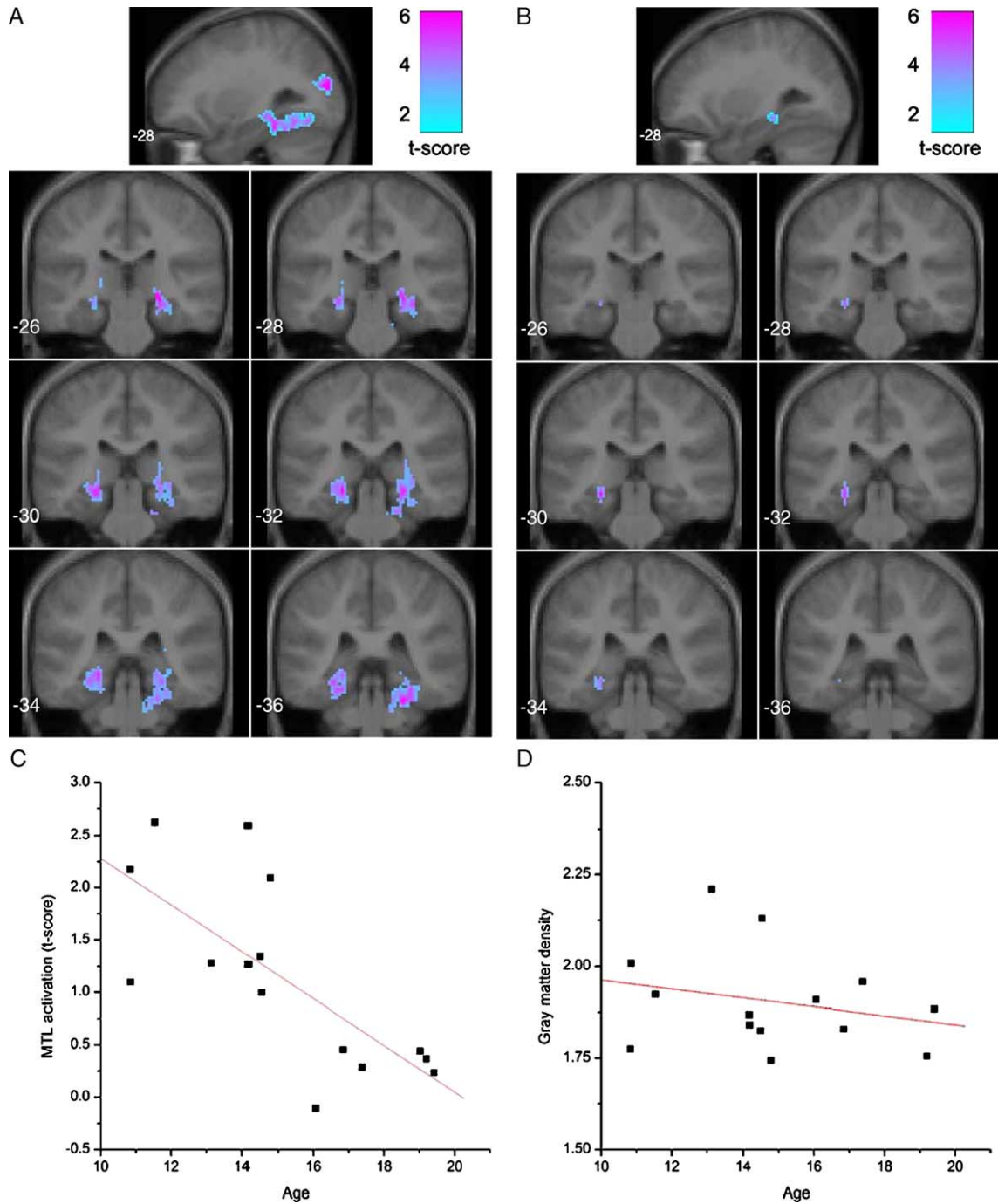


Fig. 2. (A) Coronal and sagittal views of the MTL and other areas that showed significant activation during visual memory encoding. (B) Age-related changes were localized to the left posterior hippocampus (Talairach coordinates: $-26, -30, -7$) and the entorhinal cortex (Talairach coordinates: $-26, -32, -14$). All activations were significant at $P < 0.01$ after correction for multiple comparisons. (C) Age-related changes are further clarified using the average t score, for each subject, within the MTL cluster identified in panel (B). Activations showed decreases with age ($P < 0.001$). (D) Within the MTL regions identified in Fig. 1B, gray matter density (GMD) did not show significant changes with age ($P = 0.3$).

regions showed age-related decreases in effective connectivity with either the entorhinal cortex or the hippocampus. It has been argued in the neuropsychological literature that the PFC facilitates the use of strategies in memory tasks, and Nelson et al. have argued that changes in memory after the age of 6 or so years may arise from changes in connectivity between the MTL and the PFC regions that have the longest

developmental trajectories [22]. Our data are consistent with this view and show for the first time how the PFC may play a critical role in memory development, via the development of functional connections with the MTL.

It is noteworthy that the entorhinal cortex, but not the hippocampus proper, showed increased effective connectivity with the left dorsolateral PFC. The entorhinal cortex is

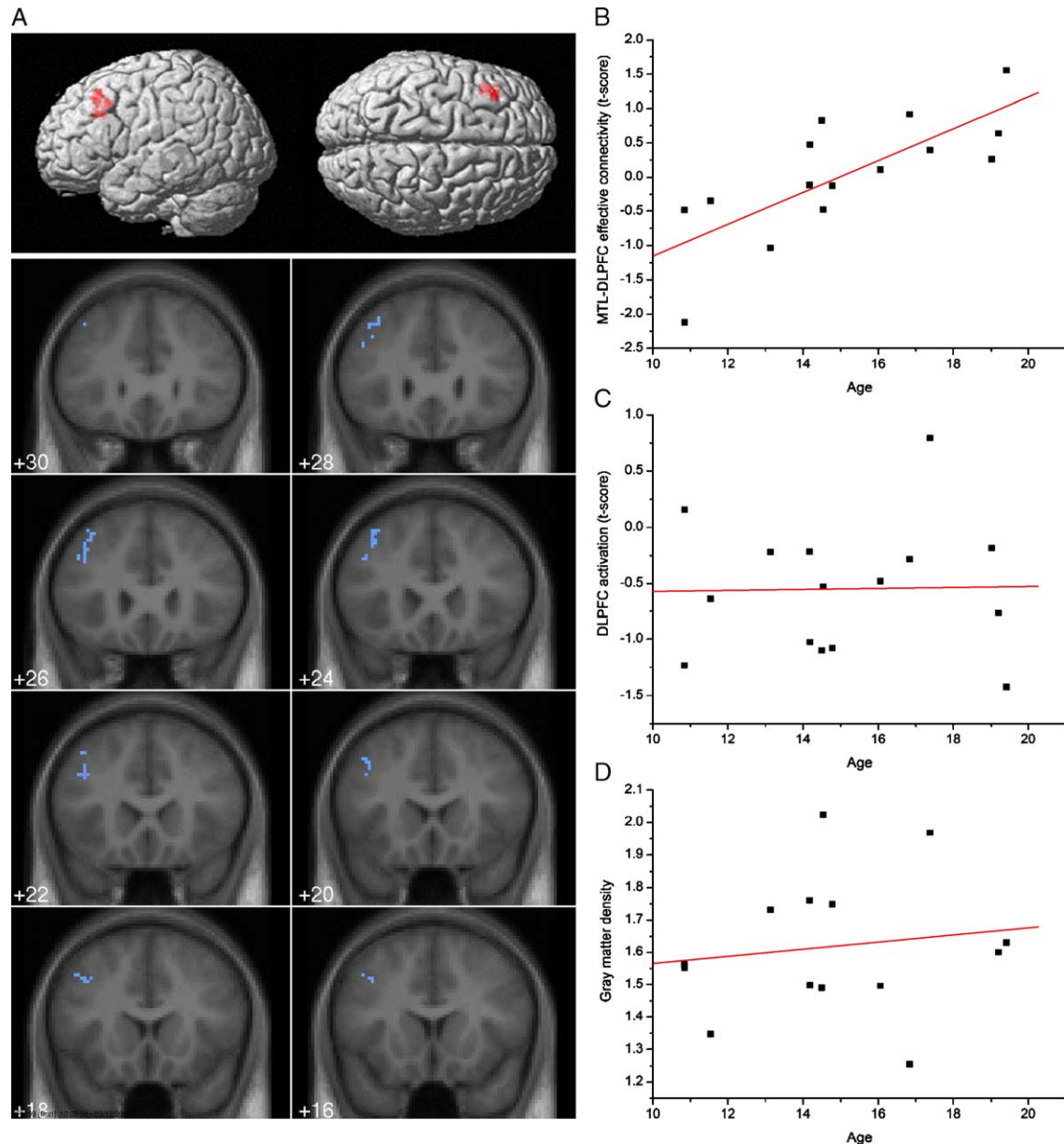


Fig. 3. (A) Surface rendering and coronal views of brain areas that showed significant age-related increases in effective connectivity with the MTL. Only the left dorsolateral PFC (DLPFC) showed increased connectivity with the left entorhinal subregion of the MTL. All activations were significant at $P < 0.01$ after correction for multiple comparisons. (B) Age-related changes in effective connectivity between the left MTL and voxels in the left DLPFC cluster identified in panel (A). Connectivity between the MTL and DLPFC regions increased with age ($P < 0.002$). (C) Task-related activation was not correlated with age in the left DLPFC cluster identified in panel (A) ($P = 0.93$). (D) Within the DLPFC regions identified in panel (A), gray matter density (GMD) was not correlated with age ($P = 0.62$).

the principal site of cortical input into the hippocampus. In particular, it mediates the convergence of high-level input from visual association cortex into the hippocampus [29]. Age-related increases in connectivity between the entorhinal cortex and dorsolateral PFC were restricted to the left hemisphere. While the specific contributions of each hemisphere to memory encoding are currently unknown, there tends to be a greater right lateralization of activation for visual compared to verbal material [10]. Nevertheless, for outdoor visual scenes such as those used in our study, both PFC and MTL activations tend to be bilateral, and the

lateralization of encoding may be more determined by the degree to which the stimuli lend themselves to verbalization rather than whether the stimuli are verbal or visuo-spatial [14]. One influential model of episodic memory has suggested a process-specific description of asymmetric PFC activation, arguing that left PFC is more involved in episodic memory encoding, whereas right PFC is more involved in episodic memory retrieval [15]. The question of whether the left lateralized developmental changes observed in our study are related to verbalization or to other intrinsic encoding mechanisms remains to be investigated.

Our findings point to dissociable developmental changes involving local and distributed processes serving memory encoding. On the one hand, there is decreased reliance on the MTL with age; on the other hand, this decrease is counter-balanced by increased interaction of the MTL with the PFC. The effectiveness of encoding strategies, particularly those related to source monitoring, continues to increase through adolescence as does awareness of deliberate strategy use [16]. This is consistent with the finding that memory performance in older children tends to differ from memory performance in adults more in retrieval speed (see, for example, Fig. 1B) and source identification than in accurate item recognition [6]. Stronger interactions between the MTL and PFC may also underlie greater awareness and more robust learning in older subjects [20]. Taken together, these findings suggest that with age the ability to form more versatile memory representations develops. This may permit more difficult judgments about source and recency, which require greater involvement of control mechanisms mediated by the PFC.

One shortcoming of this study is that we used a blocked fMRI design in our initial attempt to identify the neuro-developmental trajectory of memory encoding. There are two issues that bear on the interpretation of our findings. One is that there may have been some encoding of the stimuli in the control condition. However, this effect is minimal given that the same stimulus is presented over and over again in each control block. Consistent with this view, no subregions of the MTL and the PFC showed greater response to the control, compared to the experimental, condition. A second issue is that the items in the experimental condition are novel, whereas the items in the control condition are repeated; therefore, it is not completely clear if the identified brain regions are those related to memory encoding per se or those responding to stimulus novelty. To the extent that stimulus novelty generally results in obligatory encoding, a strong relationship with memory encoding is likely in the several subregions of the MTL that showed age-related decreases in activation in our study [28]. This is clearly an issue that warrants further investigation with appropriate event-related designs.

2. Methods

2.1. Subjects

Twenty-five healthy children and adolescents participated in this study after providing written informed consent. They were right-handed as determined by the Edinburgh Handedness Inventory [24]. Subjects were screened for neurological and developmental disorders and for psychiatric conditions using the Symptom Checklist-Revised (SCL-90-R) [7] for adolescents and young adults or the Child Behavior Checklist (CBCL) [1] for children. All subjects had SCL-90-R or CBCL *t* scores within one standard deviation of the mean of a normative standardized

sample. fMRI data from ten subjects could not be included in the study due to excessive movement during the scan (≥ 3 mm translational movement in any dimension or 3° rotational movement around any axis); therefore, we analyzed data from fifteen subjects (6 males, 9 females) aged 11–19 (mean = 15.1 ± 2.7 years).

2.2. Neuropsychological assessment

IQ estimates were obtained for each subject based on the Wechsler Adult Intelligence Scale-Third Edition (WAIS-III) [32] for subjects over 16 years and the Wechsler Intelligence Scale for Children-III (WISC-III) [31] for subjects age 16 and younger. Verbal IQ (VIQ), Performance IQ (PIQ), and Full Scale IQ (FSIQ) scores were derived for each subject. Within the subjects used in our study, the mean full scale IQ (FSIQ) score for the sample was 115 ± 12 (range: 93–129); age and FSIQ were not correlated ($F(1,13) = 1.28$; $R^2 = 0.09$; $P = 0.27$). Similarly, verbal and performance IQ were also not correlated with age.

2.3. Experimental design

Subjects viewed photographs of natural outdoor scenes presented in one of two conditions: (1) experimental and (2) control. In the experimental condition, subjects viewed a new visual scene every 3 s. In the control condition, the same scene was presented every 3 s. The experiment began with a 30-s passive fixation epoch to allow the fMRI response to equilibrate. This was followed by twelve 24-s epochs that alternated between the two task conditions. The task concluded with a 30-s passive fixation epoch (total time: 5 min and 48 s). Thus, only one scene was used in the control condition. In the experimental condition, we used 8 scenes in each block times 6 blocks for a total of 48 scenes. Subjects were instructed to study and remember the pictures.

Ten minutes following the MRI scan, a simple yes/no recognition test was used to assess accuracy of memory encoding. Subjects had to answer whether they had seen the picture when they were in the MRI scanner. Subjects were presented with 64 visual scenes; two-thirds of the scenes were chosen from the stimuli previously seen in the MRI scanner, the remaining scenes were novel.

2.4. Behavioral data analysis

Memory accuracy was determined for each subject from a post-scan retrieval test. Accuracy was defined as the percentage of scenes which subjects either (1) correctly recognized from the encoding task or (2) correctly rejected as novel.

2.5. fMRI acquisition

Images were acquired on a 1.5 T GE Signa scanner using a custom-built whole head coil that provided a 50%

advantage in signal to noise ratio over that of the standard GE coil. A custom-built head holder was used to prevent head movement. Eighteen axial slices (6 mm thick, 1 mm skip) parallel to the anterior and posterior commissures, covering the whole brain, were imaged with a temporal resolution of 2 s using a T2*-weighted gradient echo spiral pulse sequence (TR = 2000 ms, TE = 40 ms, flip angle = 89° and 1 interleave) [13]. The field of view was 24 cm, and the effective inplane spatial resolution was 3.75 mm. To aid in localization of functional data, a high resolution T1-weighted spoiled grass gradient recalled (SPGR) 3D MRI sequence with the following parameters was used: TR = 24 ms; TE = 5 ms; flip angle = 40°; 24 cm field of view; 124 slices in coronal plane; 256 × 192 matrix.

2.6. fMRI analysis

For each time point, images were reconstructed by inverse Fourier transform into 64 × 64 × 18 matrices (voxel size: 3.75 × 3.75 × 7 mm). Functional MRI data were pre-processed using Statistical Parametric Mapping (SPM99) software (Wellcome Department of Cognitive Neurology, London, England). Images were corrected for movement, and normalized to stereotaxic Talairach coordinates [30]. Any subject with more than 3 cm of translation or more than 3° of rotation on any axis was excluded from further analysis. Images were then resampled every 2 mm using sinc interpolation and smoothed with a 4 mm Gaussian kernel.

Statistical analysis was performed using SPM99 as described in detail elsewhere [2]. Voxel-wise *t* statistics were normalized to *Z* scores to provide a statistical measure of activation that is independent of sample size. Group analysis of whole brain activation was performed using a random-effects model with a two-stage hierarchical procedure, thereby ensuring that only brain regions showing robust age-related activation changes would be found significant [2]. In the first step, images contrasting the experimental and control conditions were generated for each subject. In the second step, these contrast images were analyzed using a general linear model with age as a covariate of interest. Regression analysis was used to determine voxel-wise *Z* statistics corresponding to age-related increases and decreases in activation. Significant clusters of activation were determined using height ($Z = 2.33$; $P < 0.01$) and extent ($P < 0.01$) thresholds, corrected at the cluster level for multiple comparisons.

2.7. Structural and functional changes with age

To investigate whether age-related changes in brain activation are associated with anatomical changes, we examined changes in underlying GMD within the fMRI-activation clusters identified in the previous section. Within these clusters, we used regression analysis to examine age-related changes in GMD. For this purpose, T1-weighted images were first segmented [4], and the resultant gray

matter images were smoothed using a 4 mm Gaussian kernel (same smoothing kernel as the one used in the fMRI data analysis). For each subject, gray matter intensities were globally normalized to 1, and intensities were averaged across all voxels in the fMRI-activation cluster. A parallel analysis also examined changes in fMRI activation in these clusters. For this purpose, voxel-wise *t* scores were averaged across all voxels in the cluster.

2.8. Effective connectivity analysis

Effective connectivity was modeled as a psycho-physiological interaction (PPI), defined as the context-dependent interaction of brain regions [11]. We determined the brain regions that showed significant effective connectivity with the MTL. Voxel-wise regression analysis was used to derive the estimated response to each trial of interest (e.g. experimental or control); the time series corresponding to this response were then extracted from each region of interest (ROI). Two spherical ROIs of 2-mm radius were used, centered on the first and second maxima in the MTL cluster. These time series were mean-corrected and high-pass filtered ($f < 1/120$) to remove low-frequency signal drifts. The PPI regressor was computed as the time series from the MTL, scaled by the task vector (1 for “experimental” time point and -1 otherwise) and then entered into a regression analysis along with the main task effects and the raw unfiltered time series from the MTL. Contrast images corresponding to the PPI term were generated and further analyzed using a general linear model with age as a covariate of interest.

Acknowledgments

Supported by NIH grants HD40761, MH50047 and HD47520 to VM. It is a pleasure to thank the reviewers for their comments and suggestions which have helped to improve our manuscript.

Appendix A. Supplementary data

Supplementary data associated with this article can be found, in the online version, at [doi:10.1016/j.cogbrainres.2005.07.007](https://doi.org/10.1016/j.cogbrainres.2005.07.007).

References

- [1] T.M. Achenbach, C.S. Edelbrock, Behavioral problems and competencies reported by parents of normal and disturbed children aged four through sixteen, *Monogr. Soc. Res. Child Dev.* 46 (1) (1981) 1–82.
- [2] N.E. Adleman, V. Menon, C.M. Blasey, C.D. White, I.S. Warsofsky, G.H. Glover, A.L. Reiss, A developmental fMRI study of the Stroop Color–Word Task, *NeuroImage* 16 (1) (2002) 61–75.
- [3] M.E. Arterberry, M.M. Milburn, H.L. Loza, A.S. Willert, Retrieval of

- episodic information from memory: comparisons among 3- and 4-year-olds, 7- and 8-year-olds, and adults, *J. Cogn. Dev.* 2 (3) (2001) 283–305.
- [4] J. Ashburner, K.J. Friston, Voxel-based morphometry—The methods, *NeuroImage* 11 (6 Pt. 1) (2000) 805–821.
- [5] J. Bachevalier, F. Vargha-Khadem, The primate hippocampus: ontogeny, early insult and memory, *Curr. Opin. Neurobiol.* 15 (2) (2005) 168–174.
- [6] Y.M. Cycowicz, D. Friedman, J.G. Snodgrass, M. Duff, Recognition and source memory for pictures in children and adults, *Neuropsychologia* 39 (3) (2001) 255–267.
- [7] L.R. Derogatis, K.L. Savitz, The SCL-90-R, brief symptom inventory, and matching clinical rating scales, in: M.E. Maruish (Ed.), *The Use of Psychological Testing for Treatment Planning and Outcomes Assessment*, second ed., Lawrence Erlbaum Associates, Inc., Mahwah, NJ, 1999, pp. 679–724.
- [8] B. Draganski, C. Gaser, V. Busch, G. Sshuierer, U. Bogdahn, A. May, Neuroplasticity: changes in grey matter induced by training, *Nature* 427 (2004) 311–312.
- [9] H. Eichenbaum, N.J. Cohen, *From Conditioning to Conscious Recollection: Memory Systems of the Brain*, Oxford Univ., Upper Saddle River, NJ, 2001.
- [10] P.C. Fletcher, R.N. Henson, Frontal lobes and human memory: insights from functional neuroimaging, *Brain* 124 (Pt. 5) (2001) 849–881.
- [11] K.J. Friston, C. Buechel, G.R. Fink, J. Morris, E. Rolls, R.J. Dolan, Psychophysiological and modulatory interactions in neuroimaging, *NeuroImage* 6 (3) (1997) 218–229.
- [12] J.D. Gabrieli, Functional neuroimaging of episodic memory, in: R. Cabeza, A. Kingstone (Eds.), *Handbook of Functional Neuroimaging of Cognition*, MIT Press, Cambridge, 2001, pp. 253–292.
- [13] G.H. Glover, S. Lai, Self-navigated spiral fMRI: interleaved versus single-shot, *Magn. Reson. Med.* 39 (3) (1998) 361–368.
- [14] A.J. Golby, R.A. Poldrack, J.B. Brewer, D. Spencer, J.E. Desmond, A.P. Aron, J.D.E. Gabrieli, Material-specific lateralization in the medial temporal lobe and prefrontal cortex during memory encoding, *Brain* 124 (9) (2001) 1841–1854.
- [15] R. Habib, L. Nyberg, E. Tulving, Hemispheric asymmetries of memory: the HERA model revisited, *Trends Cogn. Sci.* 7 (6) (2003) 241–245.
- [16] M.E. Huba, F.R. Vellutino, The development of visual encoding and retention skills, *J. Exp. Child Psychol.* 30 (1) (1980) 88–97.
- [17] E.B. Isaacs, F. Vargha-Khadem, K.E. Watkins, A. Lucas, M. Mishkin, D.G. Gadian, Developmental amnesia and its relationship to degree of hippocampal atrophy, *Proc. Natl. Acad. Sci. U. S. A.* 100 (22) (2003) 13060–13063.
- [18] R. Kail, Y.S. Park, Processing time, articulation time, and memory span, *J. Exp. Child Psychol.* 57 (2) (1994) 281–291.
- [19] H. Kwon, A.L. Reiss, V. Menon, Neural basis of protracted developmental changes in visuo-spatial working memory, *Proc. Natl. Acad. Sci.* 99 (20) (2002) 13336–13341.
- [20] A.R. McIntosh, M.N. Rajah, N.J. Lobaugh, Functional connectivity of the medial temporal lobe relates to learning and awareness, *J. Neurosci.* 23 (16) (2003) 6520–6528.
- [21] V. Menon, C.D. White, S. Eliez, G.H. Glover, A.L. Reiss, Analysis of distributed neural system involved in spatial, novelty and memory processing, *Hum. Brain Mapp.* 11 (2) (2000) 117–129.
- [22] C.A. Nelson, The ontogeny of human memory: a cognitive neuroscience perspective, *Dev. Psychol.* 31 (5) (1995) 723–738.
- [23] C.A. Nelson, Neural plasticity and human development: the role of early experience sculpting memory systems, *Dev. Sci.* 3 (2) (2000) 115–130.
- [24] R.C. Oldfield, The assessment and analysis of handedness: the Edinburgh inventory, *Neuropsychologia* 9 (1) (1971) 97–113.
- [25] S.M. Rivera, A.L. Reiss, M.A. Eckert, V. Menon, Developmental changes in mental arithmetic: evidence for increased functional specialization in the left inferior parietal cortex, *Cereb. Cortex* (in press).
- [26] W. Schneider, Memory development in childhood, in: U. Goswami (Ed.), *Blackwell Handbook of Childhood Cognitive Development*, Blackwell Publishers, Malden, MA, US, 2002.
- [27] E.R. Sowell, B.S. Peterson, P.M. Thompson, S.E. Welcome, A.L. Henkenius, A.W. Toga, Mapping cortical change across the human life span, *Nat. Neurosci.* 6 (3) (2003) 309–315.
- [28] B.A. Strange, R. Hurlmann, A. Duggins, H.J. Heinze, R.J. Dolan, Dissociating intentional learning from relative novelty responses in the medial temporal lobe, *NeuroImage* 25 (1) (2005) 51–62.
- [29] W.A. Suzuki, D.G. Amaral, Topographic organization of the reciprocal connections between the monkey entorhinal cortex and the perirhinal and parahippocampal cortices, *J. Neurosci.* 14 (3 Pt. 2) (1994) 1856–1877.
- [30] J. Talairach, P. Tournoux, *Co-Planar Stereotaxic Atlas of the Human Brain: A 3-Dimensional Proportional System, An Approach to Cerebral Imaging*, Thieme Medical Publishers, Stuttgart, New York, 1988.
- [31] D. Wechsler, *Wechsler Intelligence Scale for Children-Third Edition Manual*, Psychol. Corp., San Antonio, 1991.
- [32] D. Wechsler, *Wechsler Adult Intelligence Scale-Third Edition*, third ed., Psychol. Corp., San Antonio, 1997.