Evaluation of 3D T2-weighted Imaging In Breast MRI

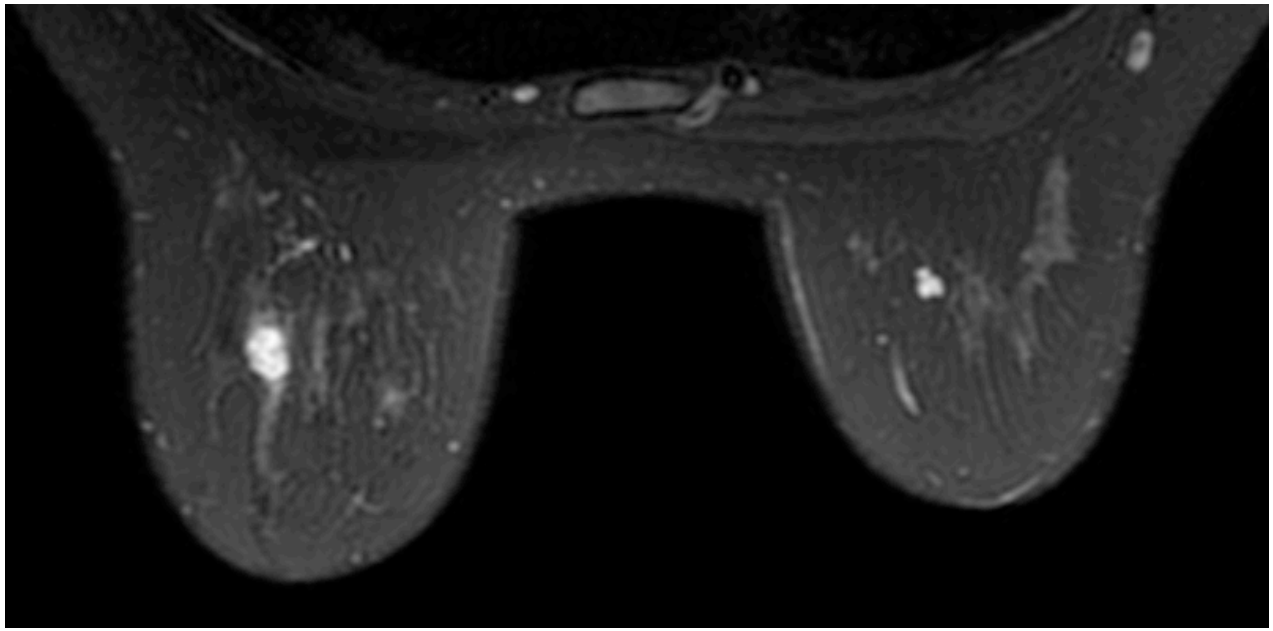

- T2 contrast
- 2D versus 3D T2-weighted MRI
- T2-weighted imaging in breast MRI
- Pilot study in breast MRI

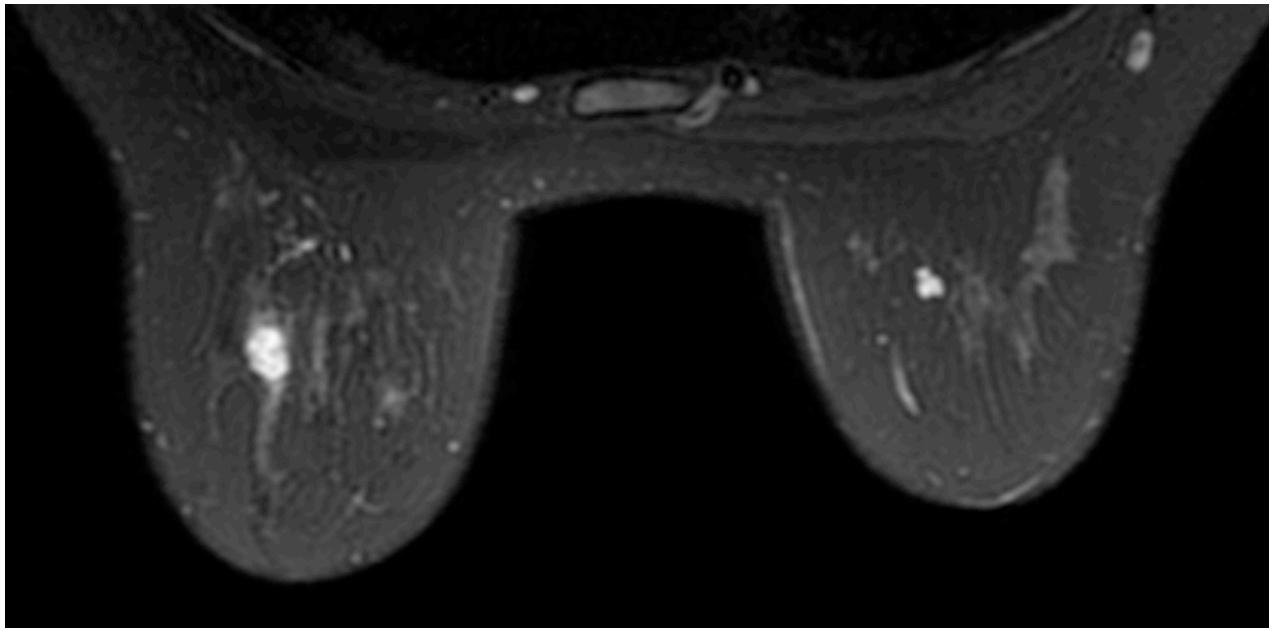

- T2 contrast
- 2D versus 3D T2-weighted MRI
- T2-weighted imaging in breast MRI
- Pilot study in breast MRI

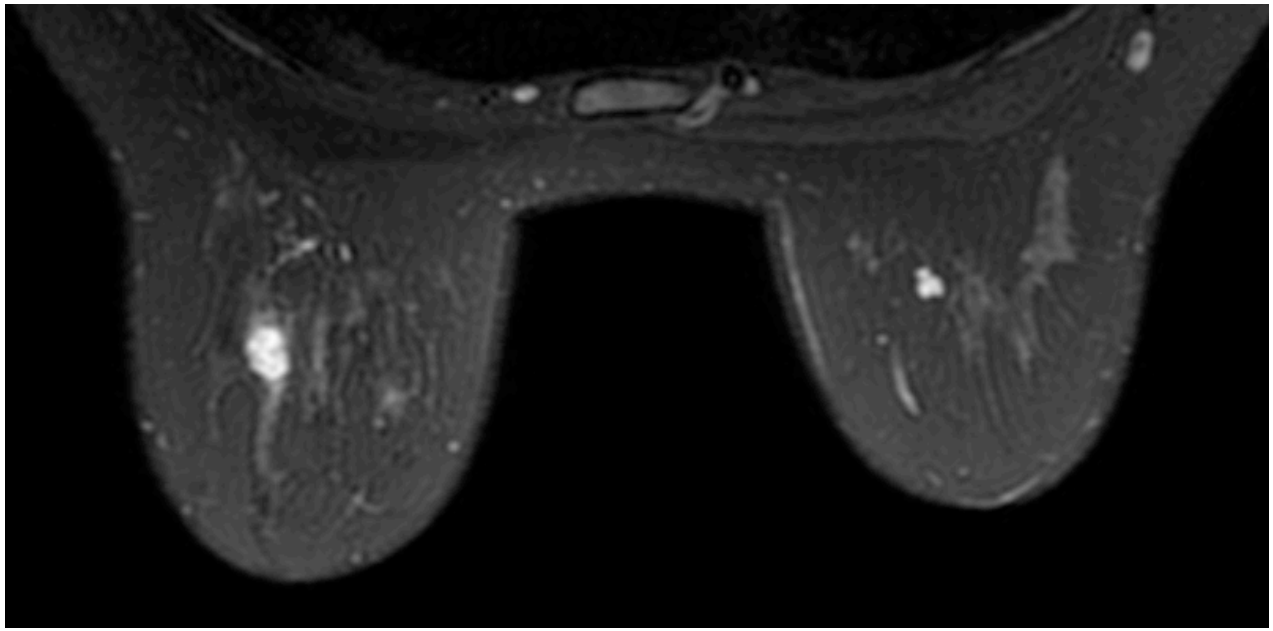

T2-weighted Contrast

- Signal changes by two mechanisms

T1 relaxation:

- spin-lattice relaxation
- return of spins their initial orientation

T2 relaxation:

- spin-spin relaxation
- interaction of nuclei with local environment

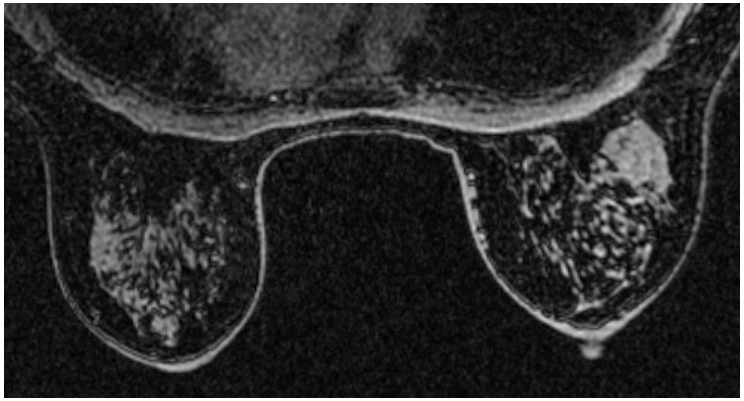

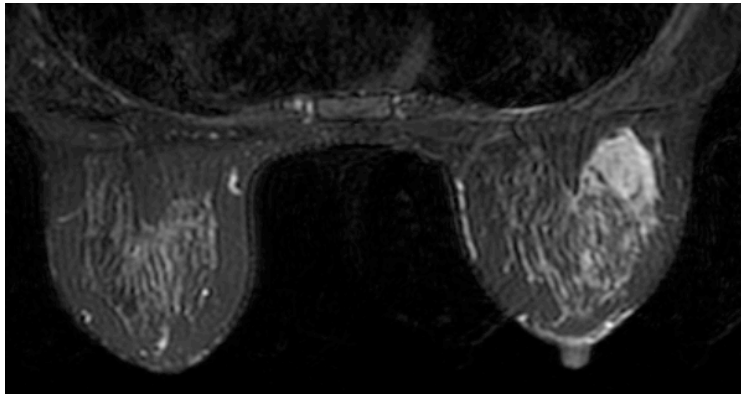

T2-weighted Contrast

- T2 < T1
- Short T2s darker, longer T2s brighter
- Fluids bright on T2, more structured or solid dark on T2

T2-weighted Contrast

- T2 < T1
- Short T2s darker, longer T2s brighter
- Fluids bright on T2, more structured or solid dark on T2
    - Cyst
    - Fluid-filled
    - Hyperintense T2-signal

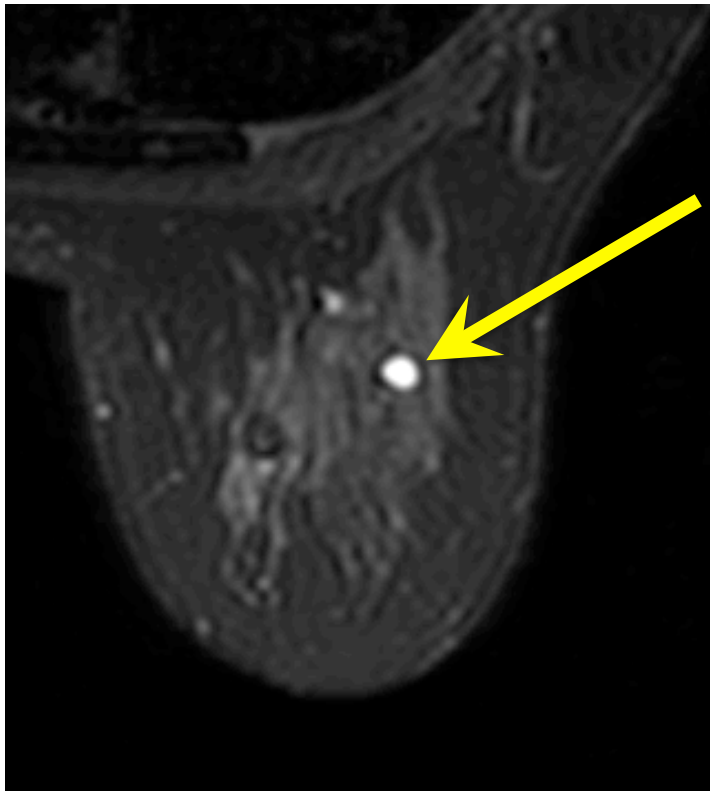

T2-weighted Contrast

- T2 < T1
- Short T2s darker, longer T2s brighter
- Fluids bright on T2, more structured or solid dark on T2
    - Invasive Ductal Carcinoma (IDC)
    - High-cellularity
    - Isointense T2-signal

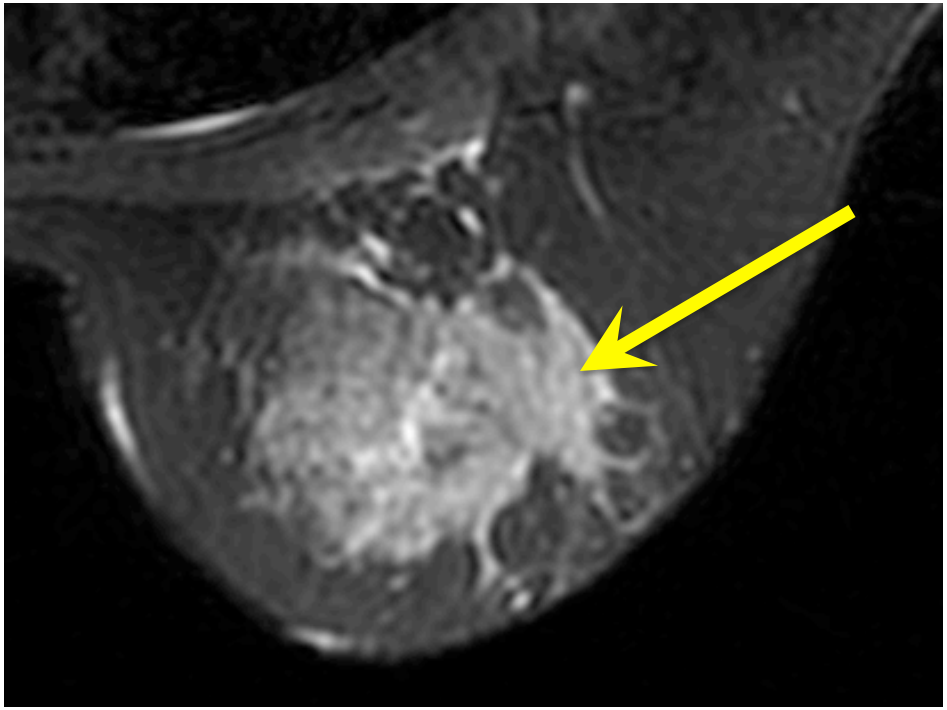

T2-weighted Contrast

- T2 < T1
- Short T2s darker, longer T2s brighter
- Fluids bright on T2, more structured or solid dark on T2
    - Mucinous carcinoma
    - High mucin component
    - Hyperintense T2-signal

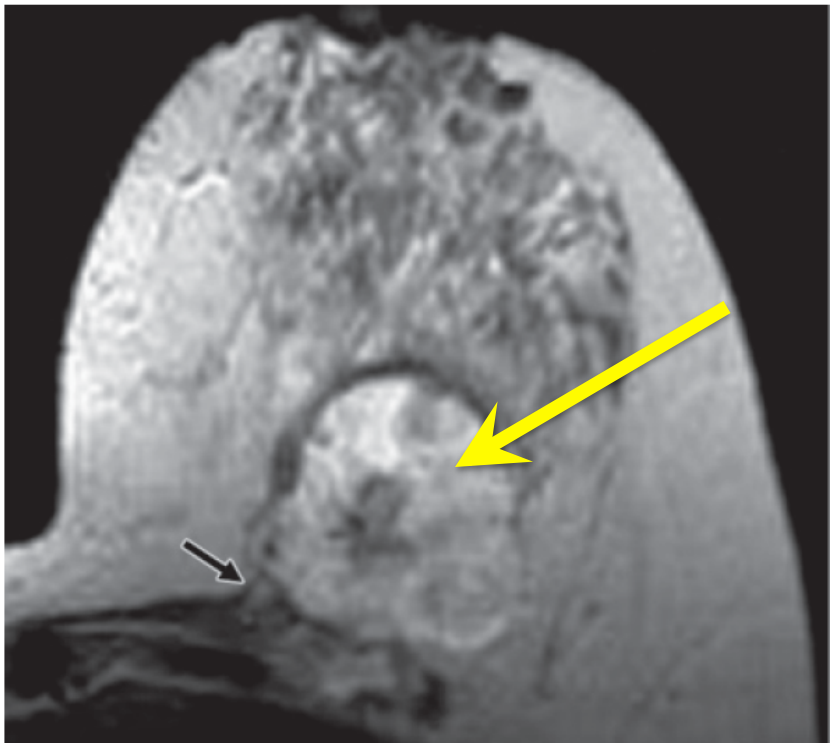

- T2 contrast
- 2D versus 3D T2-weighted MRI
- T2-weighted imaging in breast MRI
- Pilot study in breast MRI

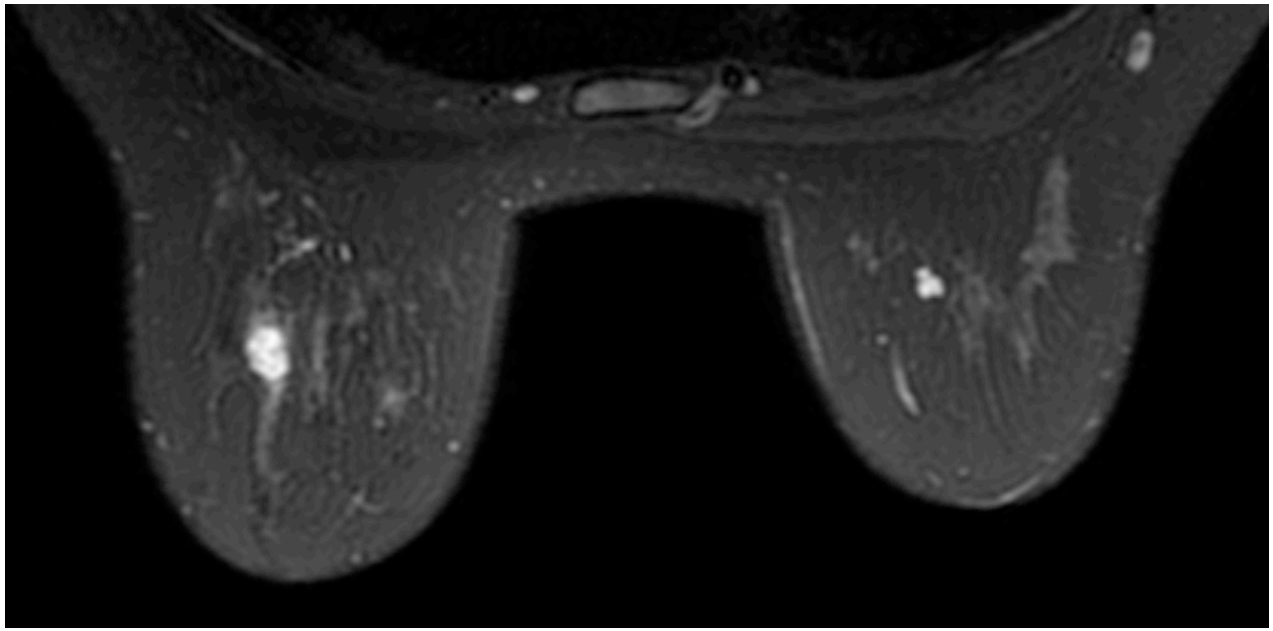

- T2 contrast
- 2D versus 3D T2-weighted MRI
- T2-weighted imaging in breast MRI
- Pilot study in breast MRI

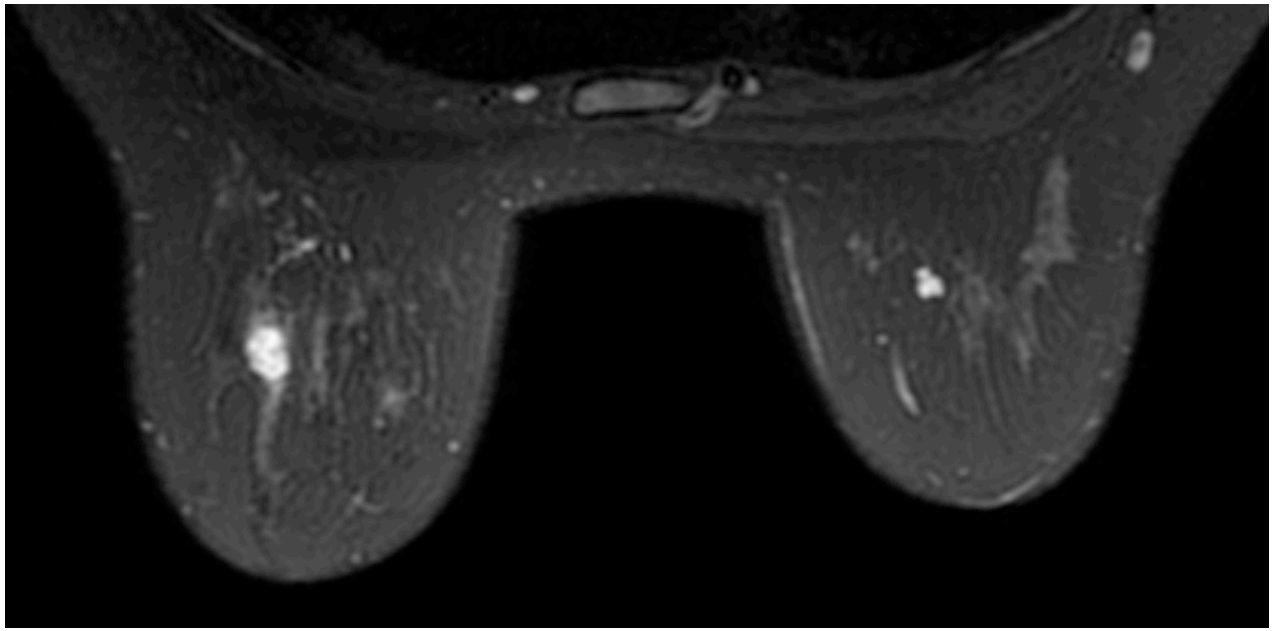

2D T2-weighted MRI

- Fast Spin Echo Acquisition
- Necessity for long TR, short signal duration

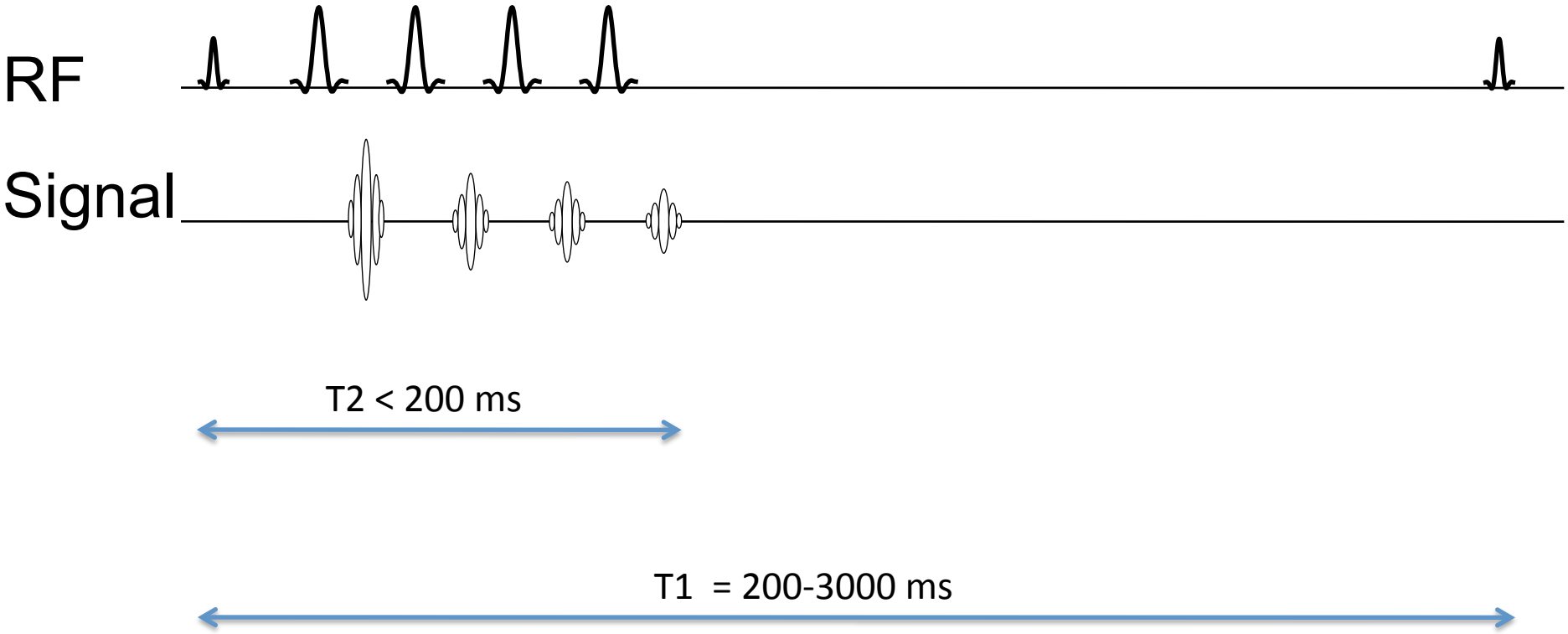

2D T2-weighted MRI

- Inefficient scan
- Long scan times for high resolution

2D T2-weighted MRI

2D FSE

- Inefficient scan
- Long scan times for high resolution
- Acquired in 2D with low through-plane resolution
- Obscure lesion morphology
- Difficult to align findings

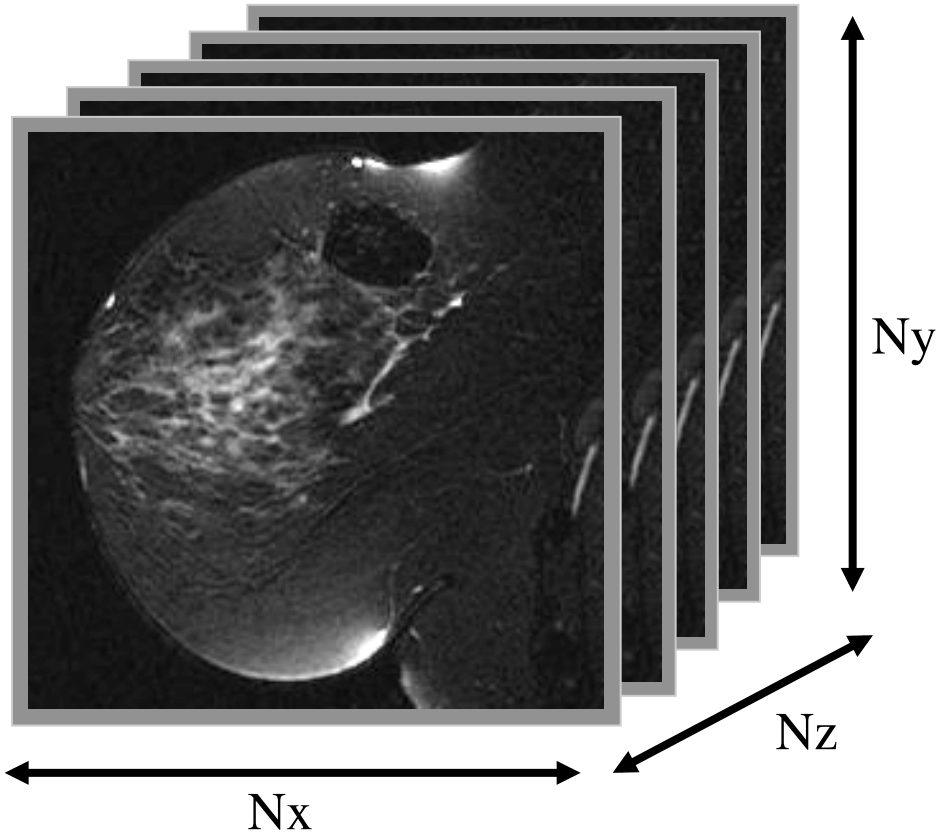

3D T2-weighted MRI

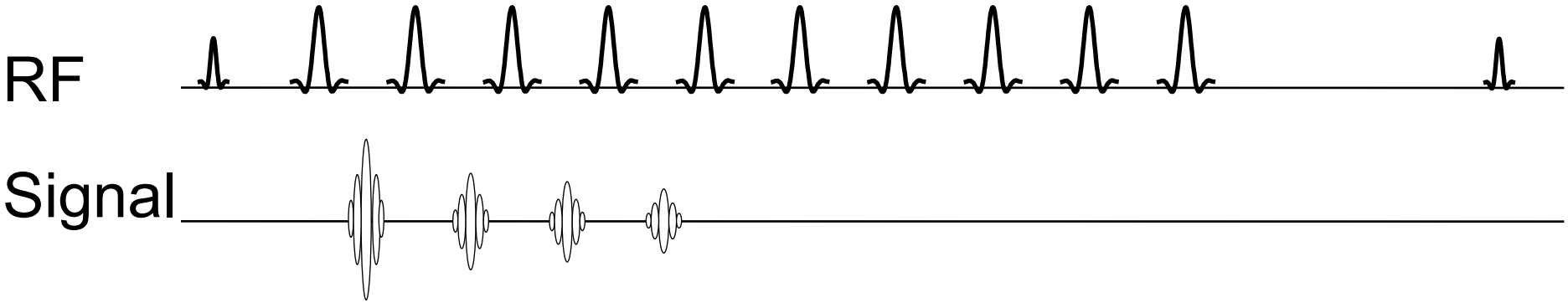

3D T2-weighted MRI

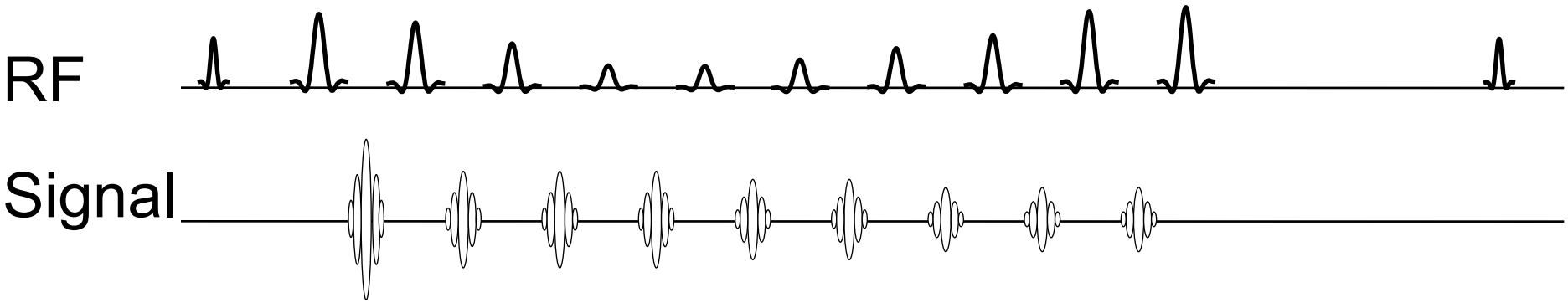

- Variable flip angle, extended echo train T2-weighted

3D T2-weighted MRI

- More efficient scan
- Higher resolution in all planes, reasonable scan times

3D T2-weighted MRI

- More efficient scan

- Higher resolution in all planes, reasonable scan times

3D-FSE-Cube

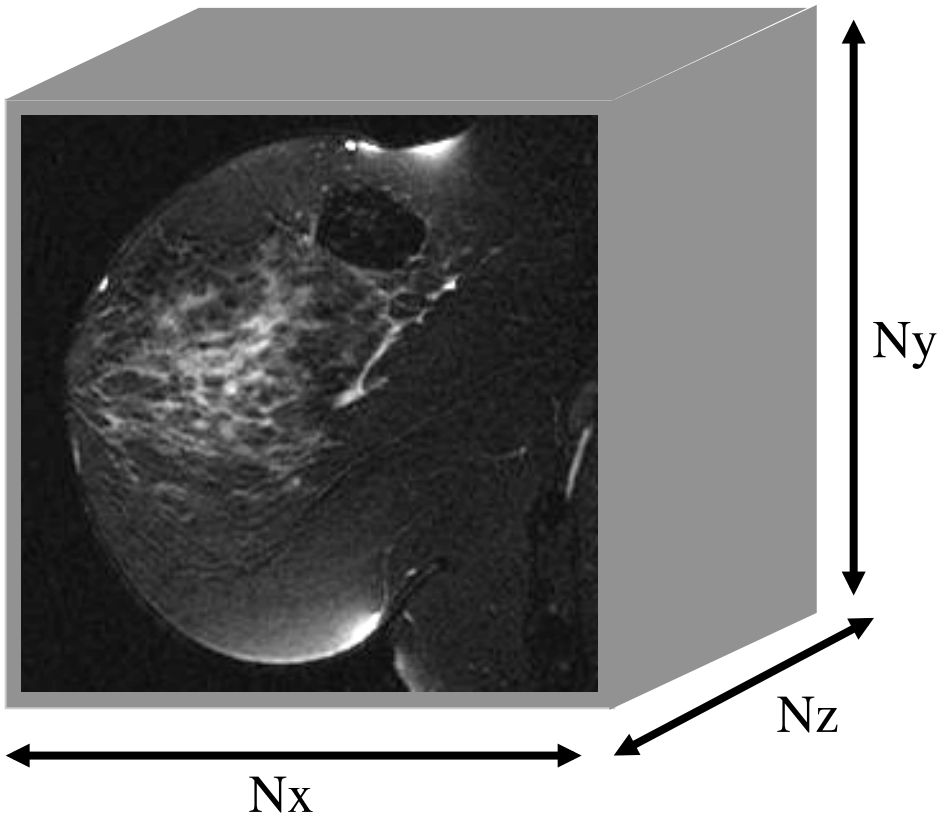

3D T2-weighted MRI

- More efficient scan

- Higher resolution in all planes, reasonable scan times

3D-FSE-Cube

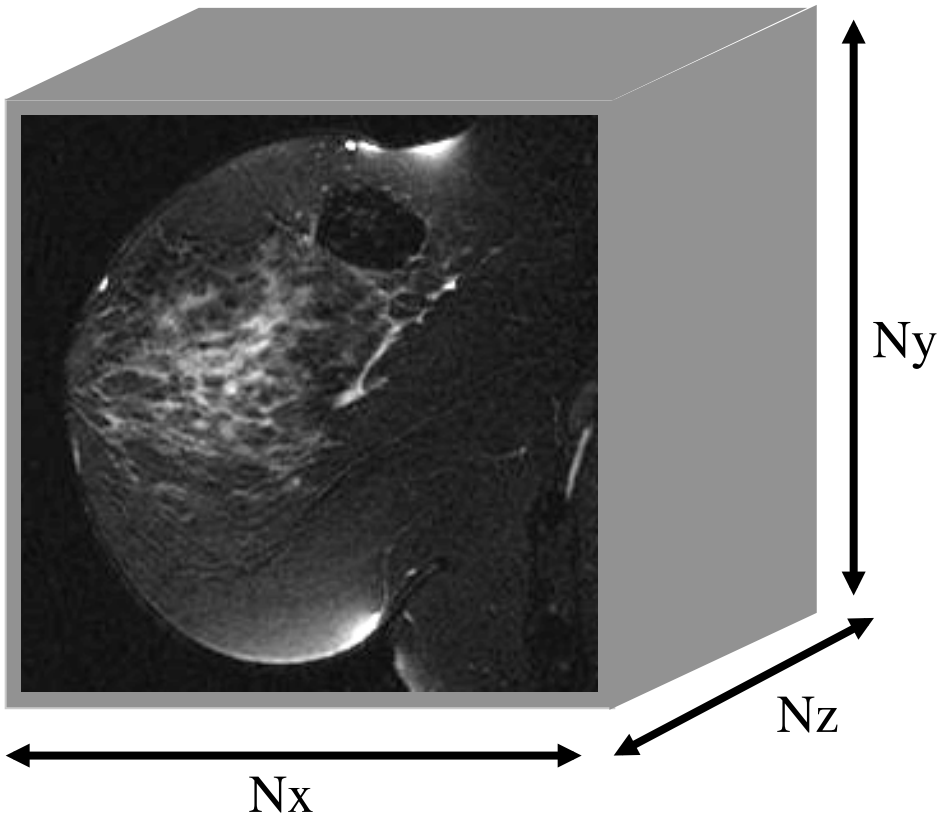

3D T2-weighted MRI: Trade-offs

- T1 signal contamination
- Blurring due to extended echo train
- Tissue dependent

3D-FSE-Cube

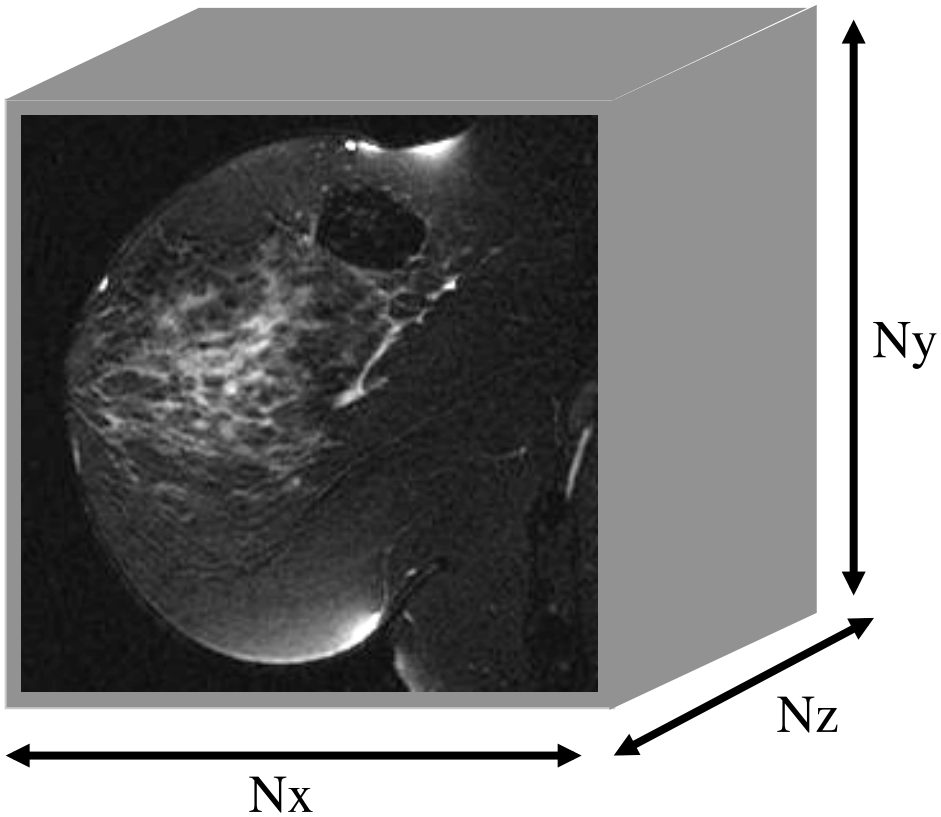

- T2 contrast
- 2D versus 3D T2-weighted MRI
- T2-weighted imaging in breast MRI
- Pilot study in breast MRI

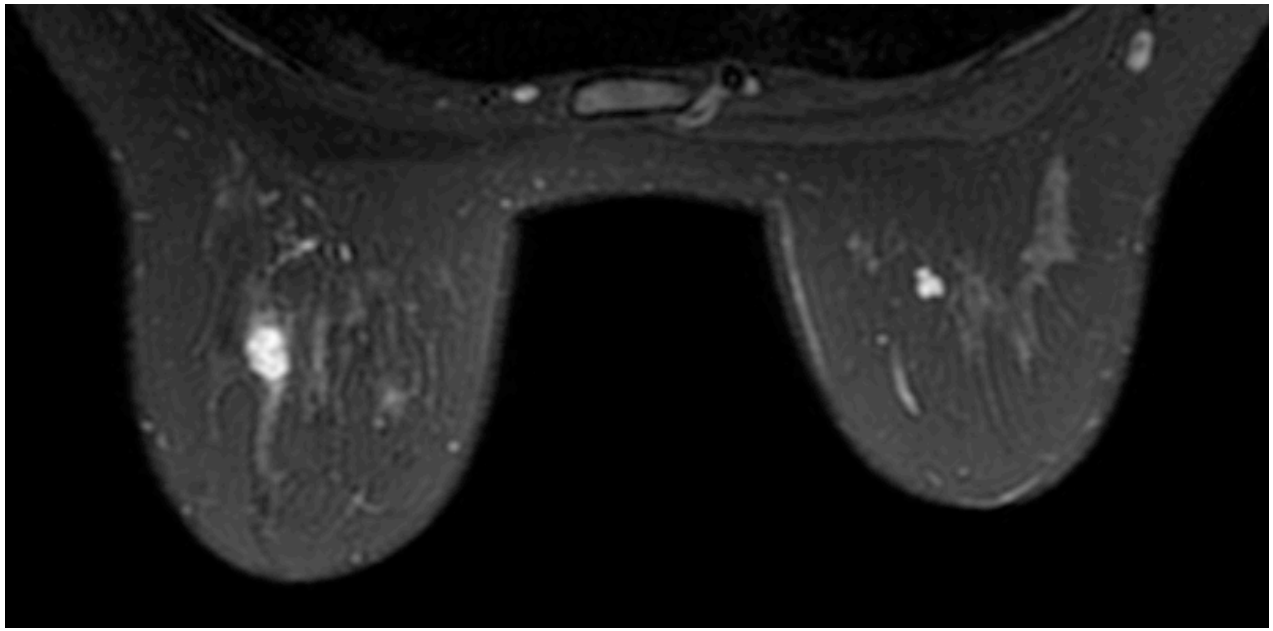

- T2 contrast
- 2D versus 3D T2-weighted MRI
- T2-weighted imaging in breast MRI
- Pilot study in breast MRI

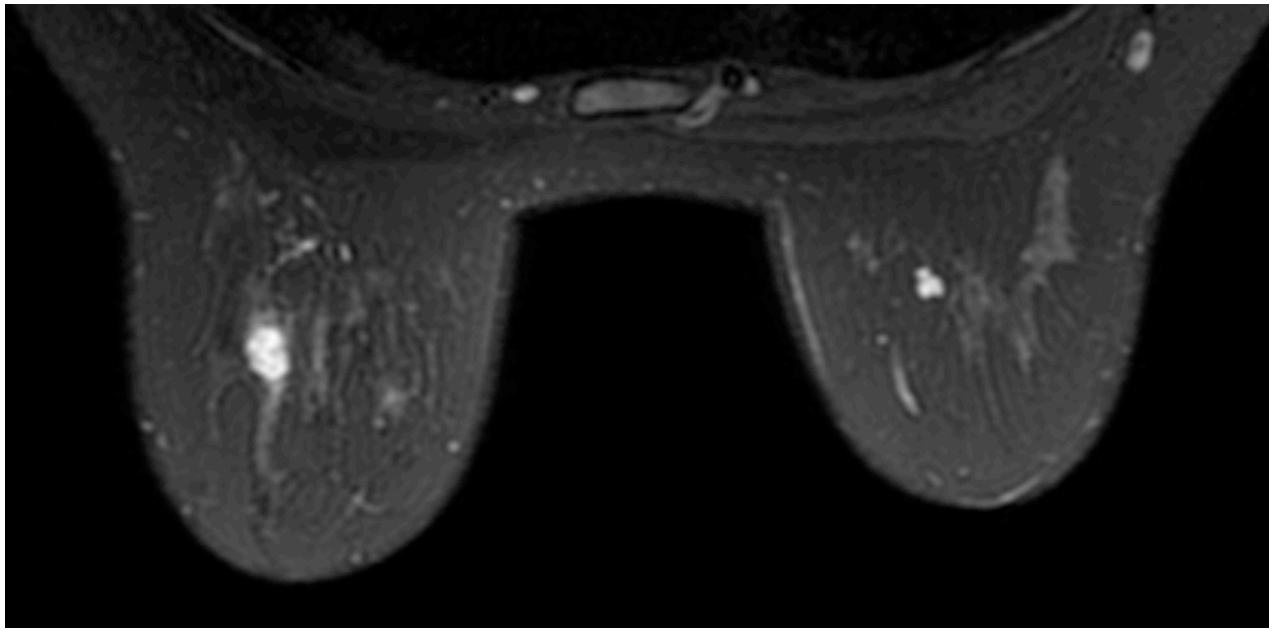

Clinical Breast MRI Protocol

T1-weighted Pre contrast

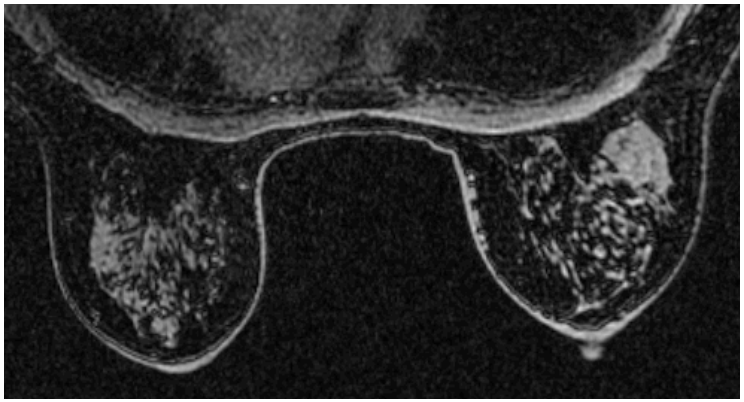

T1-weighted Post contrast

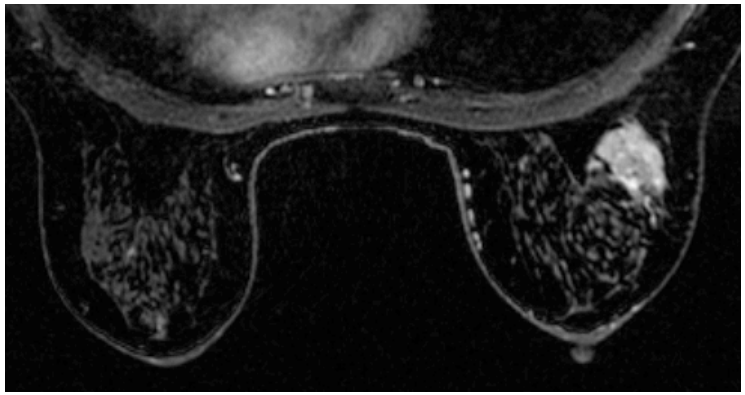

T2-weighted

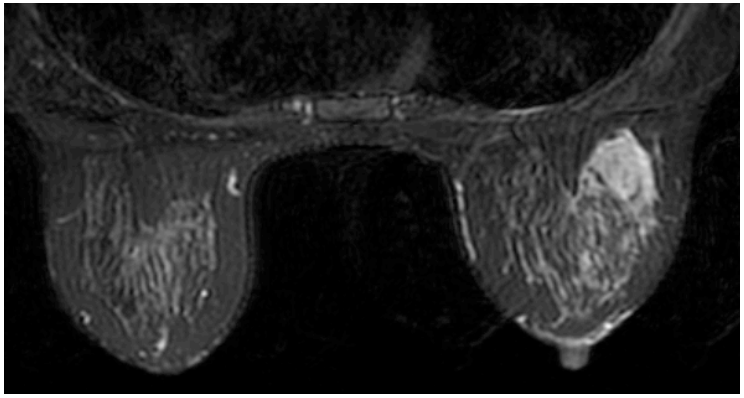

Clinical Breast MRI Protocol

T1-weighted Pre contrast

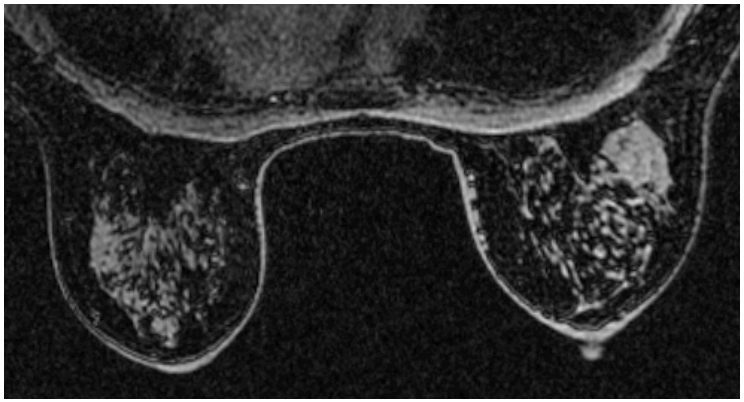

T1-weighted Post contrast

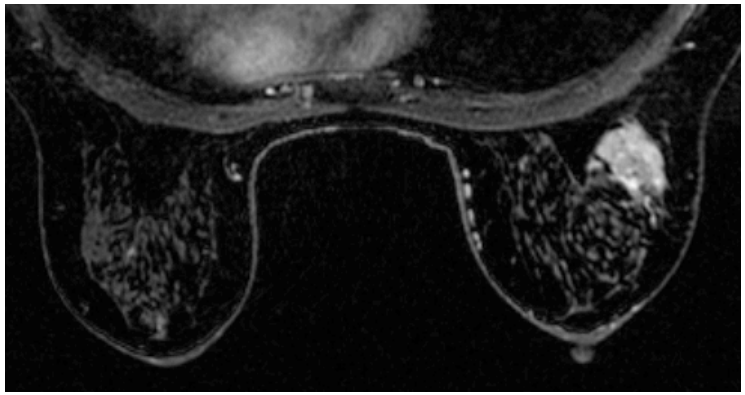

T2-weighted

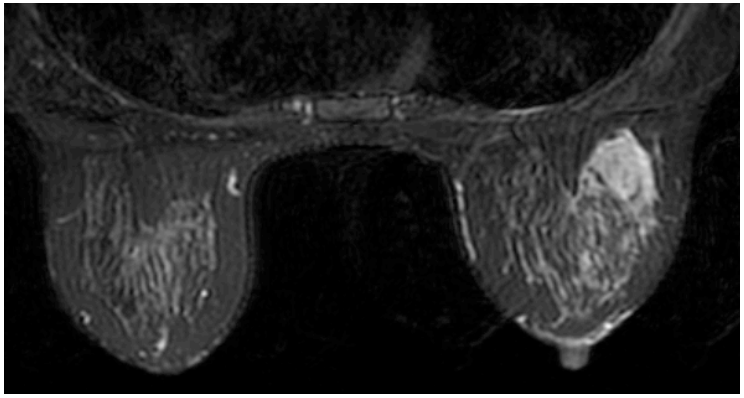

T2-weighted Imaging in Breast MRI

- Identification of cysts
- Lesion characterization (contrast/morphology)
- Alignment with DCE images
- Small lesions

T2-weighted

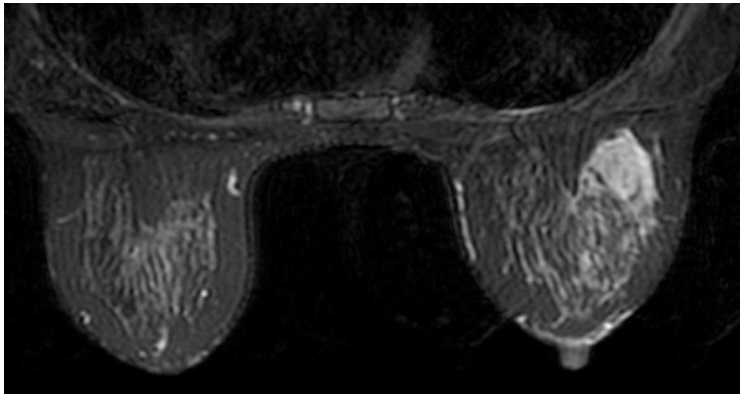

T2-weighted Imaging in Breast MRI

- Recent studies continue to show the potential contribution of T2-weighted Imaging to Breast MRI

ORIGINAL ARTICLE

Nonmass Lesions in Magnetic Resonance Imaging of the Breast: Additional T2-Weighted Images Improve Diagnostic Accuracy

Pascal A.T. Baltzer, MD, Matthias Dietzel, MD, and Werner A. Kaiser, MD, MS

Objective: In magnetic resonance imaging (MRI) of the breast, contrast enhancements present as mass or nonmass (NM) lesions. This study aimed to test the usefulness of currently accepted T1-weighted Breast Imaging Reporting and Data System predictors and to determine the incremental value of new T2-weighted predictors for differentiation of benign from malignant NM lesions.

The BI-RADS lexicon differentiates between space-occupying mass and non–space-occupying nonmass lesions. The advantage of this approach is that different biological tumor growth conditions are taken into account. Furthermore, radiological lesion descriptors applicable on the one group might show limited use in the other, that is, lesion margins. In comparison to mass lesions, the knowledge of nonmass lesions is rather limited. The

T2-weighted Imaging in Breast MRI

- While others point to the lingering questions of T2-weighted Imaging in breast MRI

Eur Radiol (2008) 18: 1307–1318
DOI 10.1007/s00330-008-0863-7

NEWS FROM EUSOBI

R. M. Mann
C. K. Kuhl
K. Kinkel
C. Boetes

Breast MRI: guidelines from the European Society of Breast Imaging

Received: 4 October 2007
Revised: 10 December 2007
Accepted: 1 January 2008
Published online: 4 April 2008

K. Kinkel
Department of Radiology,
Clinique des Grangettes,
7, chemin des Grangettes,
1224 Genève, Switzerland
e-mail: Karen.Kinkel@grangettes.ch

MRI should only be offered by institutions that can also offer a MRI-guided breast biopsy or that are in close contact with a site that can perform this type of biopsy for them. Radiologists involved in breast imaging should ensure that they have a

T2-weighted Imaging in Breast MRI

- While others point to the lingering questions of T2-weighted Imaging in breast MRI

Eur Radiol (2008) 18: 1307–1318
DOI 10.1007/s00330-008-0863-7

NEWS FROM EUSOBI

R. M. Mann
C. K. Kuhl
K. Kinkel
C. Boetes

In the T2-weighted images water-containing lesions or edematous lesions have an intense signal, and in this sequence small cysts and myxoid fibroadenomas are very well identified.

In most cases cancer does not yield a high signal on T2-weighted images; thus, these sequences can be useful in the differentiation between benign and malignant lesions. However, as most of these lesions can also be identified on T1-weighted images, there is no evidence as yet of added value of T2-weighted sequences in breast MRI [14, 15].

Received: 4 Oc
Revised: 10 De
Accepted: 1 Ja
Published onlin

T2-weighted Imaging in Breast MRI

- While others point to the lingering questions of T2-weighted Imaging in breast MRI

Eur Radiol (2008) 18: 1307–1318
DOI 10.1007/s00330-008-0863-7

NEWS FROM EUSOBI

R. M. Mann
C. K. Kuhl
K. Kinkel
C. Boetes

Breast MRI: guidelines from the European Society of Breast Imaging

Received: 4 October 2007
Revised: 10 December 2007
Accepted: 1 January 2008
Published online: 4 April 2008

K. Kinkel
Department of Radiology,
Clinique des Grangettes,
7, chemin des Grangettes,
1224 Genève, Switzerland
e-mail: Karen.Kinkel@grangettes.ch

MRI should only be offered by institutions that can also offer a MRI-guided breast biopsy or that are in close contact with a site that can perform this type of biopsy for them. Radiologists involved in breast imaging should ensure that they have a

- T2 contrast
- 2D versus 3D T2-weighted MRI
- T2-weighted imaging in breast MRI
- Pilot study in breast MRI

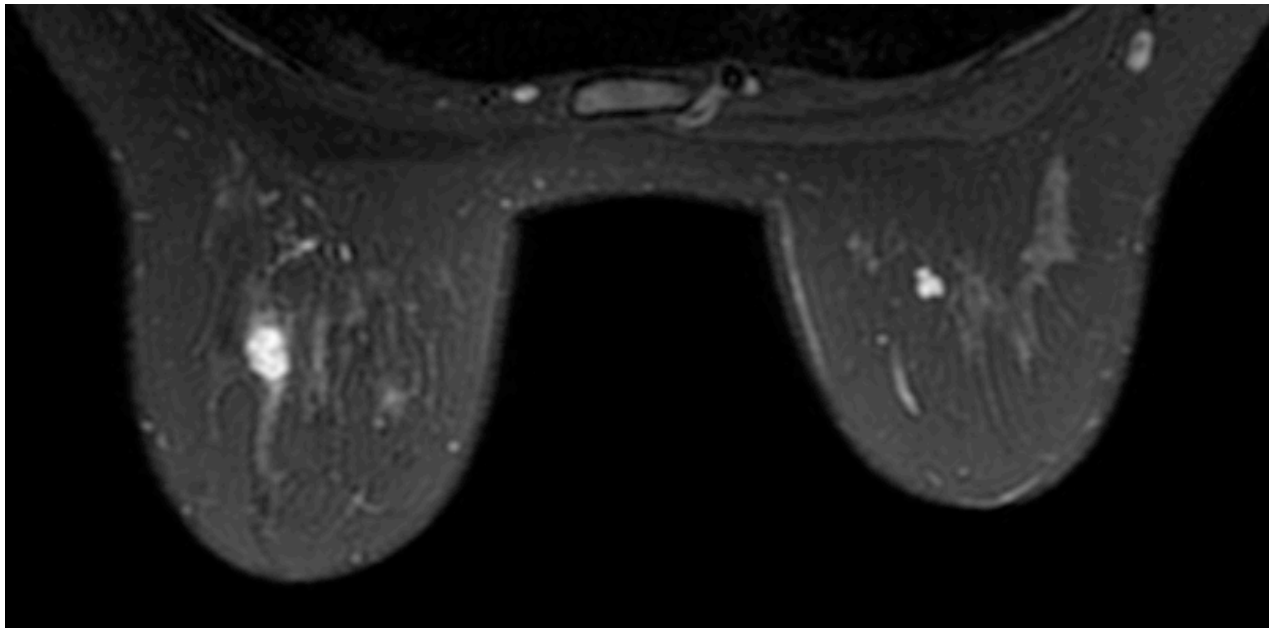

- T2 contrast
- 2D versus 3D T2-weighted MRI
- T2-weighted imaging in breast MRI
- Pilot study in breast MRI

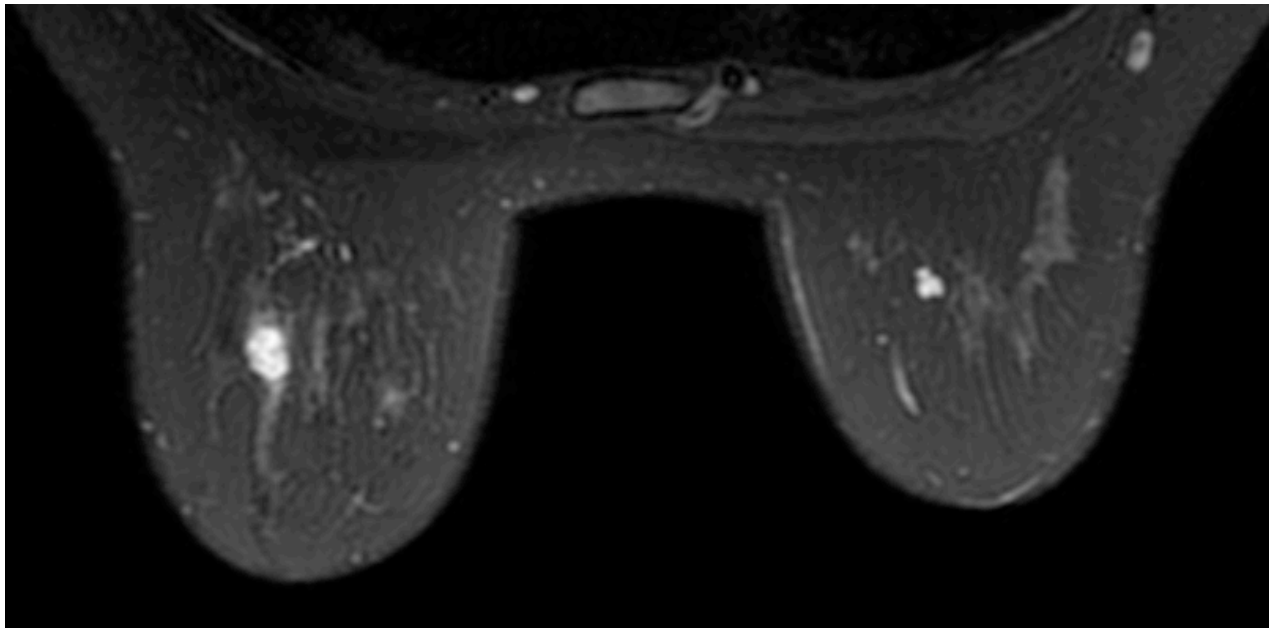

- Routine part of Protocol

- Routine part of Protocol
  - Role remains vague

- Routine part of Protocol
  - Role remains vague
    - Alignment of finding, small lesions

- Routine part of Protocol
  - Role remains vague
    - Alignment of finding, small lesions
      - 3D T2-weighted Imaging

- Routine part of Protocol
  - Role remains vague
    - Alignment of finding, small lesions
      - 3D T2-weighted Imaging
        - Improved resolution

- Routine part of Protocol
  - Role remains vague
    - Alignment of finding, small lesions
      - 3D T2-weighted Imaging
        - Improved resolution
          - Improved T2-weighted data

Evaluation of 3D T2-weighted Imaging In Breast MRI

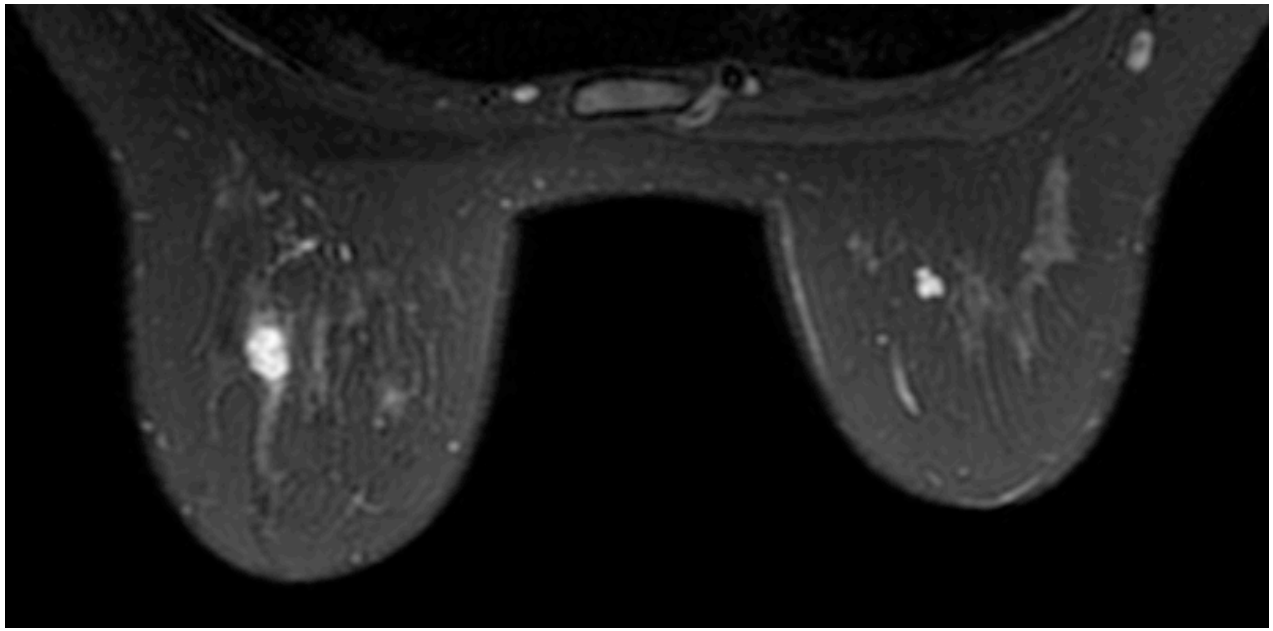

2D vs. 3D T2-weighted Imaging in Breast MRI

Subjects:

- 25 patients
- Clinically indicated breast MRI
- 2D-FSE and 3D-FSE-Cube
- 3D-FSE-Cube added on to clinical protocol
- Informed consent

2D vs. 3D T2-weighted Imaging in Breast MRI

Scans:

- 3T (GE Discovery MR 750)
- 8-channel GE HD Breast Coil
- Axial plane

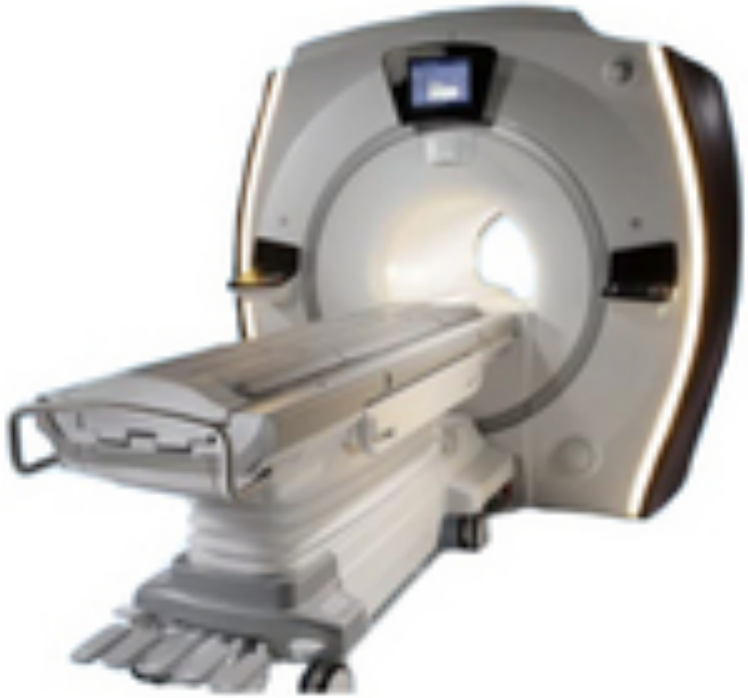

2D vs. 3D T2-weighted Imaging in Breast MRI

Imaging parameters:

	2D-FSE	**3D-FSE-Cube**
Resolution	1.25 mm x 1.0 mm	1.25 mm x 1.0 mm
Slice Thickness	4 mm	2 mm
ETL	16	64
Scan time	6 min	4 min

2D vs. 3D T2-weighted Imaging in Breast MRI

Imaging parameters:

	2D-FSE	**3D-FSE-Cube**
Resolution	1.25 mm x 1.0 mm	1.25 mm x 1.0 mm
Slice Thickness	4 mm	2 mm
ETL	16	64
Scan time	6 min	4 min

In 2/3 scan time 3D-FSE-Cube provided 50% reduction in voxel size

Analysis

- Identification of lesions
- Pathology
- Stability from prior imaging studies

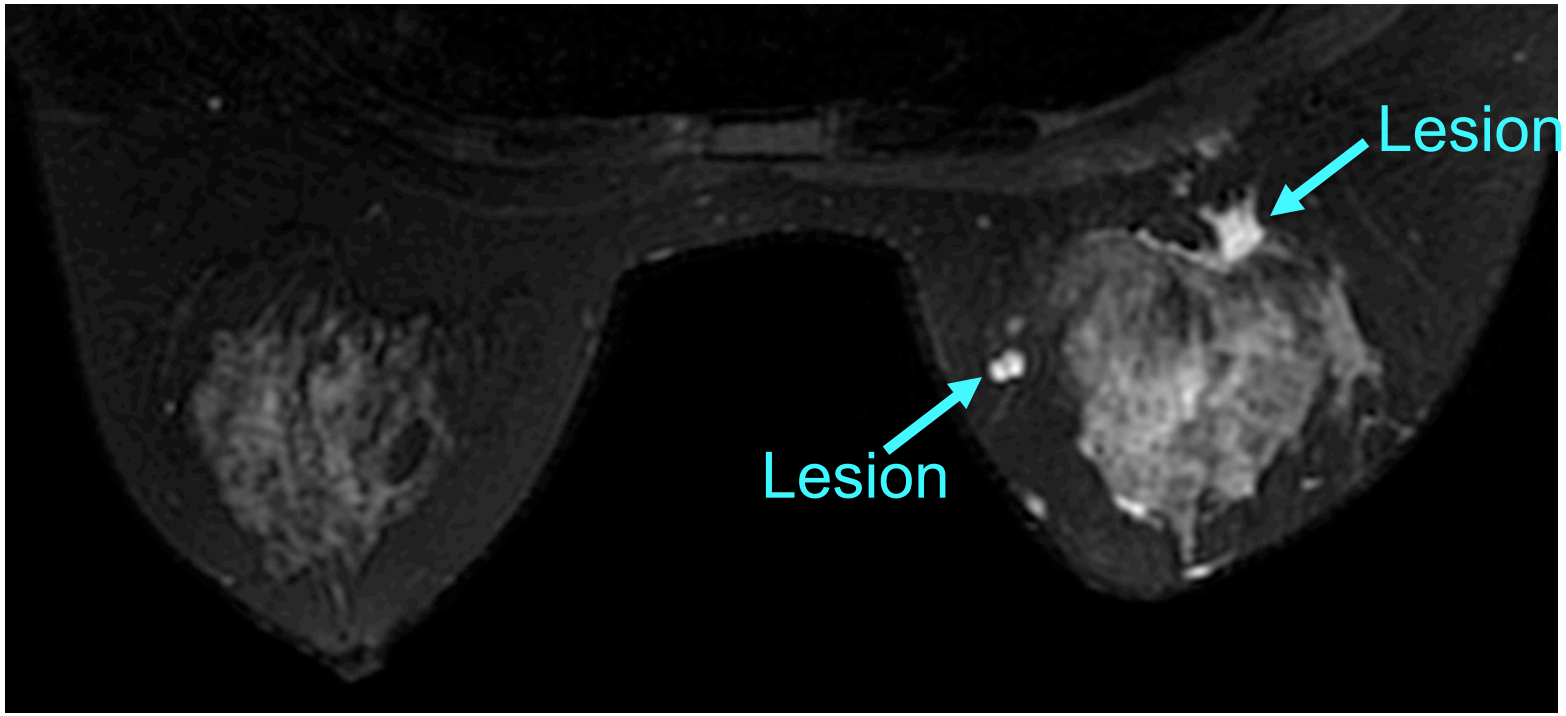

Analysis

- Contrast
- Lesion morphology
- Diagnostic significance

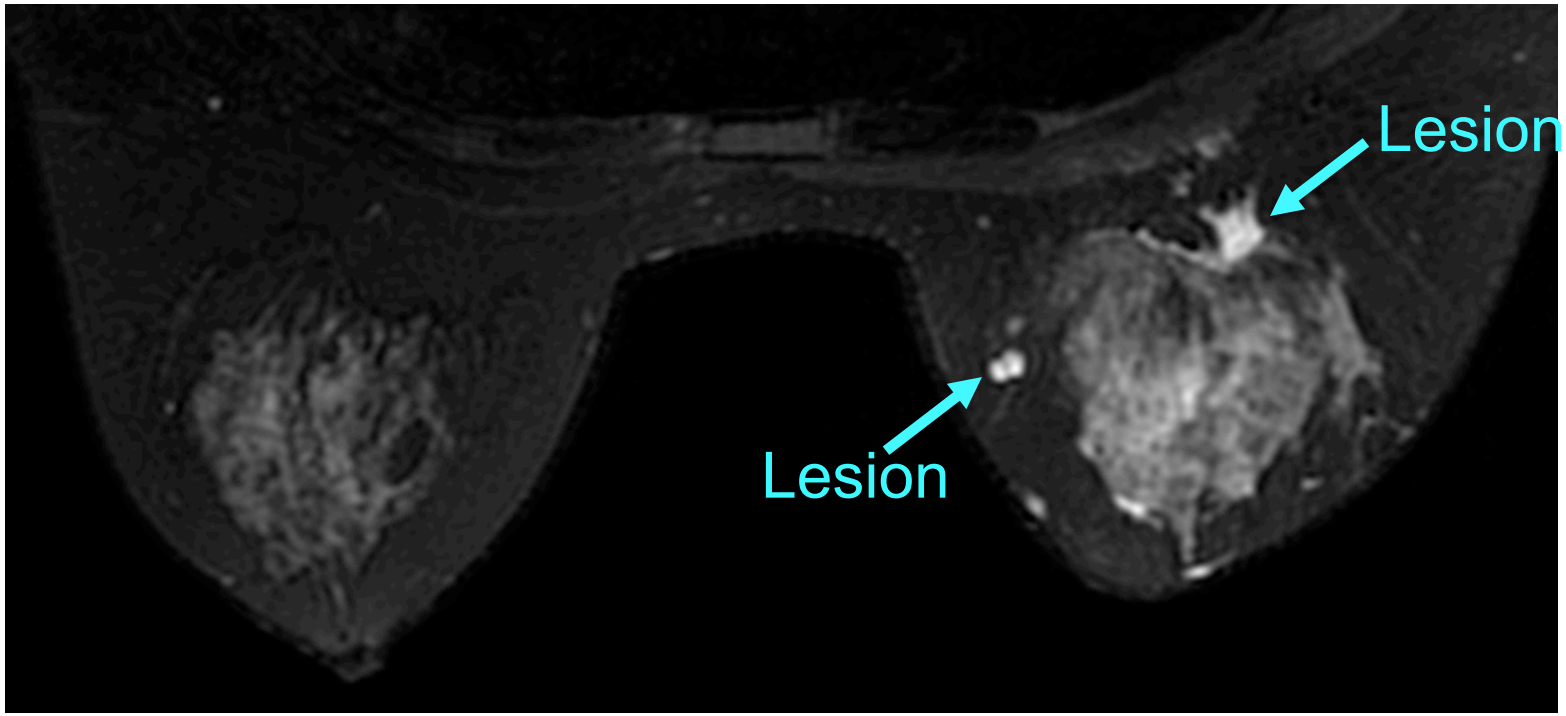

Analysis: Contrast

- Lesion-to-fibroglandular tissue signal ratio (S_L/S_F)
- Lesion signal intensity (S_L)
- Fibroglandular signal intensity (S_F)

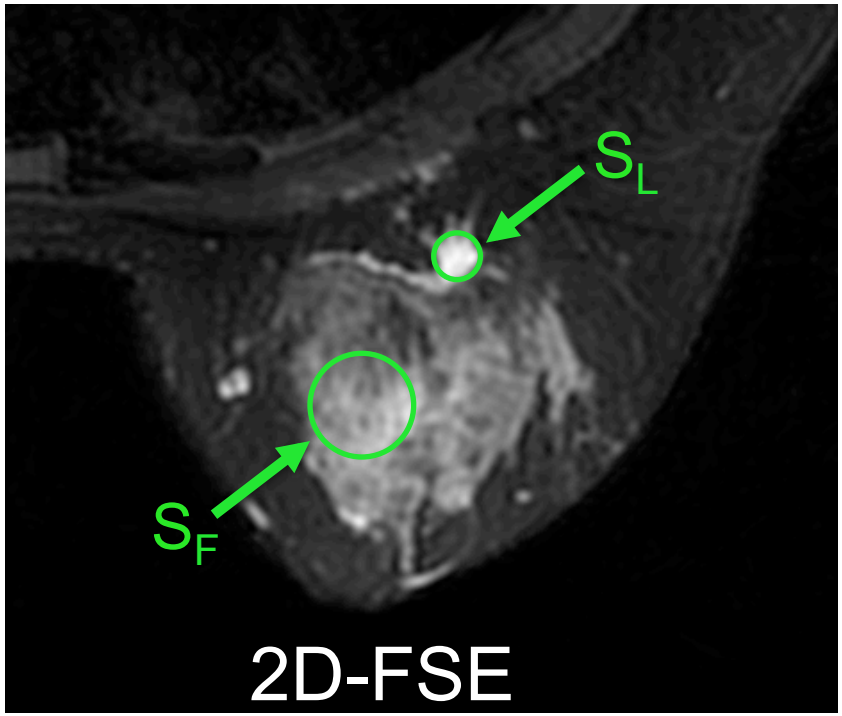

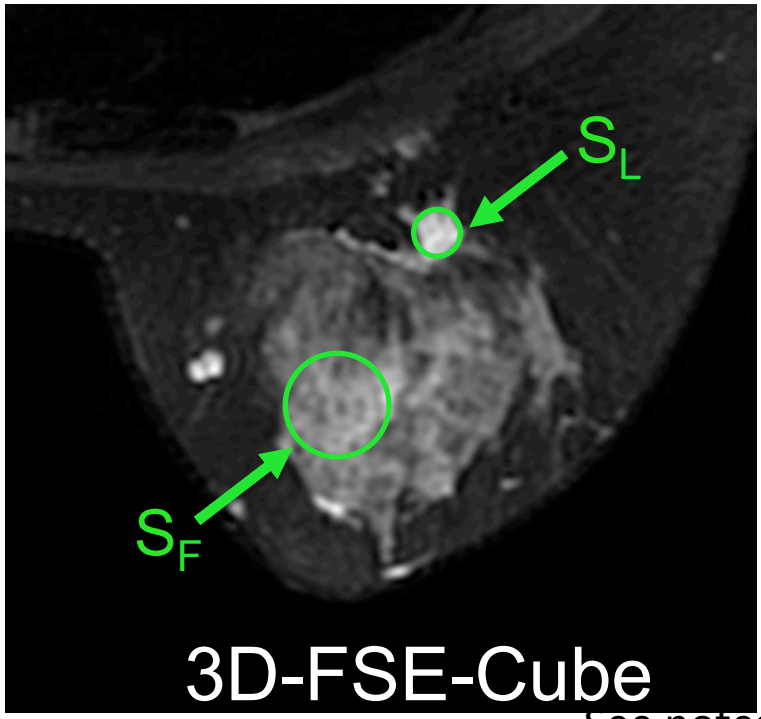

See notes page

Analysis: Lesion Morphology

- Blinded paired review
- Three radiologists with breast imaging expertise
- Only lesion with high T2-signal
- Lesion magnified and indicated with an arrow

Analysis: Lesion Morphology

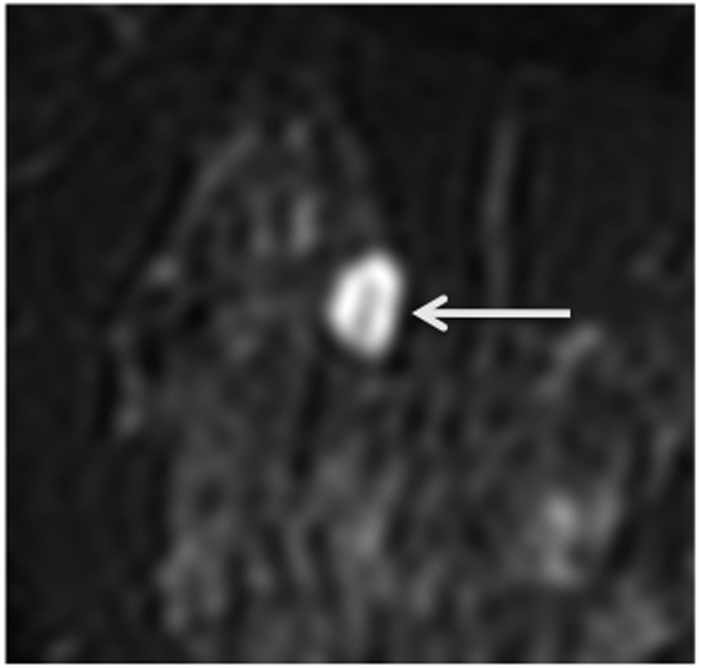

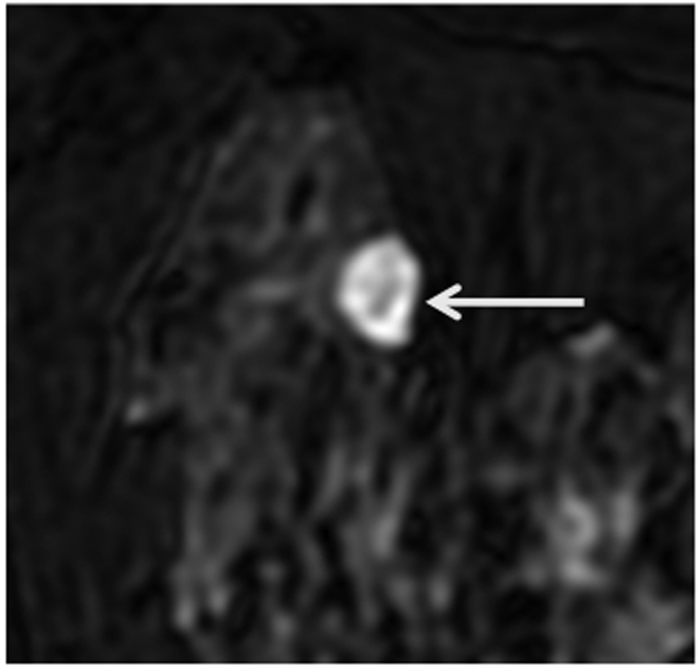

- Clearer depiction of morphology
- Or if depiction of morphology was equivalent
- Statistical significance

Analysis: Diagnostic Significance

- Fourth radiologist with breast MRI expertise
- Unblinded review
- Instances where 3D-FSE-Cube affected diagnostic information were noted
- Images analyzed in acquisition plane as well as in reformatted sagittal and coronal orientations

Results

- 17 lesions identified
- 7 malignant and 10 benign
    - 7 invasive ductal carcinomas
    - 5 fibroadenomas
    - 3 cysts
    - 1 papilloma
    - 1 cyst/hematoma

2D FSE vs. 3D-FSE-Cube Lesion-to-Fibroglandular Tissue Contrast (S_L/S_F)

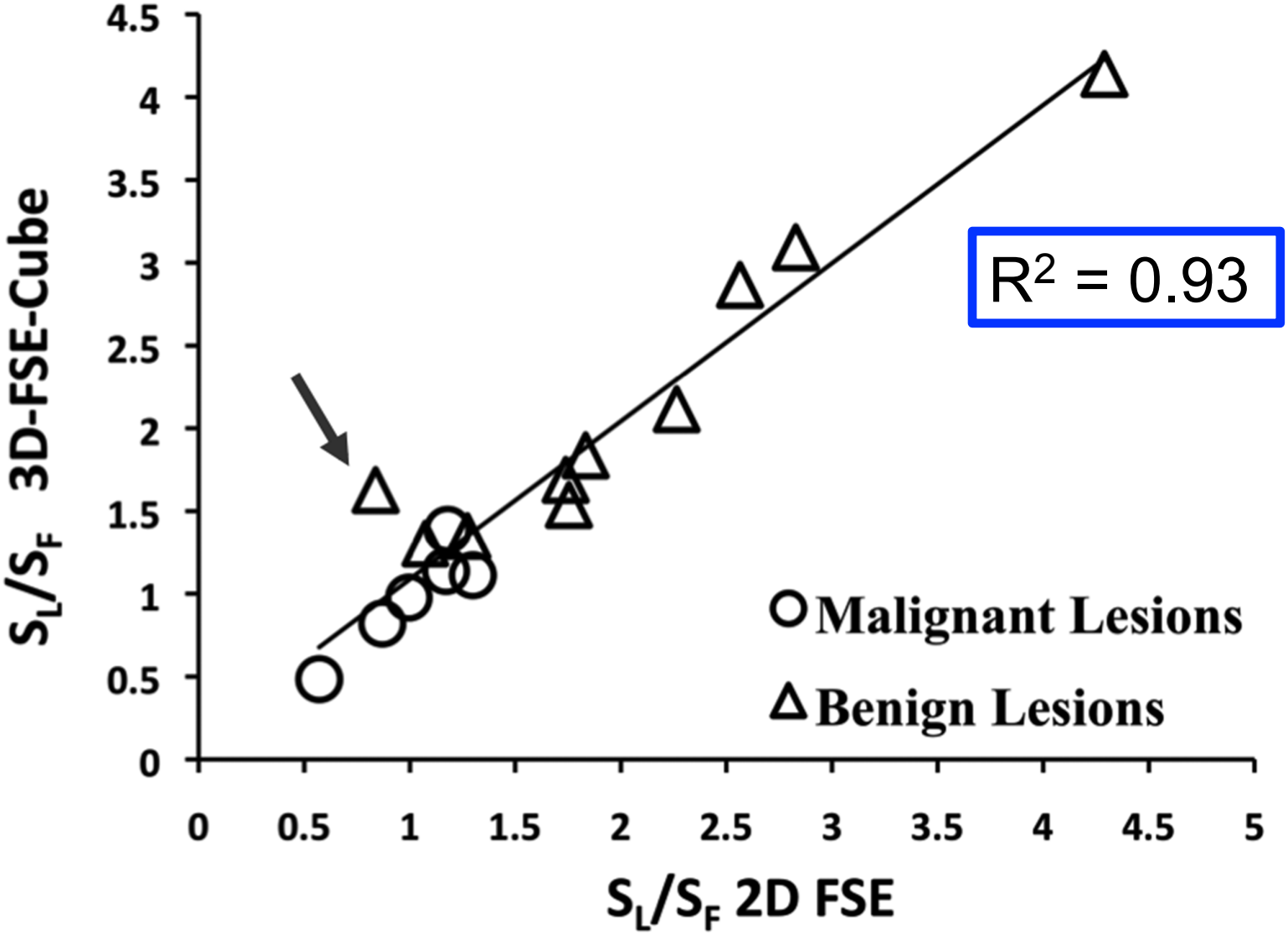

Equivalent Contrast

Contrast-Enhanced T1-weighted

2D-FSE

3D-FSE-Cube

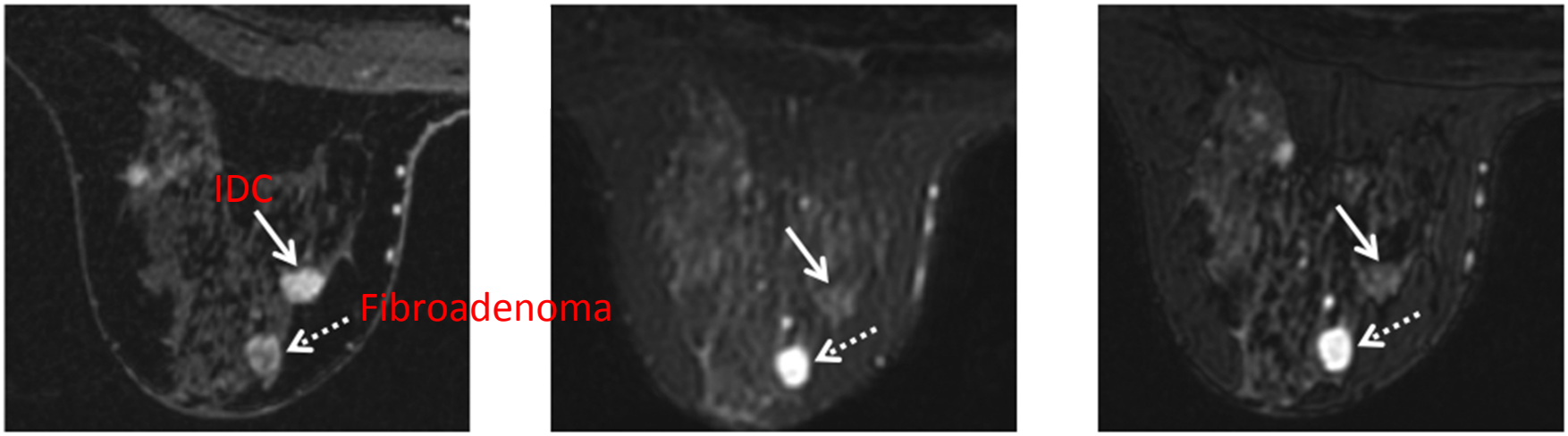

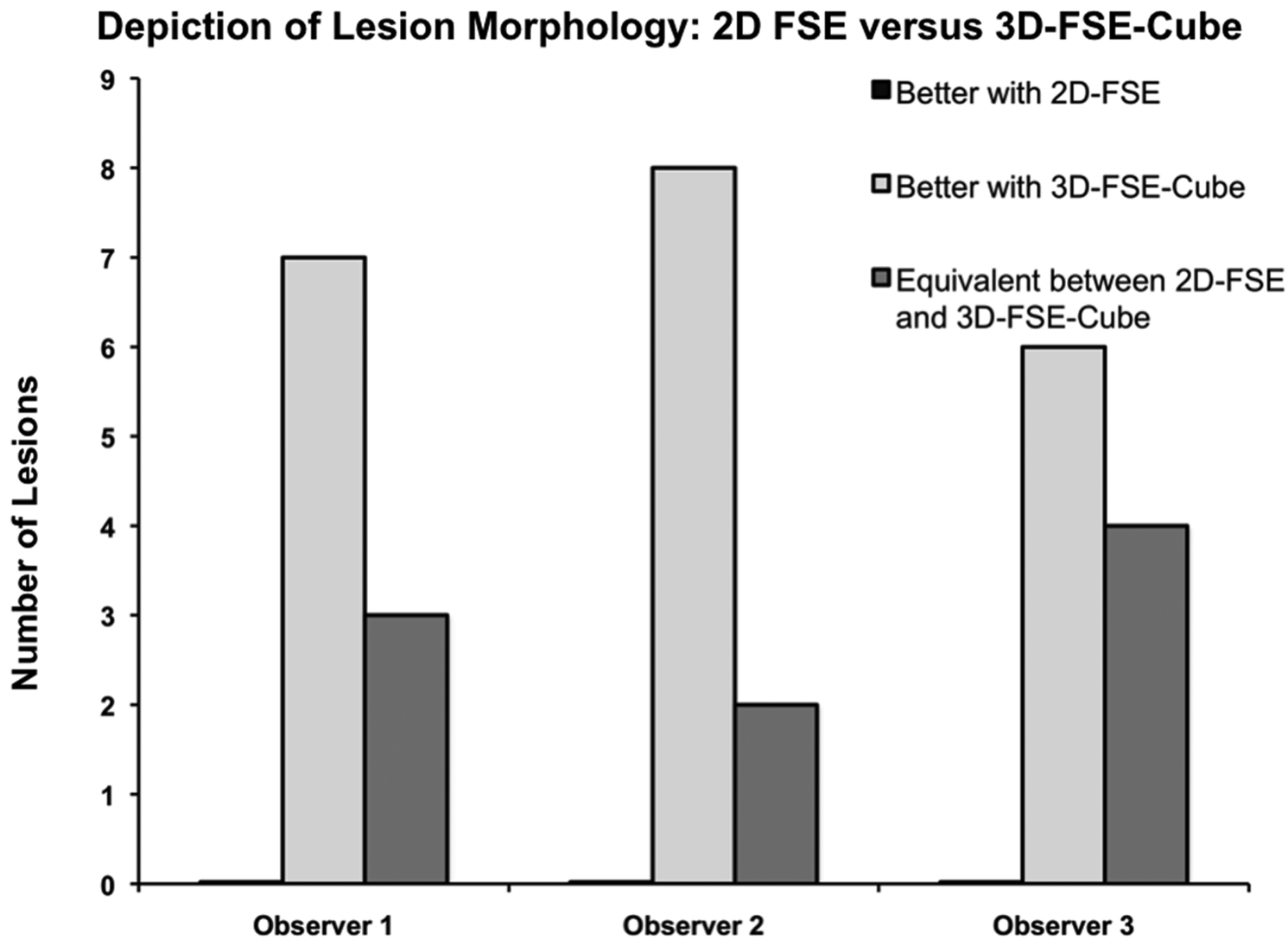

Statistically significant: $p \leq 0.02$, $p \leq 0.01$, $p \leq 0.03$

Depiction of Lesion Morphology

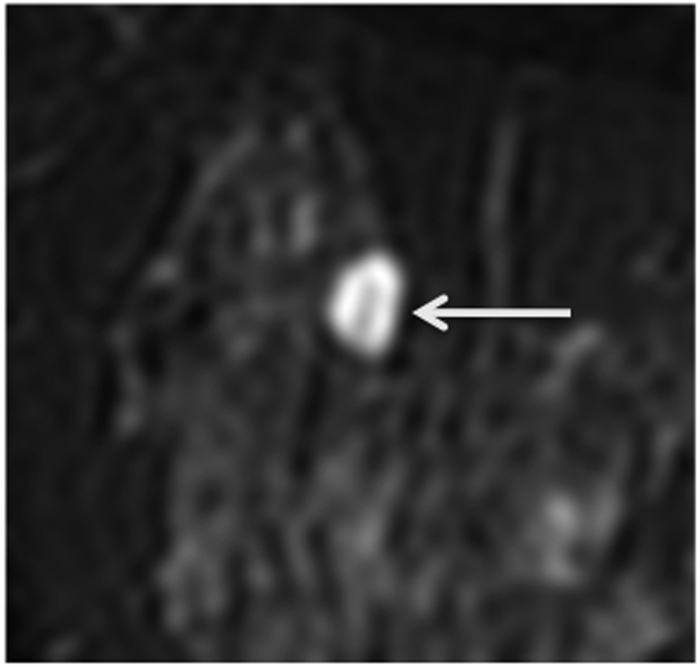

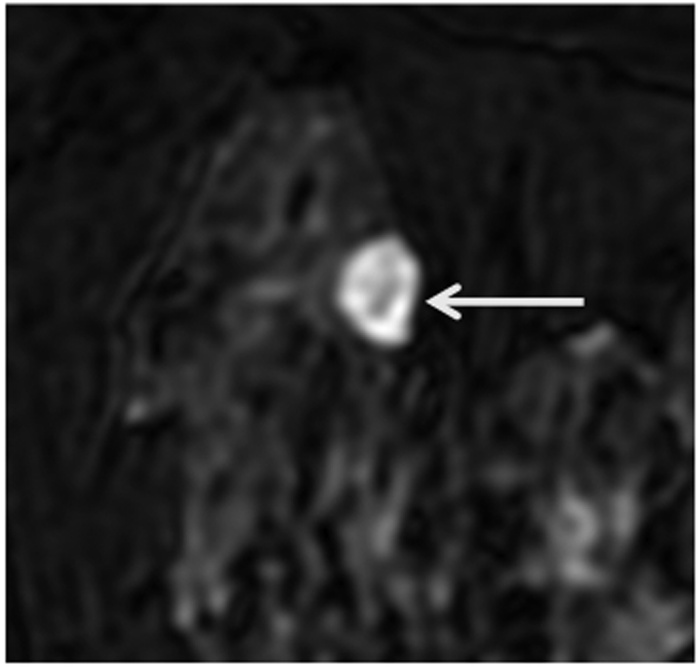

Depiction of Lesion Morphology

2D-FSE

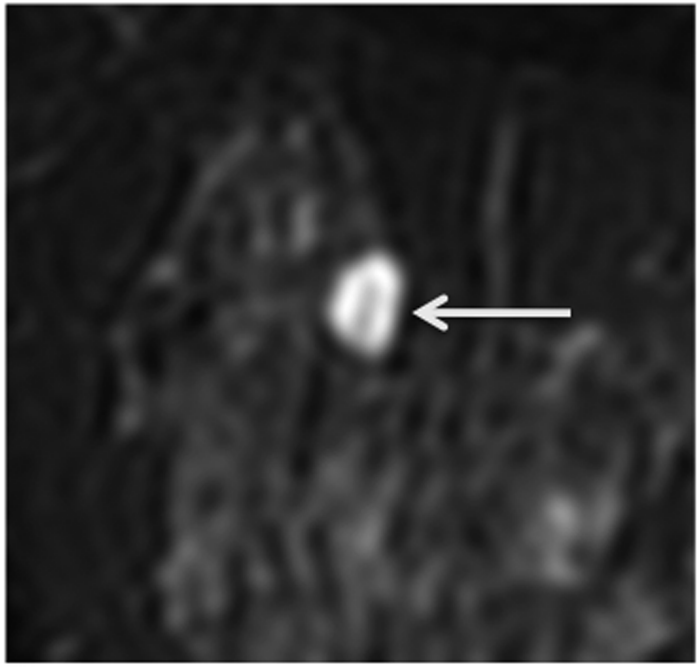

3D-FSE-Cube

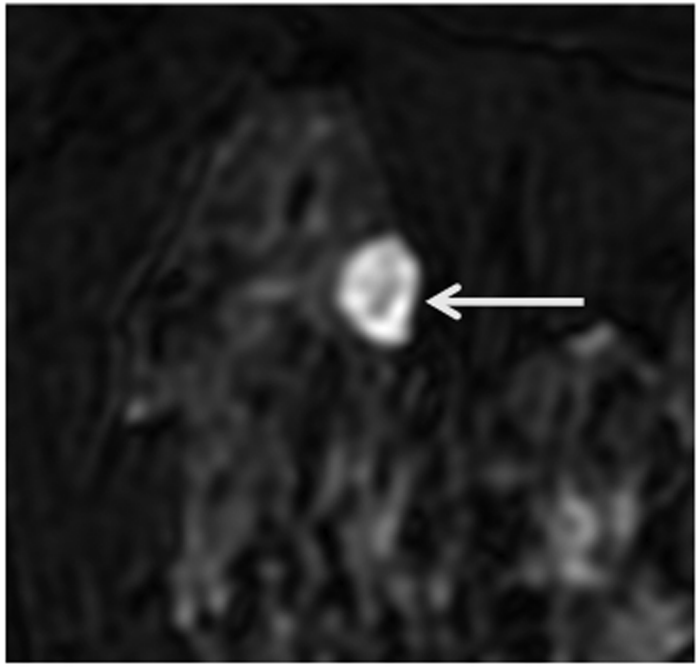

✓ ✓ ✓

Depiction of Lesion Morphology

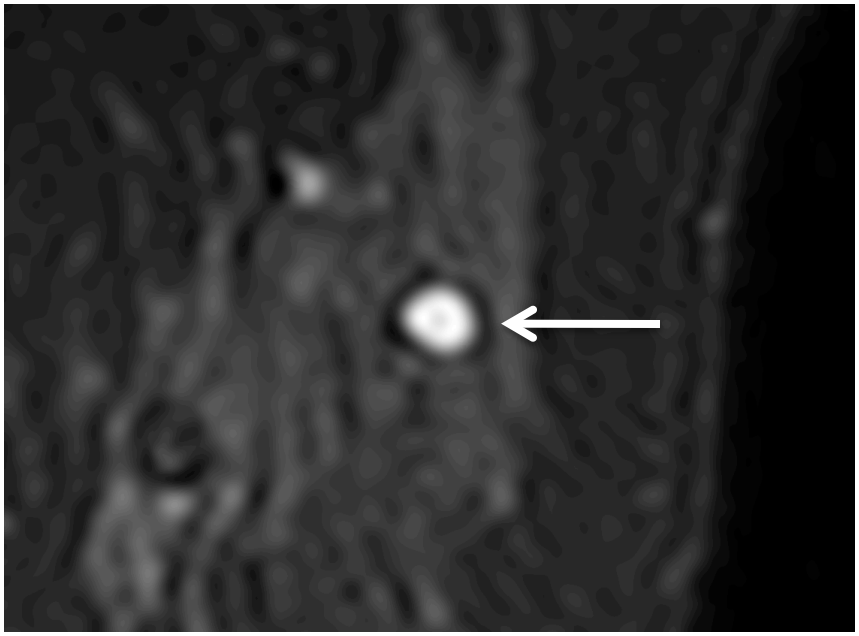

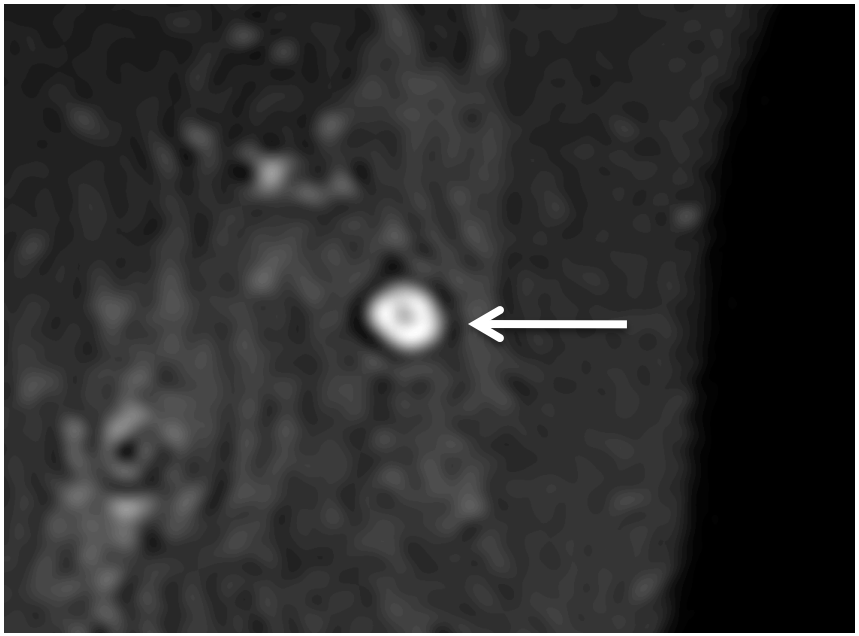

Depiction of Lesion Morphology

2D-FSE

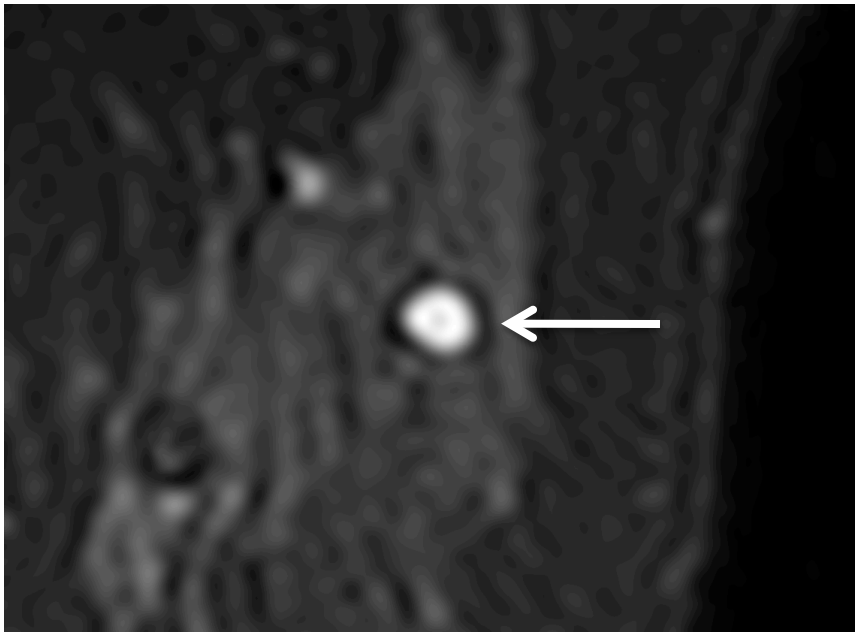

3D-FSE-Cube

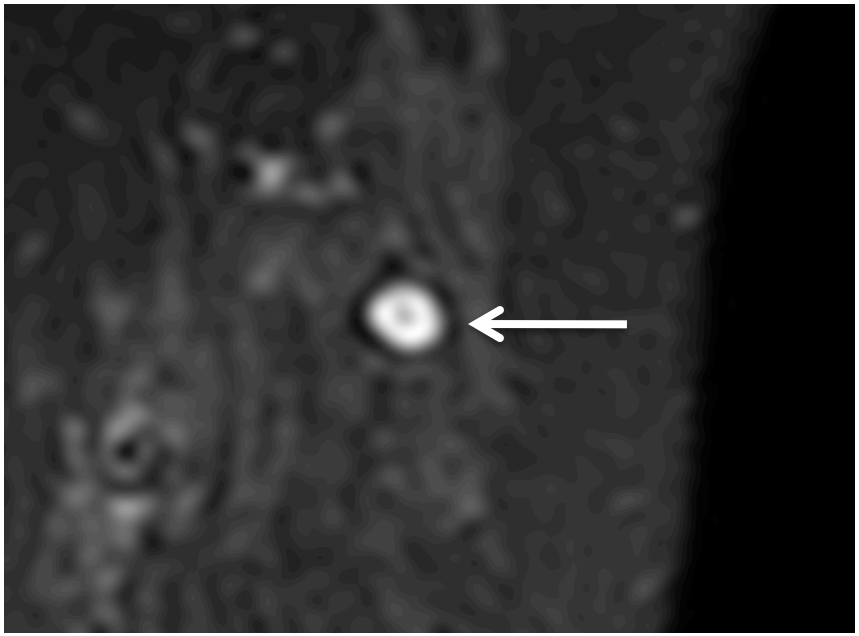

=

=

Potential Diagnostic Contribution

Contrast-Enhanced
T1-weighted

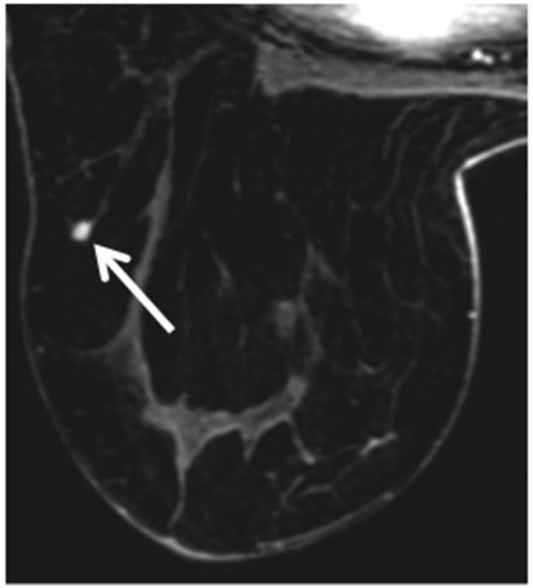

2D-FSE

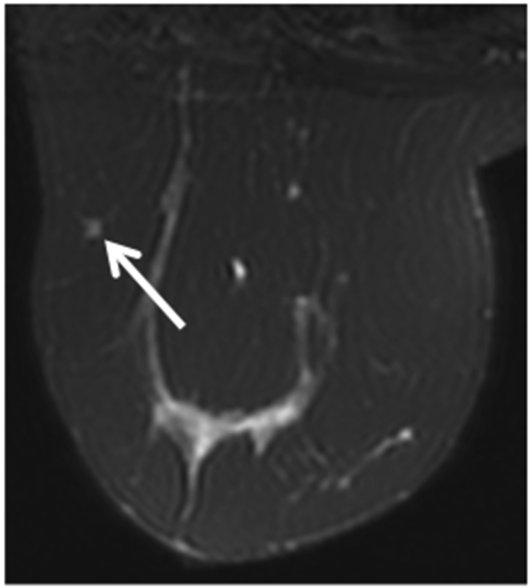

3D-FSE-Cube

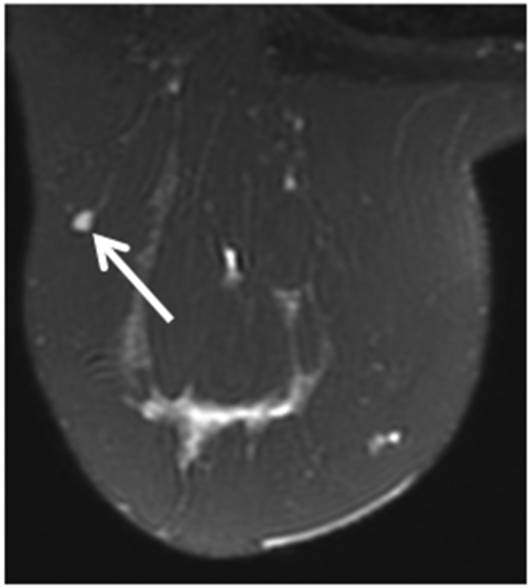

Conclusions

- Comparable contrast
- Improves the depiction of lesion morphology
- Contribution to differential diagnosis

Clinical Utilization, Future Work

- 3D-FSE-Cube now routine in breast MRI at Stanford
- Alignment of findings
- Larger database of patients
- Focus on specific T2-features of breast lesions

Acknowledgements

Brian Hargreaves

Bruce Daniel

Jafi Lipson

Deb Ikeda

Jennifer Kao

Anne Sawyer

Kevin Epperson

Volunteers