Decreased Synovial Inflammation in Atraumatic Hip Microinstability Compared With Femoroacetabular Impingement

Geoffrey D. Abrams, M.D., Ayala Luria, Ph.D., Joshua Sampson, M.D., Rachel A. Madding, B.S., William H. Robinson, M.D., Marc R. Safran, M.D., and Jeremy Sokolove, M.D.

Purpose: To compare the inflammatory profile of hip synovial tissue in those with atraumatic microinstability to patients with femoroacetabular impingement (FAI). **Methods:** Patients with cam and mixed-type FAI (FAI group) and patients with hip instability underwent sampling of the anterolateral synovium. Demographic data, intraoperative measurements, and functional outcome scores (International Hip Outcomes Tool and Short Form-12) were recorded. Cryosections were stained and examined under light microscopy as well as confocal fluorescent microscopy for anti-CD45 (common leukocyte antigen), anti-CD31 (endothelial), and anti-CD68 (macrophage) cell surface markers. A grading system was used to quantify synovitis under light microscopy whereas digital image analysis was used to quantify immunofluorescence staining area. Comparison were made with Student t test, Mann-Whitney U, χ^2, and regression analysis. **Results:** There were 12 patients in the FAI group and 5 in the instability group. Mean age was not significantly different ($P > .05$), but there was a significantly greater proportion of females in the instability group versus the FAI group ($P < .001$). There was a significant correlation ($r = 0.653$; $P = .005$) between number of turns needed for 10 mm of distraction and increased synovitis. Synovitis scores also were increased significantly in patients with cam morphology and articular cartilage damage ($P = .024$) versus those without. Immunohistochemistry did not reveal differences ($P > .082$) between the instability and FAI groups, but CD68 staining was significantly greater in those with cam morphology and cartilage damage ($P < .045$). CD45+/CD68− cells were noted in the perivascular area while CD45+/CD68+ cells were noted within the synovial lining in both groups. **Conclusions:** Increased synovial inflammation was associated with an increased number of turns to achieve joint distraction. Both instability and FAI groups demonstrated baseline levels of synovial inflammation. Synovitis scores also were increased in patients with cartilage damage. **Clinical Relevance:** An understanding of the molecular and cellular mechanisms behind both hip instability and FAI may lead to novel therapeutic anti-inflammatory therapy, which may serve as an adjunct to treatment of mechanical abnormalities in this conditions.

Atraumatic hip microinstability is a poorly understood clinical entity that is emerging as a common cause of hip pain and dysfunction in the younger and more active patient population.[1-7] Because a diagnosis of instability requires perceived pain, the condition is defined as extraphysiologic hip motion associated with pain. The pathoanatomy behind the disorder is thought to be related to subtle underlying anatomic abnormalities (whether osseous or soft tissue) or ligamentous laxity and associated periarticular muscular weakness in the setting of repetitive hip joint loading and rotation.[7] These factors can result in excessive motion of the femoral head on the acetabulum, leading to damage to the labrum and articular cartilage.[1] Some groups have reported that this excessive motion can include not only rotation of the femoral head but also translation within the acetabulum.[2,8] In contrast, femoroacetabular impingement (FAI) results from an aspherical femoral head−neck junction with or without acetabular rim over coverage.[9] This may lead to mechanical abutment of the femur on the acetabulum and subsequent

From the Department of Orthopedic Surgery (G.D.A., M.R.S.) and Rheumatology Division, Department of Medicine (W.H.R., J.So.), Stanford University, Palo Alto, California; and Veterans Administration Palo Alto (G.D.A., A.L., J.Sa., R.A.M., W.H.R., J.So.), Palo Alto, California, U.S.A.

The authors report that they have no conflicts of interest in the authorship and publication of this article.

This study was presented at the International Society for Hip Arthroscopy, September 23-26, 2015, Cambridge, United Kingdom.

Received March 9, 2016; accepted September 12, 2016.

Address correspondence to Geoffrey D. Abrams, M.D., 450 Broadway St., MC 6342, Redwood City, CA 94063, U.S.A. E-mail: gabrams@stanford.edu

Published by Elsevier on behalf of the Arthroscopy Association of North America

0749-8063/16195/$36.00

http://dx.doi.org/10.1016/j.arthro.2016.09.007

damage to intra-articular structures within physiologic ranges of motion.

Abnormalities leading to excessive motion of the femoral head on the acetabulum can lead to joint damage either through mechanical wear or by stimulation of an inflammatory response through the innate immune system.[10,11] In the past, degenerative conditions of joints, such as osteoarthritis, have been considered noninflammatory diseases.[12] Inflammation, however, has been identified within disorders previously considered "noninflammatory," including osteoarthritis,[10,13] rotator cuff pathology,[14,15] as well as FAI.[16] The synovium plays an important role in this process because a variety of immune system cells localize to the synovium during joint injury[17] and therefore likely play a role in the development and perpetuation of the inflammatory state.

The molecular pathology underlying hip instability is not understood. The purpose of this study was to compare the inflammatory profile of hip synovial tissue in those with atraumatic microinstability with patients with FAI. We hypothesized that patients with atraumatic microinstability would demonstrate less synovial inflammation versus those with FAI.

Methods

All patients provided informed consent for tissue biopsy and functional outcome assessment under an institutional review board–approved protocol (Protocol 30479 approved by Stanford University institutional review board). Inclusion criteria was hip pain without radiographic evidence of osteoarthritis (Tönnis grade 0-1) as well as a self-reported pain decrease of at least 50% with a diagnostic injection with 0.5% ropivacaine without corticosteroid given under fluoroscopic guidance by a musculoskeletal radiologist. Exclusion criteria were previous surgery on the hip, lateral center edge angle of Wiberg less than 20°,[18] known inflammatory arthritis, use of anti-inflammatory medication within 1 week of surgery, current use or history of immunosuppressive medication, and Tönnis grade 2 or greater osteoarthritis of the hip. Patients were diagnosed with cam, pincer, or mixed-type impingement based on clinical examination and imaging studies as previously described by Ganz et al.[9] A preoperative diagnosis of hip instability is based on supine hyperexternal rotation (increased external rotation in the supine position vs the contralateral limb), a positive hyperextension-external rotation test defined as the presence of pain, a Beighton score of 6 or greater,[19] as well as a lack of significant cam (alpha angle <50° in all cases) or pincer abnormalities (lateral center edge angle of Wiberg <34° in all cases) on plain radiographs. Because there is no definitive preoperative test to confirm atraumatic instability, intraoperative distraction was used to confirm the preoperative diagnosis of instability based on a previously published methodology.[4]

Preoperative data recorded included age, sex, center edge angle of Wiberg, and alpha-angle (Centricity Picture Archiving and Communications System; GE Health Care, Little Chalfont, United Kingdom) as well as the International Hip Outcomes Tool – Short Version[20] and Short Form–12. Intraoperative data recorded included the presence of a labral tear, cartilage status (as determined by the Outerbridge classification system as well as the need for microfracture), and surgical procedures performed, including labral repair, cheilectomy, acetabuloplasty, and microfracture.

After induction of anesthesia, gross traction was applied to the limb to remove slack and then the number of turns of the traction table (YUNO OTN table; Maquet GmbH, Rastatt, Germany) to achieve 10 mm of joint distraction was recorded. Lower extremity positioning and distraction was performed by the same individual in all cases. After proper pelvis positioning against a centralized perineal post and abduction of the nonoperative leg, traction initially was performed on the operative extremity by the use of only body weight (the "water ski" position). The operative extremity was positioned in neutral flexion/extension, neutral abduction/adduction, and neutral internal/external rotation. There was no change in body weight of the person performing the distraction throughout the study period.

For each case, a standard anterolateral viewing portal was created by the use of fluoroscopic guidance and a subsequent midanterior portal was made with direct visualization. Arthroscopic fluid was allowed to fill the joint, and tissue biopsies were obtained from the anterolateral synovium at approximately the 1:30-o'clock position (Fig 1).

Light Microscopy Analysis

Biopsy specimens were frozen at −80°C in optimum cutting temperature compound (Tissue-Tek, Torrance, CA) and 10-μm cryosections were cut and affixed on

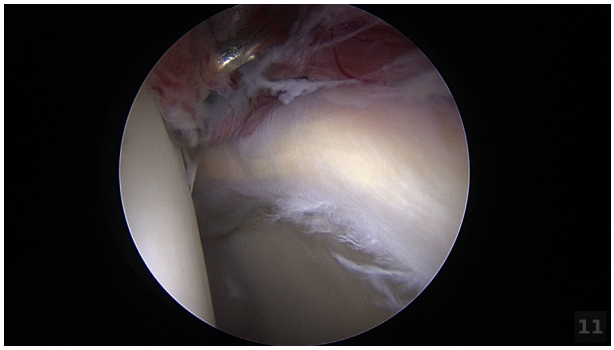

Fig 1. Arthroscopic image of a right hip viewed through the anterolateral portal. The arthroscopic biter has been placed through the midanterior portal to biopsy the anterolateral synovium just adjacent to the labrum.

glass slides. Sections from 3 different depths of the sample were used to obtain a representative sample of the entire specimen. Tissue was stained with hematoxylin and counterstained with eosin as detailed previously.[21] Light microscopy was used to calculate a synovitis score, which has been previously described and validated.[22,23] The synovitis score consists of 3 separate components (lining cell layer, synovial stroma, and inflammatory infiltrate) each graded on a scale of 0-3 points. Scores are added to achieve a final synovitis score. Samples were blinded and scored twice by 2 separate observers (G.D.A., J.S.), with the final score being the average of each evaluation.

Immunofluorescence Analysis

Cryosections were cut and placed on slides as described previously. Slides were fixed with 4% paraformaldehyde in 1× phosphate-buffered saline. Blocking was performed with 1% bovine serum albumin and 1% normal goat serum. Slides were incubated with monoclonal anti-human CD31 (Thermo Fisher Scientific, Waltham, MA) and anti-human CD45 antibodies (BioLegend, San Diego, CA) overnight followed by secondary conjugated antibodies of anti-mouse IgG1 and IgG2a, respectively (Alexa Flour 555 and 488; Life Technologies, Carlsbad, CA). Another set of slides were incubated with monoclonal anti-human CD45 and anti-human CD68 antibodies (Abcam, Cambridge, United Kingdom) followed by conjugated secondary antibodies of anti-mouse IgG2a and IgG2b, respectively (Alexa Flour 555 and 488). A third set were incubated with monoclonal anti-human MMP-3 antibodies (BioLegend, San Diego, CA). All slides were mounted with anti-fade gold containing 4′,6-diamidino-2-phenylindole (Promega, Madison, WI) for visualization of nuclei. Slides were examined under a confocal laser microscope (Zeiss, Göttingen, Germany). Image analysis (ImageJ; National Institutes of Health, Bethesda, MD) was used to calculate the immunostaining area for CD45 (common leukocyte antigen), CD31 (endothelial), and CD68 (macrophage) cell surface markers as used previously.[24] Three separate areas of maximal staining were identified with the confocal microscope. The total area of pixel representation was recorded for each wavelength to assess staining area for each image.

Statistical Analysis

Results are reported as mean ± standard deviation. Comparison between the 2 groups were made with χ^2, Student *t* test, and Mann-Whitney *U* tests with SPSS (v.21, IBM Inc., Armonk, NY). Correlations were performed with linear regression and the Pearson correlation coefficient. Intra- and interobserver reliability was assessed with Cohen kappa statistic. An alpha value of 0.05 was set as significant; SD, standard deviation.

Table 1. Patient Demographics and Group Details

	FAI Group (n = 12)	Instability Group (n = 5)	*P* Value
Age, mean ± SD, yr	34.5 ± 12.2	30.8 ± 14.0	.595
Male/female, n	9/3	0/5	.009
FAI diagnosis, n (cam/pincer/mixed)	6/1/5	–	
Alpha angle, mean ± SD, °	58.4 ± 4.0	50.1 ± 5.2	.011
Center edge angle, mean ± SD, °	30.9 ± 6.2	28.6 ± 4.8	.474

FAI, femoroacetabular impingement; SD, standard deviation.

Results

A total of 17 patients with hip pain refractory to nonoperative treatment were recruited from January 2015 through March 2015 and agreed to participate in the investigation (Table 1). No patients declined to participate. Of these, 12 patients were diagnosed with cam, pincer, or mixed-type impingement, whereas 5 patients received a preoperative diagnosis of hip instability. Age did not differ between the FAI and instability groups; however, there was a significant difference in the proportion of male and female patients (Table 1). All biopsy samples demonstrated synovitis and/or inflammatory cell infiltrate.

Light Microscopy

There was significant agreement between observers when we evaluated the synovitis score (k = 0.7). There was no significant difference in the synovitis score between those in the FAI and instability groups ($P = .186$). A significant positive correlation between number of turns needed for hip distraction and synovitis score (r = 0.653, $P = .005$) was found (Fig 2). In addition, the number of turns needed for distraction also positively correlated with preoperative International Hip Outcomes Tool − Short Version score (r = 0.600, $P = .030$), with a greater number of turns correlating with increasing disability. Synovitis scores also were significantly increased in those patients who received a microfracture ($P = .024$).

Immunohistochemistry

All samples demonstrated the presence of CD45 (common leukocyte antigen) and CD68 (macrophage) positive inflammatory cells. There was no difference in the quantification of inflammatory cells (CD45 of CD68) or neovascularization (determined with CD31 staining) between the FAI and instability groups ($P > .082$). No significant correlations were found between the amount of inflammatory infiltrate noted on immunohistochemistry and functional outcome scores. There was significantly more CD68+ cells in those with cam type FAI ($P = .045$) as well as those who had microfracture performed ($P = .035$). CD45+/CD68− cells were noted

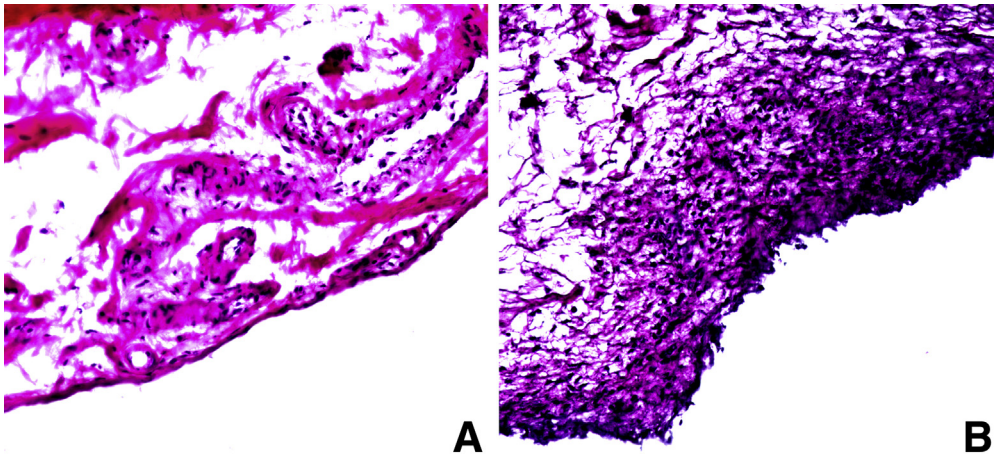

Fig 2. Light microscopy (20×) image of hematoxylin and eosin stained synovium from (A) instability and (B) patients with FAI demonstrating increased cellular infiltration and density in the FAI sample. (FAI, femoroacetabular impingement.)

primarily in the perivascular area immediately adjacent to blood vessels and within the stroma whereas differentiation into CD45+/CD68+ macrophages was noted in the synovial lining layer (Fig 3).

Discussion

This investigation presents evidence for less synovial inflammation in patients with atraumatic hip instability compared with those with classical FAI. The presence of synovial inflammation within both the instability and FAI groups suggests that the pathogenesis of nonarthritic hip pathology involves, at least in part, an inflammatory component. There was a significant positive correlation between intraoperative distraction and synovitis, indicating an increased distraction force was associated with an increased synovitis score. Synovitis scores were increased significantly in patients with cam morphology and cartilage damage. Although immunohistochemistry did not reveal differences between the instability and FAI groups, CD68 was elevated significantly in those with cam morphology and cartilage damage.

In the past, both nonarthritic hip pathology and osteoarthritis of the hip were thought to be noninflammatory in nature. This can be traced back to historical studies that compared osteoarthritic joint samples with those with rheumatoid arthritis.[25,26] Because of the robust nature of inflammation within the rheumatoid samples, underlying inflammation in the osteoarthritis samples was overlooked. More recent data that use modern molecular and cellular detection techniques, however, have confirmed baseline inflammation in a number of musculoskeletal disease states that were once considered non-inflammatory.[10,14,15,24] Although the inciting events leading to the increased inflammation has not been identified definitively, evidence suggests that the initial insult may be a recognized or unrecognized minor trauma, leading to a response of the innate immune system to damage-associated molecular patterns (DAMPs).[11] These

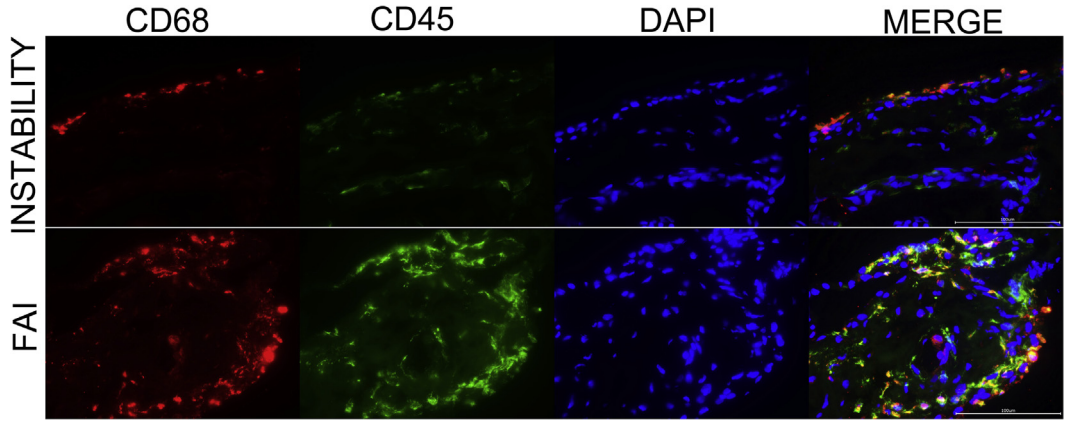

Fig 3. Confocal microscopic image of synovium from instability and patients with FAI demonstrating increased cellular staining in the patient with FAI for CD45 (green) and CD68 (red). In addition, there is CD45+/CD68− fluorescence within the perivascular and stromal tissue, whereas CD45+/CD68+ macrophages (yellow) are more peripheral in the synovial lining layer. (FAI, femoroacetabular impingement.)

DAMPs include products of tissue damage that are recognized by the host immune system and may include damaged intra-articular products such as fibronectin, hyaluronic acid, and biglycan.[11] These damaged products bind to one of the many pattern-recognition receptors of the innate immune system and set off a cascade of events leading to recruitment of inflammatory cells and the production of inflammatory mediators.[11,27,28]

Our finding that synovial inflammation was correlated directly with the number of turns needed for hip distraction, a surrogate for hip instability, is not surprising. Given the mechanistic hypothesis described previously, inflammatory reaction should be related to the relative amount of DAMPs within the intra-articular space. Classical FAI, with its mechanical abutment of the femoral head-neck junction against the acetabulum as well as contra-coup lesion in pincer pathology, would likely create a larger number of DAMPs compared with hips with microinstability. Compared with FAI, instability does not lead to direct impingement of tissues but rather subtle motion abnormalities of the femur within the acetabulum and potentially less articular cartilage damage. This would lead to lower levels of mechanical degradation of native proteins such as collagen, fibronectin, and hyaluronic acid and, therefore, generation of fewer DAMPs and a less robust inflammatory response.

The presence of joint inflammation as a component of nonarthritic hip pathology is only just beginning to be recognized. Elias-Jones et al.[16] recently examined labrum samples from a group of patients undergoing hip replacement for osteoarthritis and compared them with those with FAI, finding increased presence of inflammatory cells and neovascularization within the FAI group. Although different types of samples were used (labrum vs synovial tissue) and our groups differed (osteoarthritis vs instability), both investigations reported increased inflammation within the FAI group. Notably, macrophages were prominently featured in both studies, with this investigation finding no difference between FAI and microinstability. This could be related, however, to the closer similarity of the instability and FAI groups versus the osteoarthritis and FAI groups or the fact that our study may be underpowered. A finding of no difference, it should be noted, does not imply that there was no inflammation within the groups, because both may have had similarly elevated levels.

Uniquely, in this current study, CD45+/CD68− cells were localized in the perivascular areas whereas CD45+/CD68+ cells were identified in the synovial lining of the joint. This finding indicates that mononuclear cells are undergoing differentiation towards a macrophage-specific phenotype as they near the joint articular space. This enhances the hypothesis that an innate immune response to extracellular matrix damage can induce recruitment, differentiation, and activation of synovial macrophages. These macrophages play an important role in the pathogenesis of inflammation within the joint, because they have been shown to produce a number of catabolic inflammatory mediators.[29-31]

Limitations

Limitations of this investigation are primarily related to the difficulty in establishing a definitive diagnosis of hip instability. Because of this, it is possible that some of the patients classified as unstable in this investigation may actually have subtle FAI or other diagnoses. This finding is mitigated by the fact that objective criteria were used, such as intraoperative distraction and a lack of radiographic FAI characteristics, to help define this group. Sample size is another limitation of this investigation, because this study was likely underpowered to detect significant differences in some measures. The finding of significant differences in a number of measures, however, demonstrates that a likely difference in the inflammatory profile of these 2 disease states does, in fact, exist, although a type I error is still possible. Lastly, the difference in inflammation could be related to anatomic sampling variability, individual differences between the group (female vs male), patient activity levels, or medical comorbidities. To minimize these effects, a consistent and reproducible protocol for sample acquisition was developed and patients with chronic disease were excluded.

Conclusions

Decreased synovial inflammation was associated with increased distractibility, but both instability and FAI groups demonstrated baseline levels of synovial inflammation. Synovitis scores also were increased in patients with cartilage damage.

References

1. Boykin RE, Anz AW, Bushnell BD, Kocher MS, Stubbs AJ, Philippon MJ. Hip instability. *J Am Acad Orthop Surg* 2011;19:340-349.
2. Harris JD, Gerrie BJ, Lintner DM, Varner KE, McCulloch PC. Microinstability of the hip and the splits radiograph. *Orthopedics* 2016;39:e169-e175.
3. Jackson TJ, Peterson AB, Akeda M, et al. Biomechanical effects of capsular shift in the treatment of hip microinstability: Creation and testing of a novel hip instability model. *Am J Sports Med* 2016;44:689-695.
4. Kalisvaart MM, Safran MR. Microinstability of the hip—it does exist etiology, diagnosis and treatment. *J Hip Preserv Surg* 2015;2:123-135.
5. Mitchell RJ, Gerrie BJ, McCulloch PC, et al. Radiographic evidence of hip microinstability in elite ballet. *Arthroscopy* 2016;32:1038-1044.e1.

6. Nepple JJ, Clohisy JC. The dysplastic and unstable hip: A responsible balance of arthroscopic and open approaches. *Sports Med Arthrosc* 2015;23:180-186.
7. Shu B, Safran MR. Hip instability: Anatomic and clinical considerations of traumatic and atraumatic instability. *Clin Sports Med* 2011;30:349-367.
8. Bayne CO, Stanley R, Simon P, et al. Effect of capsulotomy on hip stability—a consideration during hip arthroscopy. *Am J Orthop (Belle Mead NJ)* 2014;43:160-165.
9. Ganz R, Parvizi J, Beck M, Leunig M, Notzli H, Siebenrock KA. Femoroacetabular impingement: A cause for osteoarthritis of the hip. *Clin Orthop Relat Res* 2003:112-120.
10. Sohn DH, Sokolove J, Sharpe O, et al. Plasma proteins present in osteoarthritic synovial fluid can stimulate cytokine production via Toll-like receptor 4. *Arthritis Res Ther* 2012;14:R7.
11. Sokolove J, Lepus CM. Role of inflammation in the pathogenesis of osteoarthritis: Latest findings and interpretations. *Ther Adv Musculoskelet Dis* 2013;5:77-94.
12. Berenbaum F. Osteoarthritis as an inflammatory disease (osteoarthritis is not osteoarthrosis!). *Osteoarthritis Cartilage* 2013;21:16-21.
13. Atukorala I, Kwoh CK, Guermazi A, et al. Synovitis in knee osteoarthritis: a precursor of disease? *Ann Rheum Dis* 2016;75:390-395.
14. Robertson CM, Chen CT, Shindle MK, Cordasco FA, Rodeo SA, Warren RF. Failed healing of rotator cuff repair correlates with altered collagenase and gelatinase in supraspinatus and subscapularis tendons. *Am J Sports Med* 2012;40:1993-2001.
15. Shindle MK, Chen CC, Robertson C, et al. Full-thickness supraspinatus tears are associated with more synovial inflammation and tissue degeneration than partial-thickness tears. *J Shoulder Elbow Surg* 2011;20:917-927.
16. Elias-Jones CJ, Farrow L, Reilly JH, et al. Inflammation and neovascularization in hip impingement: Not just wear and tear. *Am J Sports Med* 2015;43:1875-1881.
17. de Lange-Brokaar BJ, Ioan-Facsinay A, van Osch GJ, et al. Synovial inflammation, immune cells and their cytokines in osteoarthritis: A review. *Osteoarthritis Cartilage* 2012;20:1484-1499 (review).
18. Werner CM, Ramseier LE, Ruckstuhl T, et al. Normal values of Wiberg's lateral center-edge angle and Lequesne's acetabular index—a coxometric update. *Skeletal Radiol* 2012;41:1273-1278.
19. Beighton P, Horan F. Orthopaedic aspects of the Ehlers-Danlos syndrome. *J Bone Joint Surg Br* 1969;51:444-453.
20. Griffin DR, Parsons N, Mohtadi NG, Safran MR. A short version of the International Hip Outcome Tool (iHOT-12) for use in routine clinical practice. *Arthroscopy* 2012;28:611-616. quiz 616-618.
21. Lillie RD, Pizzolato P, Welsh RA, Holmquist ND, Donaldson PT, Berger C. A consideration of substitutes for alum hematoxylin in routine histologic and cytologic diagnostic procedures. *Am J Clin Pathol* 1973;60:817-819.
22. Krenn V, Morawietz L, Burmester GR, et al. Synovitis score: Discrimination between chronic low-grade and high-grade synovitis. *Histopathology* 2006;49:358-364.
23. Krenn V, Morawietz L, Haupl T, Neidel J, Petersen I, Konig A. Grading of chronic synovitis—a histopathological grading system for molecular and diagnostic pathology. *Pathol Res Pract* 2002;198:317-325.
24. Abrams GD, Luria A, Carr RA, Rhodes C, Robinson WH, Sokolove J. Association of synovial inflammation and inflammatory mediators with glenohumeral rotator cuff pathology. *J Shoulder Elbow Surg* 2016;25:989-997.
25. Nettelbladt E, Sundblad L. Protein patterns in synovial fluid and serum in rheumatoid arthritis and osteoarthritis. *Arthritis Rheum* 1959;2:144-151.
26. Pruzanski W, Russell ML, Gordon DA, Ogryzlo MA. Serum and synovial fluid proteins in rheumatoid arthritis and degenerative joint diseases. *Am J Med Sci* 1973;265:483-490.
27. Okamura Y, Watari M, Jerud ES, et al. The extra domain A of fibronectin activates Toll-like receptor 4. *J Biol Chem* 2001;276:10229-10233.
28. Schaefer L, Babelova A, Kiss E, et al. The matrix component biglycan is proinflammatory and signals through Toll-like receptors 4 and 2 in macrophages. *J Clin Invest* 2005;115:2223-2233.
29. Parameswaran N, Patial S. Tumor necrosis factor-alpha signaling in macrophages. *Crit Rev Eukaryot Gene Expr* 2010;20:87-103 (review).
30. Schling P, Rudolph C, Heimerl S, Fruth S, Schmitz G. Expression of tumor necrosis factor alpha and its receptors during cellular differentiation. *Cytokine* 2006;33:239-245.
31. Freigang S, Ampenberger F, Weiss A, et al. Fatty acid-induced mitochondrial uncoupling elicits inflammasome-independent IL-1alpha and sterile vascular inflammation in atherosclerosis. *Nat Immunol* 2013;14:1045-1053.