

# Specific Pain Conditions & Their Management

PEDIATRIC PAIN MANAGEMENT

Ardin S. Berger, D.O.  
Department of Anesthesiology & Pain Management  
Version 1, revised 10/22/19

# Contents

## Pain Conditions

- Differential Diagnoses
  - › CRPS
  - › EDS/hypermobility
  - › Sickle Cell Disease
  - › Rheumatologic
  - › Knee Pain in Children\*
  - › Erythromelalgia
  - › Chemotherapy Induced Neuropathy\*
  - › Functional Neurological Symptom Disorder
  - › Somatization
    - Management\*
- Back Pain
  - › Red Flag Symptoms

## Abdominal Pain

- Categorization
- Common Causes
- Red Flag Symptoms
- Pancreatitis\*

## Headache

- Differential
- Red Flag Symptoms
- Post Feverfew Syndrome\*

## Management Modalities

- Exercise Therapy
- Medications
- Interventions
- Desensitization\*
- Motivational Interviewing\*
- CBT
- Self Efficacy\*

## Differential Diagnoses

- CRPS
- Ehlers Danlos Syndrome / Benign Joint Hypermobility
- Sickle Cell Disease
- Rheumatologic Disease
- Pediatric Knee Pain\*
- Erythromelalgia
- Chemotherapy Induced Neuropathy\*
- Somatization
  - › Management\*
- Conversion
  - › “La Belle Indifference”

# Complex Regional Pain Syndrome

## CRPS

- Budapest Criteria: All of the following criteria must be met to have a positive diagnosis of complex regional pain syndrome:
  - › Patient has continuing pain that is disproportionate to the inciting event
  - › Patient must have at least **1 sign in 2 or more** of the categories below
  - › Patient reports at least **1 symptom in 3 or more** of the categories below
  - › No other diagnosis can better explain the signs and symptoms
  - › Sensory
    - Allodynia
    - Hyperalgesia
  - › Vasomotor
    - Differences in skin temperature (more than 1 degree celsius)
    - Differences in skin coloration between different sides of the body
    - Skin color changes
  - › Sudomotor/Edema
    - Changes or asymmetry in swelling
    - Changes or asymmetry in sweating
  - › Motor/Trophic
    - Decreased range of motion
    - Motor symptoms (tremors, weakness, dystonia)
    - Changes in skin, hair, nails (dystrophic)
- Treatment
  - › Desensitization
  - › Pharmacological
  - › Sympathetic blockade

# Ehlers Danlos Syndrome

## 1997 Criteria for Hypermobile type Ehlers Danlos Syndrome

- Major criteria
  - › Skin involvement
    - Hyperextensibility and/or smooth, velvety skin
    - Generalized joint hypermobility
- Minor criteria
  - › Recurring joint dislocations
  - › Chronic joint/limb pain
  - › Positive family history
- The presence of one or both of the major criteria is necessary for clinical diagnosis; the presence of one or more minor criteria contributes to the diagnosis, but in the absence of a major criterion, they are not sufficient to establish a diagnosis.

# Ehlers Danlos Syndrome

EDS/hypermobility (2017): The clinical diagnosis of hypermobile EDS needs the simultaneous presence of all criteria: 1, 2 & 3

- CRITERION 1 - Generalized Joint Hypermobility


- › One of the following:

- Beighton Score:

- $\geq 6$  Pre-pubertal children
      - $\geq 5$  Pubertal patients to age of 50
      - $\geq 4$  Patients over age of 50

- Beighton 1 point below cutoff, two or more of following required:

- Can (could) place hands flat on the floor w/o bending knees?
      - Can (could) bend thumb to touch forearm?
      - As a child, amused friends by contorting body or doing the splits?
      - As a child or teenager, did shoulder or kneecap dislocate  $> 1x$ ?
      - "Do you consider yourself 'double jointed'"?



# Ehlers Danlos Syndrome

CRITERION 2 – Two or more of the following features (A, B, or C) must be present

- Feature A (five required)
  - › Unusually soft or velvety skin
  - › Mild skin hyperextensibility
  - › Unexplained striae distensae or rubae at the back, groins, thighs, breasts and/or abdomen in adolescents, assigned-males or pre-pubertal assigned-females without history of significant weight gain/loss
  - › Bilateral piezogenic papules of the heel
  - › Recurrent or multiple abdominal hernia(s)
  - › Atrophic scarring involving at least two sites and without the formation of truly papyraceous and/or hemosideric scars as seen in classical EDS
  - › Pelvic floor, rectal, and/or uterine prolapse in children, men or nulliparous women without a history of morbid obesity or other known predisposing medical condition
  - › Dental crowding and high or narrow palate
  - › Arachnodactyly, as defined in one or more of the following: (i) positive wrist sign (Walker sign) on both sides, (ii) positive thumb sign (Steinberg sign) on both sides
  - › Arm span-to-height ratio  $\geq 1.05$
  - › Mitral valve prolapse (MVP) mild or greater based on strict echocardiographic criteria
  - › Aortic root dilatation with Z-score  $> +2$
- Feature B: Positive family history; one or more first-degree relatives independently meeting the current criteria for hEDS
- Feature C (one required)
  - › Musculoskeletal pain in two or more limbs, recurring daily for at least 3 month
  - › Chronic, widespread pain for  $\geq 3$  months
  - › Recurrent joint dislocations or frank joint instability, in the absence of trauma

# Ehlers Danlos Syndrome

CRITERION 3 - All of the following prerequisites **MUST** be met

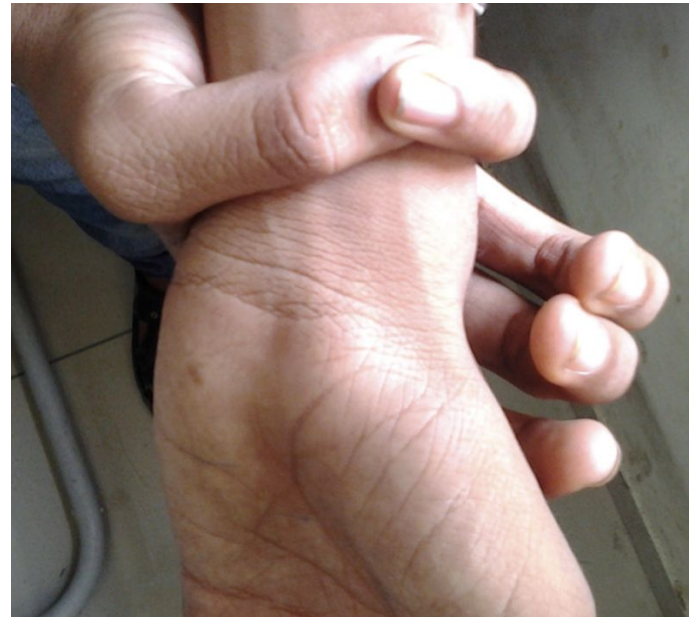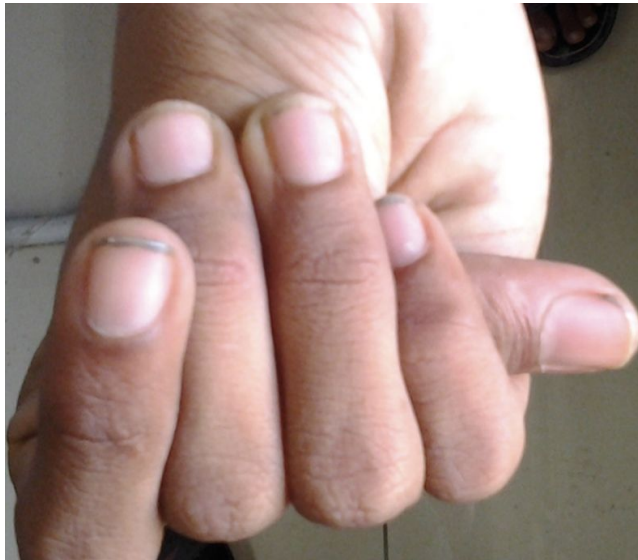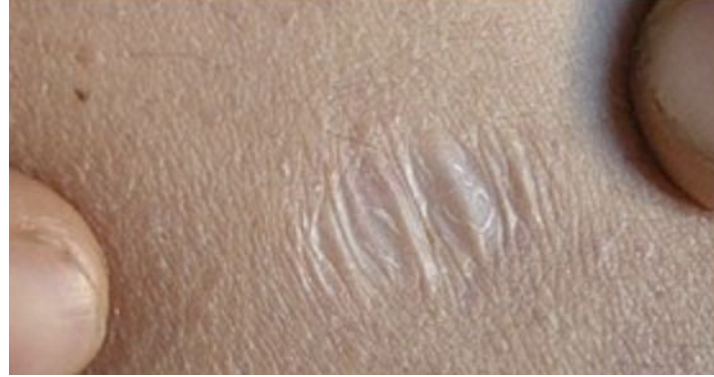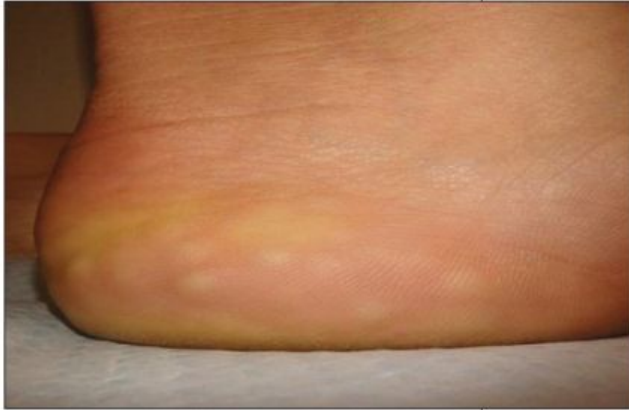- Absence of unusual skin fragility, which should prompt consideration of other types of EDS
- Exclusion of other heritable and acquired connective tissue disorders, including autoimmune rheumatologic conditions. In patients with an acquired CTD (e.g. Lupus, Rheumatoid Arthritis, etc.), additional diagnosis of hEDS requires meeting both Features A and B of Criterion 2. Feature C of Criterion 2 (chronic pain and/or instability) cannot be counted toward a diagnosis of hEDS in this situation.
- Exclusion of alternative diagnoses that may also include joint hypermobility by means of hypotonia and/or connective tissue laxity. Alternative diagnoses and diagnostic categories include, but are not limited to, neuromuscular disorders (e.g. Bethlem myopathy), other hereditary disorders of the connective tissue (e.g. other types of EDS, Loeys-Dietz syndrome, Marfan syndrome), and skeletal dysplasias (e.g. osteogenesis imperfecta).

# Ehlers Danlos Syndrome

## Benign Hypermobility Syndrome

- For those failing to meet diagnostic criteria for hEDS, may fall into category for benign hypermobility syndrome
  - › Similar signs and symptoms as well as associated diagnoses
  - › Similar treatment plan

# Ehlers Danlos Syndrome



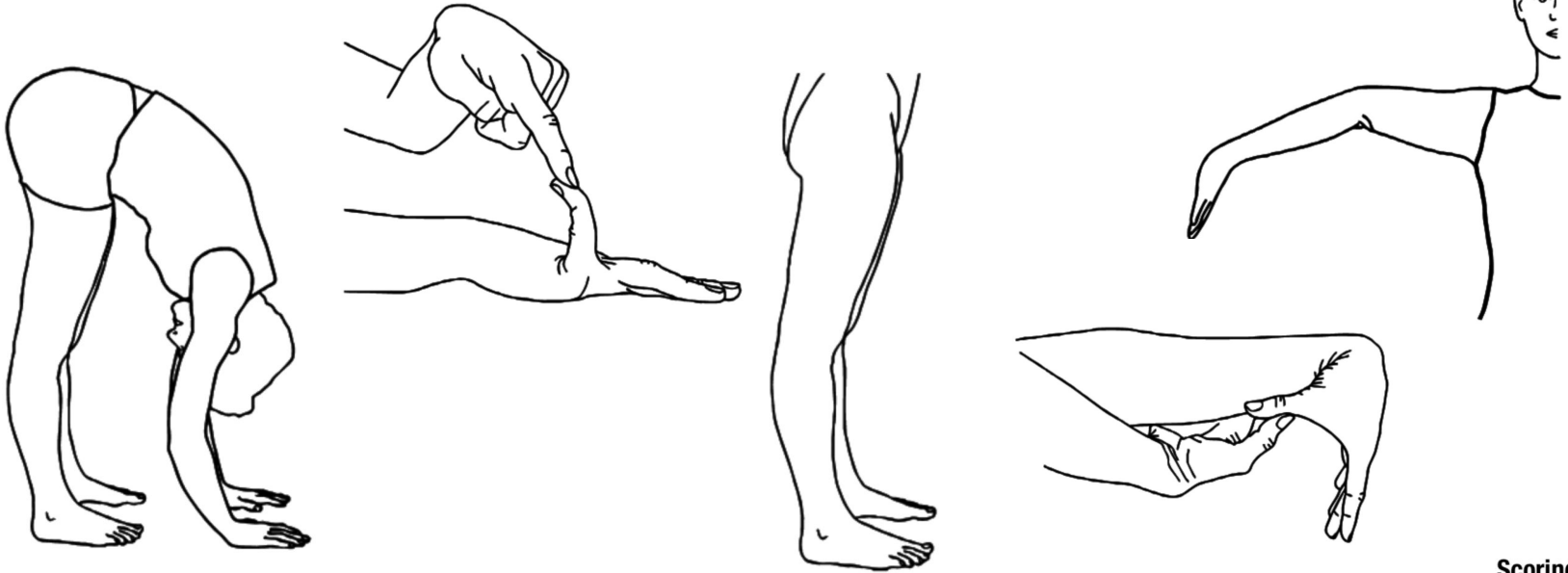
# Ehlers Danlos Syndrome - Associated Conditions

## Proposed associated conditions

- TPSAB1
  - › Chronic musculoskeletal pain
  - › Dysautonomia
    - Postural Orthostatic Tachycardia Syndrome (POTs)
  - › Cutaneous complaints
    - Mast Cell Activation Syndrome
  - › Gastrointestinal complaints
    - Chronic constipation
    - Irritable bowel syndrome
- Headaches
  - › Spontaneous CSF leak
  - › Migraine

# Ehlers Danlos Syndrome

## Beighton Scoring System



Description	Bilateral Testing	Scoring (max. points)
Passive dorsiflexion of the fifth metacarpophalangeal joint to $\geq 90$ degrees	Yes	2
Passive hyperextension of the elbow $\geq 10$ degrees	Yes	2
Passive hyperextension of the knee $\geq 10$ degrees	Yes	2
Passive apposition of the thumb to the flexor side of the forearm, while shoulder is flexed 90 degrees, elbow is extended, and hand is pronated	Yes	2
Forward flexion of the trunk, with the knees straight, so that the hand palms rest easily on the floor	No	1
Total		9

# Sickle Cell Disease

- Presentation
  - › Acute Chest Syndrome
    - An acute illness characterized by fever and/or respiratory signs and symptoms, accompanied by a new pulmonary infiltrate involving at least one complete lung segment consistent with the presence of alveolar consolidation on a chest x ray.
  - › Vaso-Occlusive Crisis
    - Pain resulting from tissue ischemia as a result of blockage of blood vessels, occurring in a variety of vascular beds, but most commonly in the bone or bone marrow and requiring analgesic medication.
  - › Central Sensitization
  - › Neuropathic Pain

# Sickle Cell Disease

- Medications
  - › Opioids
    - Consider PCA<sup>[VanBeers]</sup> with baseline infusion<sup>[Gonzalez]</sup> for acute crisis
    - Care may involve chronic opioids
      - Tolerance
      - Continue baseline dose, with additional dosing for crisis
  - › NSAIDs
  - › Muscle Relaxants
  - › Neuropathic Medications – if hyperalgesia is present
- Regional
  - › Thoracic epidural may be useful for acute chest syndrome
- Physical therapy
  - › To address joint, osseous, and deconditioning effects
- TENS for localized pain
- Behavioral medicine

# Common Causes of Pediatric Chronic Pain

- Rheumatologic Diseases
  - › Lyme Disease
  - › Dermatomyositis
  - › Kawasaki Disease
  - › Behcet's Syndrome
  - › Juvenile Scleroderma
  - › Juvenile Dermatomyositis
  - › Juvenile Idiopathic Arthritis
  - › Patellofemoral Pain Syndrome
  - › Systemic Lupus Erythematosus
  - › Mixed Connective Tissue Disease

# Common Causes

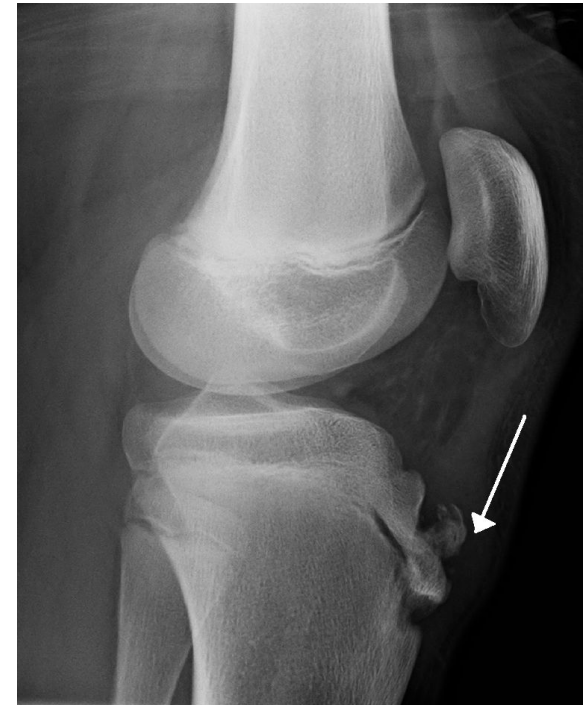## Knee Pain in Children\*

- Monoarticular
  - › Septic arthritis
  - › Osteomyelitis
  - › Malignancy
  - › Trauma
    - Fracture, hemarthroses
  - › Osteonecrosis
    - Legg-Calvé-Perthes disease (15% bilateral)
  - › Oligoarticular JIA
  - › Lyme arthritis
  - › Slipped capital femoral epiphysis
  - › CRPS
  - › Osgood-Schlatter disease
- Polyarticular
  - › Ehlers Danlos Syndrome
  - › Systemic Lupus Erythematosus
  - › Juvenile Idiopathic Arthritis
  - › IBD-associated arthritis

# Knee Pain – Common Causes

## Osgood-Schlatter

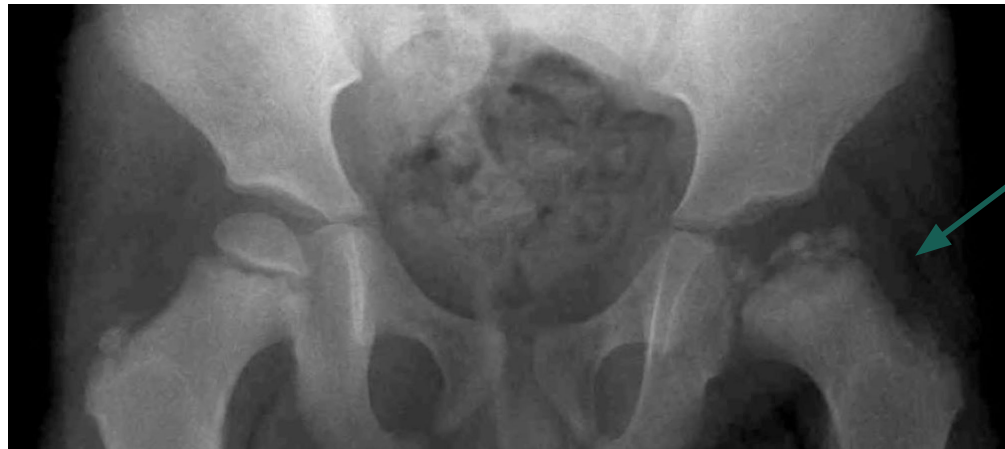- Cause
  - › Overuse condition
    - Repeated tension on upper tibial growth plate
    - Inflammation of patellar ligament at tibial tuberosity
- Diagnosis
  - › Often symptomatic
  - › Xray
    - Early: soft tissue swelling with loss of the sharp margins of the patellar tendon
    - Late: bone fragmentation at the tibial tuberosity
  - › Ultrasound
    - Swelling of the unossified cartilage and overlying soft tissues
    - Fragmentation and irregularity of ossification center; reduced internal echogenicity
    - Distal patellar tendon thickening
    - Infrapatellar bursitis
- Management
  - › Commonly conservative; infrequently surgical
  - › Spontaneously resolves once the physis closes



# Knee Pain – Common Causes

## Legg-Calvé-Perthes disease

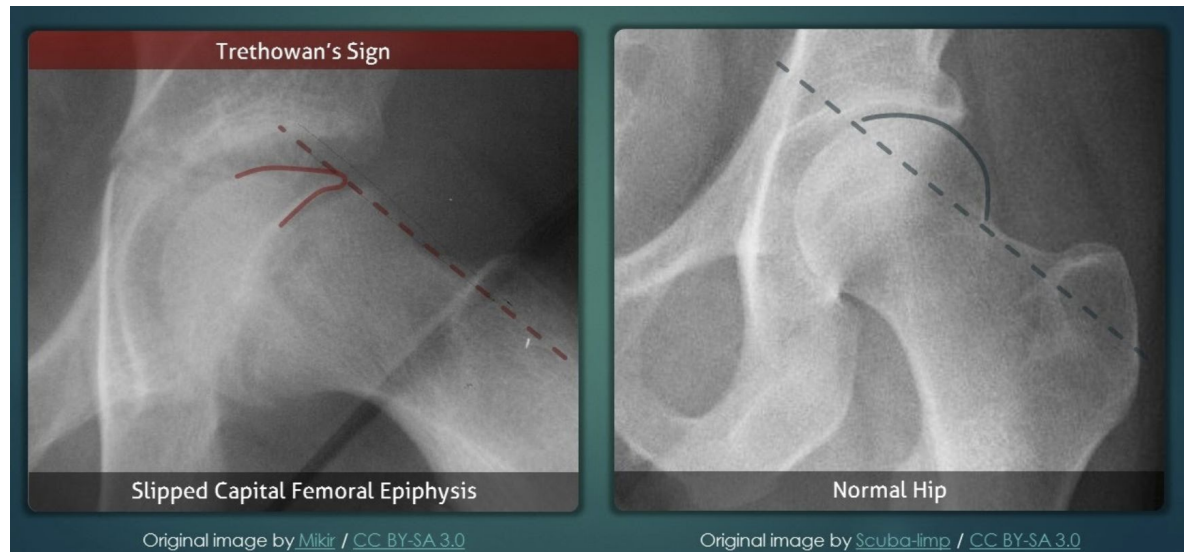
- Idiopathic avascular necrosis of femoral head
- Knee pain, hip pain, limp in 5-8 years old
- Age of diagnosis prognostic indicator
  - › <6 years old spherical femoral head restoration likely
- Management
  - › Conservative
    - Activity restrictions
    - Non-weight bearing restrictions
    - Physical therapy
  - › Surgical correction
- Radiographic findings
  - › Early
    - Widening of the joint space
    - Crescent sign: fracture through necrotic bone □ subchondral linear lucency
  - › Late
    - Fragmentation, collapse of the femoral epiphysis with areas of increased sclerosis and lucency
    - Coxa magna: broad femoral head
    - Coxa plana: flat femoral head
    - Short femoral neck; physeal growth arrest



# Knee Pain – Common Causes

## Slipped capital femoral epiphysis

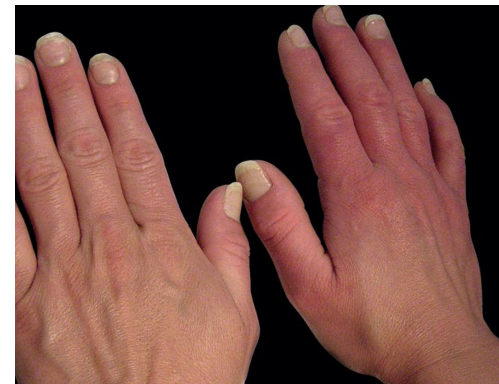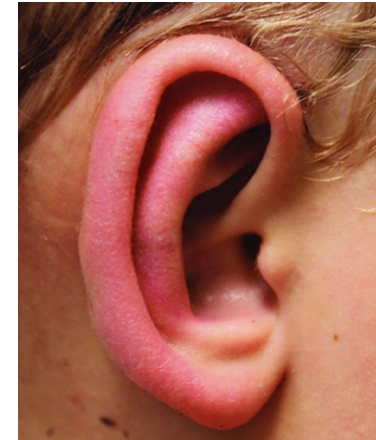- Knee pain referred from hip 15-50%
    - › Medial obturator nerve
  - Risk Factors
    - › Obese, assigned-male
    - › 10-16 year old (rapid growth)
  - Treatment
    - › Percutaneous pin placement
    - › Contralateral hip fixation
    - › ORIF
- Imaging
    - › Xray
      - Klein line
        - Superior edge of femoral neck
        - Intersects lateral portion of superior femoral epiphysis
        - **Trethowan sign:** Klein line fails to intersect the epiphysis
      - Epiphysiolysis
      - Blurring of proximal femoral metaphysis



# Common Pediatric Chronic Pain Conditions

## Erythromelalgia

- Frequently symmetric erythema, swelling, painful burning
- Often incited by heat; worsened by cold
- Lower > upper extremities; distal > proximal
- Pathophysiology
  - › Voltage-gated Na channel  $\alpha$ -subunit NaV1.7
    - Encodes gene SCN9A which is expressed in
      - Nociceptors of the dorsal root ganglion
      - Sympathetic ganglion neurons
- Cause
  - › Primary
    - Autosomal dominant
    - Hyper-excitability of c-fibers in dorsal root ganglion - pain
    - Hypo-excitability sympathetic ganglion neurons - microvascular alterations
  - › Secondary
    - Small fiber peripheral neuropathy
    - Polycythemia vera
    - Essential thrombocytosis
    - Hypercholesterolemia
    - Mushroom or mercury poisoning
    - Autoimmune disorders



# Common Pediatric Chronic Pain Conditions

## Chemotherapy Induced Neuropathy\*

- Agents: cisplatin, oxaliplatin, taxanes, vinca alkaloids, bortezomib
- Effects: dose dependent & cumulative
  - › Often slow improvement after discontinuation of responsible agent
  - › May worsen prior to improvement after agent is discontinued
- Distribution: symmetric, distal, "stocking and glove"
  - › Sensory > motor symptoms (except thalidomide and paclitaxel)
- Prevention
  - › Gabapentin<sup>[Aghili]</sup> and oxcarbazepine<sup>[Argyriou]</sup> may be of benefit
  - › Cardiovascular activity/exercise has shown preliminary promise
- Treatment
  - › Duloxetine with some benefit<sup>[Smith]</sup>
  - › Dose delay, reduction, or intermittent administration
  - › Physical therapy & rehabilitation for gait instability, motor effects
- Differential
  - › Acute neurotoxicity
    - Oxaliplatin and paclitaxel
    - Clinically distinct from CIPN
    - Not necessarily peripheral, noncumulative
    - Usually improves within days of administration
    - Recurs with subsequent doses
    - Does respond to lengthened infusion duration (CPIN does not)

# Common Pediatric Chronic Pain Conditions

## Somatic Symptom Disorder\* [APA]

- 1 or more somatic symptoms accompanied by excessive thoughts, feelings, behaviors related to the somatic symptoms
  - › Symptoms cause significant distress and/or dysfunction
  - › May or may not be explained by a recognized medical condition
- “Somatic symptom disorder” replaced somatization disorder, undifferentiated somatoform disorder, hypochondriasis, and pain disorder in DSM-5
- Management
  - › Acknowledge physical & emotional suffering
  - › Emphasize somatic symptoms are real
  - › Assure patient that presence of psychiatric disorder doesn’t negate reality of suffering
  - › If no identified medical disorder, avoid debating whether symptoms are result of psychiatric or non-psychiatric illness
  - › In presence of identified medical disorder, avoid telling patients that they are blowing symptoms out of proportion
- Diagnosis:
  - › One or more somatic symptoms that cause distress or psychosocial impairment
  - › Excessive thoughts, feelings, or behaviors associated with the somatic symptoms, as demonstrated by one or more of the following:
    - Persistent thoughts about the seriousness of the symptoms
    - Persistent, severe anxiety about the symptoms or one’s general health
    - The time and energy devoted to the symptoms or health concerns is excessive
  - › Although the specific somatic symptom(s) may change, the disorder is persistent (usually more than six months)

# Common Pediatric Chronic Pain Conditions

- Functional Neurologic Symptom Disorder<sup>[APA]</sup>
  - › “Conversion disorder” now falls under this category
  - › Somatic symptom disorder with predominant pain
    - Pain present >6 months
  - › Neurologic symptoms inconsistent with neurologic disease, but cause distress and/or impairment
    - Seizures or attacks – “psychogenic nonepileptic seizures”
      - Abnormal generalized limb shaking and apparent impaired or loss of consciousness resembling epileptic attacks or fainting (syncope)
    - Weakness or paralysis
    - Abnormal movement (dystonic movement, gait disorder, myoclonus, tremor)
    - Anesthesia or sensory loss
      - Loss of touch or pain sensation
    - Special sensory symptom
      - Visual (eg, double vision, blindness), hearing (eg, deafness), or olfactory disturbance
    - Swallowing symptom (“globus pharyngeus”)
    - Speech symptoms
    - Mixed symptoms
      - Two or three different subtypes of symptoms are present (eg, paralysis plus blindness)

# Common Pediatric Chronic Pain Conditions

## Functional Neurological Symptom Disorder, cont.

- “La Belle Indifference”
- DSM-V Diagnostic Criteria
  - › One or more symptoms of altered voluntary motor or sensory function
  - › Clinical findings that demonstrate incompatibility between the symptom and recognized neurologic or general medical conditions
    - Hoover's sign of functional limb weakness
    - Positive entrainment test for functional tremor
      - Voluntary movements at a given frequency with the extremity contralateral to the side under assessment
  - › The symptom or deficit is not better explained by another medical or mental disorder
  - › The symptom or deficit causes significant distress, psychosocial impairment, or warrants medical evaluation
- Diagnosis does not require determination that symptoms are not feigned

## Back Pain Red Flag Symptoms

- Unexplained fever
- Night sweats
- Weight loss
- Night pain
- Constant pain
- Bowel function changes
- Urinary retention
- Neurologic changes in legs
  - › Trouble walking, foot drop, weakness
  - › Loss of reflexes, sensory changes

# Abdominal Pain

- Categorization
  - › Visceral
  - › Somatic
  - › Referred
    - Referral patterns
    - Viscerosomatic convergence
    - Viscerovisceral convergence
  - › Common Causes
    - Pancreatitis\*
  - › Red Flag Symptoms



# Abdominal Pain - Categorization

## Visceral

- Tension, stretching, or ischemia to the organ itself stimulates visceral nociceptors
  - › Bilateral, unmyelinated fibers enter spinal cord at multiple levels; typically experienced midline
    - Dull & poorly localized quality
      - Foregut structure (lower esophagus, stomach)
        - Epigastric region
      - Midgut structures (small intestine)
        - Periumbilical region
      - Hindgut structures (large intestine)
        - Lower quadrants
    - › Relatively insensitive to cutting, burning, etc.
    - › Accompanied by nausea, vomiting, vital sign changes, emotional effects
    - › Congestion and inflammation cause neural ending sensitization, decreasing threshold

## Somatic

## Referred

## Abdominal Pain - Categorization

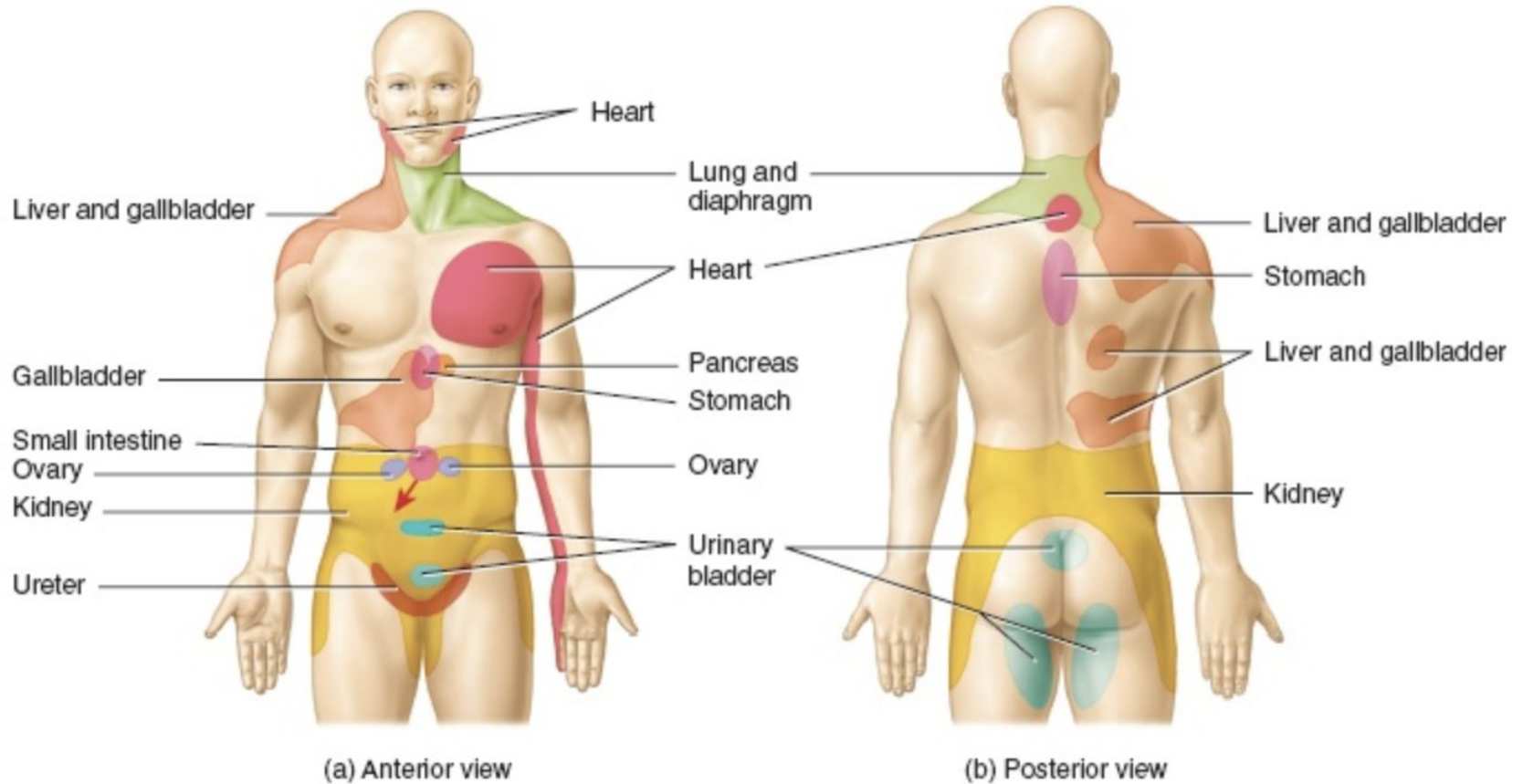
- Visceral
- Somatic
  - › Noxious stimulation of parietal peritoneum
  - › Ischemia, inflammation, or stretch transmitted via myelinated afferents to dorsal root ganglia
    - Same side and dermatomal level as origin
  - › Sharp, intense, discrete, and localized
    - McBurney's point
  - › Aggravated by coughing or movement
- Referred

## Abdominal Pain - Categorization

- Visceral
- Somatic
- Referred
  - › Many characteristics similar to parietal pain
  - › Experienced in remote regions supplied by same dermatome as affected organ
    - Shared central pathways for afferent neurons from different sites
  - › Kehr's sign: spleen referred to left shoulder

# Abdominal Pain – Referred Pain

- Referral Patterns 



# Abdominal Pain - Categorization

## Viscerosomatic convergence

- Somatic injury and visceral inflammation can respectively alter central processing of visceral and somatic inputs<sup>[Cameron]</sup>
- Visceral pain often accompanying somatic pain conditions and vice versa

## Viscerovisceral convergence

- Pain from one organ is referred to another

## Abdominal Pain – Common Pediatric Sources<sup>[Reust]</sup>

All Ages	Infants & Toddlers	School Age	Adolescents
Appendicitis	Hirschsprung	Abdominal Migraine	Ectopic Pregnancy
Obstruction	Infantile Colic	Functional Pain	Functional Pain
Child Abuse	Inguinal Hernia	Henoch-Schönlein purpura	Inflammatory Bowel Disease
Constipation	Intussusception	Intussusception	Irritable Bowel Syndrome
Diet	Lactose Intolerance	Lead Poisoning	Menstrual-related
Gallbladder Dx	Lead Poisoning	Mononucleosis	Mononucleosis
Gastroenteritis	Midgut Malrotation	Volvulus	Omental Infarction
HUS	Meckel Diverticulum		Ovarian or Testicular Torsion
Mesenteric Adenitis	Volvulus		Pelvic Inflammatory Disease
Pancreatitis			Sexually Transmitted Infection
Sickle Cell Crisis			
Trauma			
Upper Respiratory			
Urinary Tract Infection			

# Abdominal Pain – Common Pediatric Sources

## Pancreatitis Management\*

- NPO, hydration
- Adjunctive medications
- Opioids (exception to opioid-free approach to abdominal pain)
- Celiac plexus blockade
  - › 1-5 ganglia carrying afferents from upper abdominal organs
    - Stomach to mid-transverse colon, including pancreas and gallbladder
    - Afferent fibers carry visceral nociceptive signals from distal stomach, pancreas, gallbladder, other hepatobiliary structures, duodenum, small intestine, and large intestine to the mid-transverse colon (visceral pain)
  - › Sympathetic preganglionic fibers (T5-T12)
    - Greater splanchnic nerves (T5-T10)
    - Lesser splanchnic nerves (T10-T11)
    - Least splanchnic nerves (T12)
  - › Does not carry somatic nerve fibers from the upper abdominal wall
  - › Typically at the level of the L1 vertebral body anterolateral to the aorta
    - Located anywhere from T12-L1 disc space to the level of the L2 vertebral body

## Abdominal Pain – Red Flag Symptoms

- Red Flag Symptoms
  - › Dysphagia
  - › Biliary emesis
  - › Delayed puberty
  - › Unexplained fever
  - › Nocturnal diarrhea
  - › Associated arthritis
  - › Involuntary weight loss
  - › Gastrointestinal blood loss
  - › Persistent or cyclic vomiting
  - › Deceleration of linear growth
  - › Pain awakens patient from sleep
  - › Family history of IBD, celiac, PUD
  - › Persistent right upper or right lower quadrant pain
  - › Hepatosplenomegaly, masses, perianal lesions, CVA tenderness

# Headache – Differential Diagnoses

- Evaluation
- Differential Diagnoses



## Headache – Evaluation

- Physical Examination
  - › Vital signs
  - › Specific signs
    - Sinus tenderness
    - Nuchal rigidity
    - Thyromegaly
    - Head circumference
    - Signs of neurocutaneous syndrome
  - › Neurological Examination
    - Altered mental status
    - Abnormal ocular movements
    - Optic disc distortion
    - Motor or sensory asymmetry
    - Coordination disturbances
    - Deep tendon reflexes
- Neuroimaging (CT/MRI)
  - › Indicated for red flag symptoms
  - › Majority of pediatric headache not warranted
- Electroencephalography (EEG)
  - › If associated alteration of consciousness or abnormal involuntary movement
  - › Nonspecific abnormalities and benign epileptiform discharges common in children with migraine
- Lumbar puncture
  - › Febrile, nuchal rigidity, no alteration of consciousness, signs of increased ICP, lateralizing features
  - › Subarachnoid hemorrhage, meningitis, pseudotumor cerebri, or neuroborreliosis
    - Measure opening pressure
  - › Cranial imaging prior to lumbar puncture
    - AMS, focal findings, high ICP
    - Blood cultures & antibiotic prior to neuroimaging

# Headache – Differential Diagnoses

- Acute headache <sup>[Lewis]</sup>
  - › URI
  - › Sinusitis
  - › Pharyngitis
  - › Meningitis
  - › Migraine
  - › Hypertension
  - › Substance use (e.g., cocaine)
  - › Medication (stimulants, OCP, steroids)
  - › Intoxicants (e.g., lead, CO)
  - › Ventriculoperitoneal shunt malfunction
  - › Brain tumor
  - › Hydrocephalus
  - › Subarachnoid hemorrhage
  - › Intracranial hemorrhage
- Chronic progressive headache
  - › Brain tumor
  - › Hydrocephalus
  - › Pseudotumor cerebri
  - › Brain abscess
  - › Hematoma
    - Chronic subdural
  - › Vascular malformations
    - Aneurism
  - › Medications & Supplements
    - OCPs
    - Tetracycline
    - Post Feverfew Syndrome\*
    - Vitamin A (high dose)
  - › Intoxication (Lead Poisoning, etc.)

# Headache – Pediatric Migraine

## Diagnostic Criteria for Pediatric Migraine

- Last 1 to 48 hours (shorter duration in adults)
- Have at least 2 of the following features:
  - › Bilateral or unilateral (frontal/temporal) location
  - › Pulsating quality
  - › Moderate to severe intensity
  - › Aggravated by routine physical activities
- Are accompanied by at least one of the following:
  - › Nausea and/or vomiting
  - › Photophobia and/or phonophobia

# Headache – Pediatric Migraine

- Prophylactic Medications
    - › NSAIDs
      - Naproxen
    - › Antihistamine
      - Cyproheptidine
    - › Antidepressants
      - Amitriptyline
    - › Anticonvulsants
      - Valproic acid
      - Carbamazepine
      - Topiramate
    - › Beta Antagonists
      - Propranolol
      - Metoprolol
    - › Monoclonal Antibodies
      - Calcitonin gene-related peptide
        - Eptinezumab
        - Fremanezumab
        - Galcanezumab
      - CGRP receptor
        - Erenumab
    - › Botulinum Toxin
- Abortive Medications
    - › 1<sup>st</sup> line
      - NSAIDs
      - Acetaminophen
    - › Triptans
      - Sumatriptan
      - Almotriptan
      - Rizatriptan
      - Zolmitriptan
    - › Dihydroergotamine

# Headache – Differential Diagnoses

## Post Feverfew Syndrome<sup>[Miller]\*</sup>

- Supplement used for migraine prophylaxis
- Abrupt discontinuation use after chronic administration resulting in:
  - › Headaches
  - › Insomnia
  - › Joint pain
  - › Nervousness
  - › Poor sleep patterns
  - › Stiffness
  - › Tension
  - › Tiredness
  - › Muscle and joint stiffness



## Headache – Red Flag Symptoms

- Age < 3yo
- Persistent vomiting
- Focal neurological signs or abnormal neurological examination
- Papilledema
- Abnormal ocular movements
- Hemiparesis
- Presence of VP shunt
- Presence of neurocutaneous syndrome (NF or tuberous sclerosis)
- Meningeal signs
- Unexplained fever
- Increased ICP
- Changes in behavior or mental status
- Sudden onset or severe headaches
- Thunderclap headaches
- Chronic progressive pattern
- Meningeal signs
- Headache or vomiting on awakening
- Headaches awaken patient from sleep

# Pediatric Pain Medicine - Management Modalities

- Medications
  - › COX Inhibitors
  - › Antidepressants
    - Amitriptyline [Saps, Huber, Kaminski]
  - › Anticonvulsants
    - Gabapentin
    - Pregabalin
  - › Opioids
    - Typically avoided
- Interventions
  - › Etiology-guided
- Behavioral Medicine
  - › Motivational Interviewing\*
  - › CBT
  - › Self Efficacy\*

# Pediatric Pain Medicine - Management Modalities

- Behavioral Medicine
  - › CBT
    - Focuses on improving emotional regulation by challenging & changing unhelpful cognitive distortions
    - "Problem-focused" and "action-oriented"
      - Therapist's role is active; assists patient in finding and practicing effective strategies to address the identified goals and decrease symptoms of the disorder
    - Based on concept that thought distortions & maladaptive behaviors play a role in the development and maintenance of pathology
  - › Motivational Interviewing\*
  - › Self Efficacy\*

# Pediatric Pain Medicine - Management Modalities

- Behavioral Medicine
  - › CBT
  - › Motivational Interviewing\*
    - Directive, client-centered counseling style for eliciting changes in behavior
    - Focuses on exploration and resolution of ambivalence
    - Focused and goal-directed
      - Therapist attempts to influence change, rather than engaging in non-directive therapeutic exploration
  - › Self Efficacy\*

# Pediatric Pain Medicine - Management Modalities

- Behavioral Medicine
  - › Cognitive Behavioral Therapy
  - › Motivational Interviewing\*
  - › Self Efficacy\*
    - An individual's belief in their innate ability to achieve goals
      - Determines one's ability to demonstrate and sustain the use of coping behaviors
    - High self-efficacy individuals exert sufficient effort→successful outcomes
    - Low self-efficacy individuals discontinue efforts early→failure
    - Marked impact with regard to behaviors affecting health<sup>[Luszczynska]</sup>

# Questions



# Bibliography

- AGHILI, MAHDI, ET AL. "EFFICACY OF GABAPENTIN FOR THE PREVENTION OF PACLITAXEL INDUCED PERIPHERAL NEUROPATHY: A RANDOMIZED PLACEBO CONTROLLED CLINICAL TRIAL." *THE BREAST JOURNAL*, VOL. 25, NO. 2, 2019, PP. 226–231., DOI:10.1111/TBJ.13196.
- AMERICAN ACADEMY OF PEDIATRICS. "EVIDENCE-BASED MANAGEMENT OF SICKLE CELL DISEASE: EXPERT PANEL REPORT, 2014." *PEDIATRICS*, VOL. 134, NO. 6, 2014, DOI:10.1542/PEDS.2014-2986.
- AMERICAN PSYCHIATRIC ASSOCIATION. *DIAGNOSTIC AND STATISTICAL MANUAL OF MENTAL DISORDERS, FIFTH EDITION (DSM-5)*, AMERICAN PSYCHIATRIC ASSOCIATION, ARLINGTON 2013.
- ARGYRIOU, A. A., ET AL. "EFFICACY OF OXCARBAZEPINE FOR PROPHYLAXIS AGAINST CUMULATIVE OXALIPLATIN-INDUCED NEUROPATHY." *NEUROLOGY*, VOL. 67, NO. 12, 2006, PP. 2253–2255., DOI:10.1212/01.WNL.0000249344.99671.D4.
- CAMERON DM, BRENNAN TJ, GEBHART GF. HIND PAW INCISION IN THE RAT PRODUCES LONG-LASTING COLON HYPERSENSITIVITY. *J PAIN*. 2008 MAR;9(3):246–53.
- EVIDENCE-BASED MANAGEMENT OF SICKLE CELL DISEASE: EXPERT PANEL REPORT, 2014. *PEDIATRICS*. 2014;134:E1775.
- GONZALEZ ER, BAHAL N, HANSEN LA, WARE D, BULL DS, ORNATO JP, ET AL. INTERMITTENT INJECTION VS PATIENT-CONTROLLED ANALGESIA FOR SICKLE CELL CRISIS PAIN. COMPARISON IN PATIENTS IN THE EMERGENCY DEPARTMENT. *ARCH INTERN MED*. 1991;151(7):1373-8.
- HUBER AM, TOMLINSON GA, KOREN G, FELDMAN BM. AMITRIPTYLINE TO RELIEVE PAIN IN JUVENILE IDIOPATHIC ARTHRITIS: A PILOT STUDY USING BAYESIAN META ANALYSIS OF MULTIPLE N-OF-1 CLINICAL TRIALS. *J RHEUMATOLOGY*. 2007;34:1125-32.
- KAMINSKI A, KAMPER A, THALER K, CHAPMAN A, GARTLENER G. ANTIDEPRESSANTS FOR THE TREATMENT OF ABDOMINAL PAIN RELATED FUNCTIONAL GASTROINTESTINAL DISORDERS IN CHILDREN AND ADOLESCENTS. *CHOCCHRANE DATABASE SYST REV*. 2011;(6):CD008013.
- LEWIS, DW, "HEADACHES IN CHILDREN AND ADOLESCENTS." EASTERN VIRGINIA MEDICAL SCHOOL, NORFOLK, VIRGINIA. *AMERICAN FAMILY PHYSICIAN*. 2002 FEB 15;65(4):625-633.
- MILLER, LG. "HERBAL MEDICINALS: SELECTED CLINICAL CONSIDERATIONS FOCUSING ON KNOWN OR POTENTIAL DRUG-HERB INTERACTIONS." *ARCH INTERNAL MEDICINE*. 1998 Nov 9; 158(20):2200-11.
- REUST, CE, WILLIAMS, A. ACUTE ABDOMINAL PAIN IN CHILDREN. *AMERICAN FAMILY PHYSICIAN*. 2016 MAY 15;93(10):830-837.
- SAPS M, YOUSSEF N, MIRANDA A, ET AL. MULTICENTER, RANDOMIZED, PLACEBO-CONTROLLED TRIAL OF AMITRIPTYLINE IN CHILDREN WITH FUNCTIONAL GASTROINTESTINAL DISORDERS. *GASTROENTEROLOGY*. 2009. 137:1261-9.
- SMITH, ELLEN M. LAVOIE, ET AL. "EFFECT OF DULOXETINE ON PAIN, FUNCTION, AND QUALITY OF LIFE AMONG PATIENTS WITH CHEMOTHERAPY-INDUCED PAINFUL PERIPHERAL NEUROPATHY." *JAMA*, VOL. 309, NO. 13, 2013, P. 1359., DOI:10.1001/JAMA.2013.2813.
- VAN BEERS EJ, VAN TUIJN CF, NIEUWKERK PT, FRIEDERICH PW, VRANKEN JH, BIEMOND BJ. PATIENT- CONTROLLED ANALGESIA VERSUS CONTINUOUS INFUSION OF MORPHINE DURING VASO-OCCLUSIVE CRISIS IN SICKLE CELL DISEASE, A RANDOMIZED CONTROLLED TRIAL. *AM J HEMATOL*. 2007;82(11):955-60.