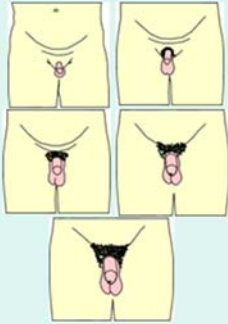


## Scavenger Hunt for Teen Clinic Wisdom

1. Your 16 yo male patient calls clinic and says that his condom broke last night and he needs to get emergency contraception for his girlfriend who is also 16.
  - Where should he go and how much does it cost?
  - Does he need a rx? Or does she need a rx?
  - Where can your patients(or you) go for info on emergency contraception?  
Search tips: <http://ec.princeton.edu/get-EC-now.html>, and <http://bedsider.org/>, and <http://www.plannedparenthood.org/health-topics/emergency-contraception-morning-after-pill-4363.asp>
2. Find the orchimeter (usually in the upper cabinet closest to the workroom door).
  - Which testicular volume lets you know a patient has progressed to genital Tanner stage (sexual maturity rating) 2?
  - Review male genital and pubic hair Tanner staging
  - Find a landmark on your hand that equals 4cc in volume or 2.5 cm in length to help you with tanner staging in the future.  
Search tips: *Flip over this page*
3. A 15 yo female is here for a sports physical. She plans to join the cross country team this fall. She is smoking about 5 cigarettes per day but states “I am not a cigarette addict or anything, I could quit right now if I wanted to. I only smoke the blackberry kind because they taste hella good.” She also reports alcohol use on a regular basis.
  - You remember a technique called “motivational interviewing” and you bet it would come in handy right now. Where can you review how to do that?
  - What is a good screening tool for adolescent substance use?
  - Should this patient switch to e cigarettes?  
Search Tips:  
Google these articles: <https://pubs.niaaa.nih.gov/publications/Practitioner/YouthGuide/AAPAdolescentHealthUpdateBMI.pdf>, [http://www.ceasar-boston.org/CRAFFT/pdf/CRAFFT\\_English.pdf](http://www.ceasar-boston.org/CRAFFT/pdf/CRAFFT_English.pdf), <https://www.aap.org/en-us/about-the-aap/aap-press-room/pages/Tobacco-and-E-Cigarettes.aspx>
4. Your 15 yo female patient is having sex with her 18 yo male partner. After discussing the relationship, you do not have concerns about abuse or coercion.
  - Are you mandated to report to CPS or the police due to the age difference?
  - She is interested in starting on the Nuva Ring, but doesn't want her parents to know. How should you handle this?  
Search Tips: <http://ahwg.net/wp-content/uploads/2017/07/Minor-Consent-and-Confidentiality-Module-2010-Version.pdf> (particularly pages A-8 and A-2)
5. A 14 yo male soccer player presents to the clinic after spraining his ankle during his soccer game this afternoon.
  - How will you decide if an xray is needed? And what is the best way to manage an ankle sprain?  
Search Tips: <http://www.aafp.org/afp/2012/0615/p1170.html>
6. After getting back a positive chlamydia test on a patient, you call her to share the news. She is allergic to amoxicillin (caused a severe rash) and some medication starting with a “D” that was used to treat her acne (caused a lot of vomiting).
  - How will you treat her infection? Can you treat her partner(s)?  
Search Tips: <http://www.cdc.gov/std/treatment/>

## Males

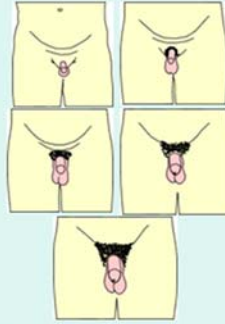
### Tanner Staging: Genital



- **Tanner 1:** prepubescent
- **Tanner 2:** enlargement of testes (>2.5cm length, 4cc volume)
- **Tanner 3:** penis grows in length and scrotum enlarges (sperm production)
- **Tanner 4:** scrotal darkening, penis grows in width
- **Tanner 5:** adult size penis and testes

## Males

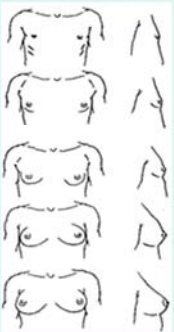
### Tanner Staging: Pubic Hair



- **Tanner 1:** no hair
- **Tanner 2:** sparse, slightly pigmented at base of penis
- **Tanner 3:** pigmentation increases, hair curls
- **Tanner 4:** coarsening of hair, adult distribution
- **Tanner 5:** spread to medial thigh

## Females

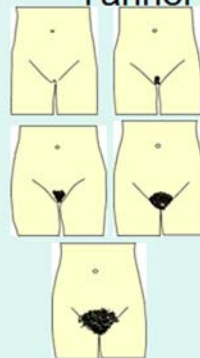### Tanner Staging: Thelarche



- **Tanner 1:** elevated papilla
- **Tanner 2:** breast buds
- **Tanner 3:** enlargement of breast bud and areola
- **Tanner 4:** areola and papilla separate from contour of breast to form a secondary mound
- **Tanner 5:** areola recedes, mature breast

## Females

### Tanner Staging: Pubic Hair



- **Tanner 1:** no hair
- **Tanner 2:** sparse, slightly pigmented at border of labia
- **Tanner 3:** pigmentation increases, hair curls, spreads to mons pubis
- **Tanner 4:** coarsening of hair, adult distribution
- **Tanner 5:** spread to medial thigh