

Vesicoureteral Reflux

Larry A. Greenbaum, MD, PhD^{a,*},
Hrair-George O. Mesrobian, MD, MSc^b

^a*Division of Pediatric Nephrology, Emory University School of Medicine,
Children's Healthcare of Atlanta, 2015 Uppergate Drive NE, Atlanta, GA 30322, USA*

^b*Medical College and Children's Hospital of Wisconsin, Corporate Center, Suite C 330,
999 North 92nd Street, Milwaukee, WI 53226, USA*

Vesicoureteral reflux (VUR) is the abnormal retrograde flow of urine from the bladder into the ureter and possibly the kidney. The severity of reflux is expressed as a grade, which is based on the system established by the International Reflux Study in Children [1]:

- Grade I: VUR does not reach the renal pelvis.
- Grade II: VUR extends up to the renal pelvis without dilation.
- Grade III: Mild or moderate dilation of the ureter and the renal pelvis. No or slight blunting of the fornices.
- Grade IV: Moderate dilation of the ureter, renal pelvis, and calyces. Complete obliteration of the sharp angle of the fornices but maintenance of the papillary impression in most calyces.
- Grade V: Gross dilation and tortuosity of the ureter. Gross dilation of the renal pelvis and calyces. The papillary impressions are not visible in most calyces.

VUR is secondary when high pressure in the bladder causes a breakdown of the normal antireflux mechanism at the ureterovesicular junction, which may occur in children with posterior urethral valves or neurogenic bladders. Secondary reflux also occurs in children who have complete ureteral duplication. This article focuses on primary VUR, which is caused by a congenital abnor-

* Corresponding author.

E-mail address: Larry_Greenbaum@oz.ped.emory.edu (L.A. Greenbaum).

mality at the ureterovesicular junction. Even in primary disease, however, increased bladder pressure may play a role in causing VUR in some patients [2].

Epidemiology and genetics

VUR is believed to be present in 1% or less of normal children, although the incidence is likely to vary depending on the age of screening because VUR often resolves over time (see later discussion). Most cases of VUR are diagnosed after occurrence of a urinary tract infection (UTI) [3]. In children with UTIs, the reported frequency of VUR varies from 20% to 40% [4–7]. Pediatric clinical practice guidelines recommend screening children for VUR after a UTI [8,9]. Boys and girls are equally likely to have VUR after a UTI, but boys are more likely to have higher grade VUR [6]. Girls are more commonly diagnosed with VUR because they are more likely to have a UTI [10].

The widespread use of prenatal ultrasound has led to more frequent detection of antenatal hydronephrosis. When screened, approximately 10% to 20% of these children have VUR [11–13]. VUR may be present despite a normal postnatal ultrasound [11]. Patients who have prenatally detected VUR have higher grade VUR than children detected after a UTI. Approximately 80% of these infants are boys, and a significant percentage have associated severe renal damage (see later discussion) [11,14]. These children, perhaps because of the male predominance, are at less risk for developing subsequent UTIs than children who are diagnosed with VUR after a UTI [15].

There is a genetic predisposition to VUR, with some studies suggesting an autosomal dominant inheritance with variable penetrance, although no specific genetic loci has been defined [7,16]. This finding is dramatically illustrated by the high incidence of reflux in siblings and offspring of patients who have VUR [17,18], which has led to the recommendation of screening children who have a first-degree relative with VUR [19,20].

Clinical manifestations

VUR is associated with two related consequences: UTI and renal scarring. The management of VUR is based on preventing these sequelae. Children who have a UTI have a high incidence of VUR [4–7], which indicates that VUR predisposes patients to UTI. Children who have a UTI and VUR are more likely to have evidence of renal involvement, as demonstrated by a nuclear scan, than children without VUR who have a UTI [21].

Reflux nephropathy is the term used to describe the association between renal scarring and VUR. Children with reflux are more likely to develop scarring after a UTI, probably because of the increased risk of renal involvement [22]. More frequent UTIs increase the risk of renal scarring [22]. Among children with VUR, some may be predisposed to scar formation because of a genetic susceptibility

[23]. The principal complications of renal scarring are chronic renal failure and hypertension [24–26].

Two distinct patient populations have renal damage associated with VUR. The first group develops renal scars after UTIs. This group most commonly presents during infancy or early childhood after occurrence of a UTI; it is composed predominantly of girls. In contrast, the second group frequently has bilateral disease, presents at a younger age, and comprises mostly boys [27–30]. This second group, often diagnosed after a prenatal ultrasound that demonstrates hydronephrosis, has congenital renal damage, which is probably secondary to renal maldevelopment rather than a direct effect of reflux or UTIs [28,31,32]. The renal damage in the second group is typically global, whereas the first group tends to have focal scars [30,33]. VUR in the second group is almost always high grade, which contrasts with the more variable severity of VUR in the first group [27].

A high percentage of children who have chronic renal failure caused by reflux nephropathy have congenital renal damage unrelated to UTIs [34]. The importance of damage from UTIs in children with VUR as a cause of chronic renal failure may have decreased because of the current emphasis on preventing UTIs in these patients [10,35]. Scar formation in children with VUR after UTIs is an important cause of secondary hypertension and can cause chronic renal failure [7]. Although younger children are more susceptible, renal scar formation after a UTI does occur in older children [36,37]. Risk factors for renal scar formation include higher grade VUR [38] and delay in UTI diagnosis and treatment [36,39]. The use of prophylactic antibiotics to prevent UTIs also may decrease the risk of scar formation (see later discussion).

Diagnosis

A voiding cystourethrogram (VCUG) is the standard diagnostic approach, with the advantages of allowing grading of VUR and providing excellent anatomic details. A VCUG is able to diagnose posterior urethral valves and bladder abnormalities. The disadvantages include radiation exposure and the need for catheterization. In contrast, direct radionuclide cystography, which also requires catheterization, has excellent sensitivity for detecting VUR and a much lower radiation exposure than a VCUG [40]. Because direct radionuclide cystography does not provide precise grading or anatomic detail (such as diagnosis of posterior urethral valves), it is usually reserved for follow-up investigations.

Natural history

VUR spontaneously resolves in most patients [41], probably secondary to an increase in the intramural length of the ureter caused by normal growth. The grade of reflux is the most important predictor of outcome; higher grade reflux is less likely to resolve [41].

The reported rate of VUR resolution varies, probably because of patient selection and study design. For grades I and II, reflux eventually ceases in more than 80% of affected ureters, with a resolution rate of 10% to 25% per year [6,38,41]. Grade III reflux resolves in more than 50% of cases, and grade IV VUR resolves in approximately 30% of cases [38,42–44]. Grade V reflux is unlikely to resolve spontaneously [43,44].

In a study from Sweden, 50% of children with grades I, II, and III–V VUR were free from reflux in 2, 5, and 8 years, respectively [6]. Given the questionable significance of grade I VUR, this study also examined the rate of grades II–V VUR reaching the endpoint of either no reflux or grade I reflux. This endpoint occurred in 83% of children with grade II VUR and in 73% of children with grades III–V VUR [6].

In one report, reflux was slower to resolve in girls than in boys [6], but another study showed a trend toward slower resolution in boys [45]. VUR resolves faster in children diagnosed before 1 year of age [46], and reflux that is diagnosed based on an abnormal prenatal ultrasound has an increased likelihood to resolve, even when it is grade IV or V [47,48]. One study suggested that VUR is less likely to resolve when diagnosed after age 7 years [43], and another study argued that the longer VUR has been present, the less likely it is to resolve [49]. In contrast, other studies proposed that the age at which VUR is diagnosed does not affect the likelihood that VUR will resolve [6,41]. Bilateral reflux resolves at a slower rate than unilateral reflux [49]. Resolution of reflux is decreased in children with severe scarring [41] or duplex systems [6]. Children who have bladder dysfunction are at increased risk for UTIs and persistence of VUR [50]. In many patients, a decrease in reflux severity precedes resolution of VUR.

Traditionally, follow-up imaging for VUR resolution has occurred yearly. A recent analysis recommended a less aggressive approach, however, with imaging every 2 years in children with grades I and II VUR and children younger than 2 years old who have unilateral grade III. Older children with grade III and all children with grade IV VUR should be imaged every 3 years [51]. This recommendation is based on the relatively slow rate of VUR resolution, balanced with the morbidity and cost of repeated imaging studies compared with the side effect of long-term antibiotic prophylaxis.

Medical management

Because VUR has a high rate of spontaneous resolution, conservative non-operative treatment of VUR grades I–III is the standard initial approach. The goal is to prevent UTIs and consequent renal scarring until the VUR resolves. Randomized studies have shown that prophylactic antibiotics are effective in preventing UTIs in children [52,53]. Observational studies suggest that children who have VUR managed with prophylactic antibiotics have a low risk of subsequent renal scarring [3,41]. Options for prophylactic antibiotics, which are given as once daily doses, include amoxicillin (10–15 mg/kg) or cephalexin

(15 mg/kg) in neonates and nitrofurantoin (1–2 mg/kg) or trimethoprim-sulfamethoxazole (2 mg/kg) in older children. Dosing immediately before sleep allows the antibiotic to remain in the bladder throughout the night. The presence of UTIs despite prophylactic antibiotics does not seem to influence the rate of VUR resolution [41,49]. There is disagreement about the need for routine antibiotic prophylaxis in children who have grade I–II VUR [8,54].

There is clearly a subset of patients with primary VUR who have dysfunctional voiding [55]. Symptoms may include urgency, diurnal enuresis, frequency, and urine holding behavior. Associated constipation and stool holding also may be present. In such children, VUR is more likely to improve with correction of the dysfunctional voiding [56].

Children who have grade V VUR should have surgical repair because of the low rate of spontaneous resolution and the increased risk of renal scar formation. The only exception involves children who have grade V VUR detected during an abnormal prenatal ultrasound. Even grade V VUR may resolve spontaneously in such patients. The approach to grade III–IV has been addressed by the International Reflux Study in Children, which randomized children to operative repair or long-term antibiotic prophylaxis. There was no difference in scar formation between the two groups [57]. Medical management of grade III–IV VUR is a reasonable option, with the caveat that surgical repair is indicated for children with recurrent UTIs—either secondary to breakthrough infections or non-adherence—or is based on parental preference.

Patients usually remain on prophylactic antibiotics until VUR resolves. Direct radionuclide cystography is an excellent option for follow-up imaging because there is less radiation burden than a VCUG. In some children, VUR does not resolve despite years of observation. Options then include surgical repair or discontinuation of prophylactic antibiotics. Surgical repair is especially appealing in children who continue to have breakthrough infections despite use of prophylactic antibiotics. It is also clear that a subset of older children do well with discontinuation of prophylactic antibiotics despite the continued presence of VUR [58,59].

Surgical evaluation and treatment of vesicoureteral reflux

Historically, surgical treatment was reserved for children with VUR who experienced breakthrough UTIs. Medical therapy was considered to have failed these children. The risk of recurrent episodes of pyelonephritis, its morbidity, and long-term consequences were cited as justification for embarking on a surgical approach. The results of open surgery for the repair of primary VUR approach a 98% success rate [60].

In 1984, O'Donnell and Puri [61] reported on endoscopic injection therapy for primary VUR. In the pioneering report, 13 girls with grade III–IV VUR were treated by endoscopic injection of polytetrafluoroethylene paste behind the intravesicular ureter. This procedure was performed on an outpatient basis with mini-

mal morbidity and a success rate approaching that of open surgery. Because polytetrafluoroethylene paste was shown to migrate to the retroperitoneum, the lungs, and even the brain, it was not adopted in the United States [62]. The endoscopic approach has been resurrected recently, with the US Food and Drug Administration having approved dextranomer/hyaluronic acid copolymer (dextranomer microspheres and hyaluronic acid) for this purpose in 2001. Because of its safety, low morbidity and high success rate, the endoscopic approach has expanded the indications for surgical treatment. Open surgery is reserved for patients who have complex VUR or patients in whom endoscopic therapy has failed or is technically not feasible. In this section on the surgical treatment of VUR, we present briefly the most effective open surgical procedures and our current state of knowledge regarding endoscopic injection therapy.

Classic open surgical procedures

Open surgery involves repositioning the ureter in the bladder in such a manner as to achieve a 5:1 ratio between its submucosal length and the width. The two main approaches differ with respect to whether the bladder is opened (intravesical) or not (extravesical). The latter approach is associated with less morbidity, but its success depends on the experience of the surgeon. The refluxing ureter is dissected extravesically and reimplanted in a trough created by separating the muscularis and exposing the bladder mucosa (Fig. 1). The distal portion is advanced and immobilized toward the bladder neck. The muscularis is then reapproximated over the ureter (Fig. 2) [63]. Patients may be discharged 1 or 2 days postoperatively.

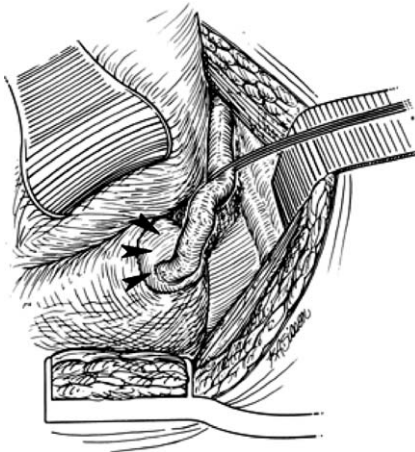


Fig. 1. Ureterovesical junction. Creation of mucosal trough where the ureter will reside. Arrows indicate uretero-vesical junction, which is dissected extravesicularly.

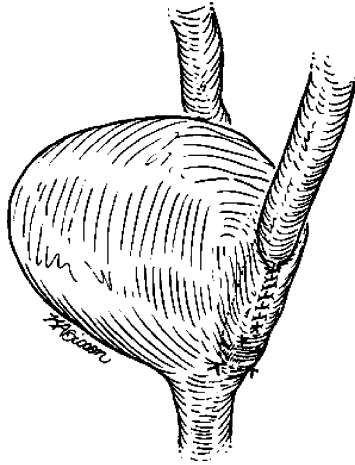


Fig. 2. Ureter reimplanted in mucosal trough.

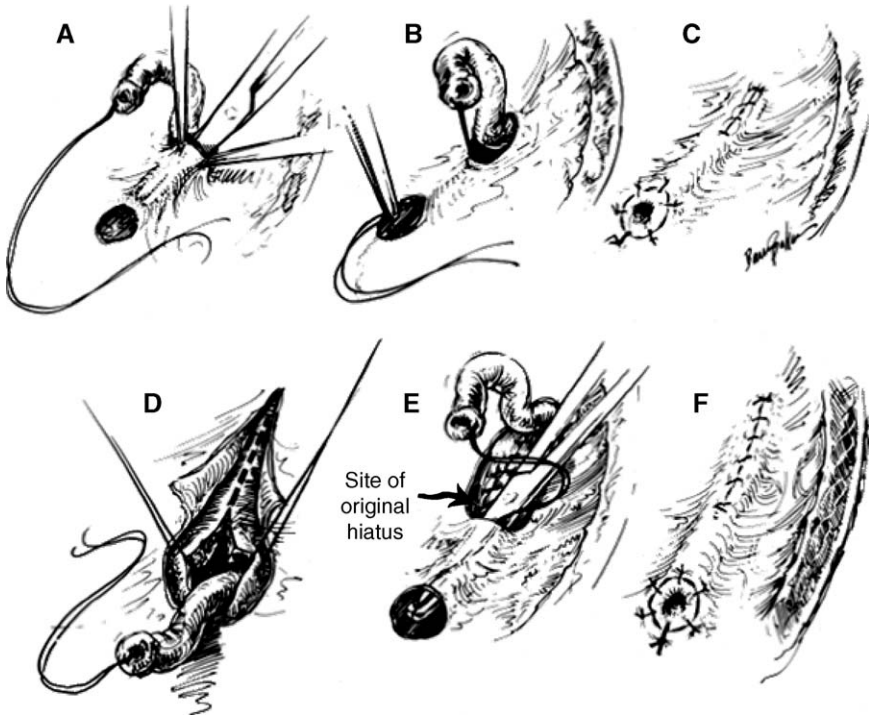


Fig. 3. (A-F) Intravesical correction of vesicoureteral reflux. See further discussion in text.

Intravesical procedures rely on creating a submucosal tunnel either by using the same hiatus and advancing the ureter or creating a new hiatus. The success rate approaches 98%. The most serious complication consists of ureterovesical junction obstruction that may require a reoperation [64]. Fig. 3 is an illustration of a common procedure. After intravesical mobilization of the ureter, a submucosal tunnel is created (Fig. 3A). The mobilized ureter is drawn into the tunnel (Fig. 3B) and the orifice is sutured to the bladder (Fig. 3C). A new hiatus may be created when the length of the submucosal tunnel must be increased. One method of creating a new hiatus is illustrated in Fig. 3D–F.

Endoscopic injection therapy

Characteristics of deflux

Deflux is a viscous gel that consists of dextranomer microspheres and non-animal-derived hyaluronic acid that serves to stabilize the microspheres [65]. Both constituents are biocompatible and have been shown not to migrate. Deflux is stabilized at the injection site by a mild inflammatory response that consists of macrophages, lymphocytes, and giant cells [66], which is a foreign body type of inflammatory response and has been shown to be nonimmunogenic. The extent of the reaction is not sufficient to produce fibrosis and does not preclude a successful open surgical procedure should Deflux injection fail to correct VUR. Ultimately, the hyaluronic acid component of Deflux is degraded and replaced by a matrix of collagen that continues to stabilize the microspheres. Of significance is the observation that the implant volume does decrease over time by approximately 20% [67]. This observation has important implications for the technique of implantation of the dextranomer under refluxing ureters.

Description of the procedure

The procedure is performed under general anesthesia. Deflux is injected through a special needle under direct vision (Fig. 4). The needle is inserted

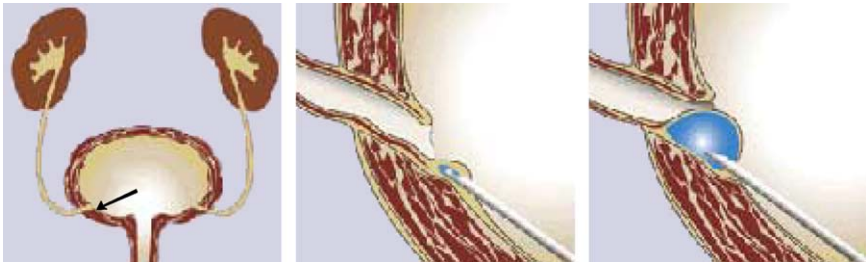


Fig. 4. The original technique of endoscopic injection therapy. Arrow points at needed position in relation to ureteral orifice (*middle*).

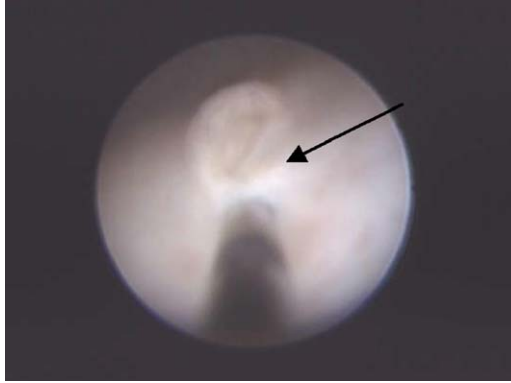

Fig. 5. Refluxing ureteral orifice being injected with dextranomer/hyaluronic acid copolymer. Arrow points to ureteral orifice. Note intraureteral placement of needle and injection.

submucosally just in front of the refluxing ureter and advanced to an intraluminal position. Sufficient Deflux is injected to create a volcano-shaped mound that converts the orifice to a crescent shape. We inject additional Deflux in front of the mound and posteriorly to stabilize the intraluminal component further (Fig. 5). In our practice, we perform a positional intraoperative cystogram after satisfactory visual injection [68]. If residual VUR is detected, additional Deflux is implanted and the intraoperative cystogram is repeated. The average volume of implanted Deflux is 0.4 mL. The procedure rarely exceeds 30 minutes, and the patient is discharged home within 1 hour of recovery. We routinely use phenazopyridine perioperatively and encourage toilet-trained children to void every 2 hours to minimize bladder distention. Antibiotic prophylaxis is maintained when indicated, and a VCUG is obtained 3 months after injection.

A modification of this technique was described recently, with significant improvement in the results [69]. The refluxing ureter is hydrodistended, which

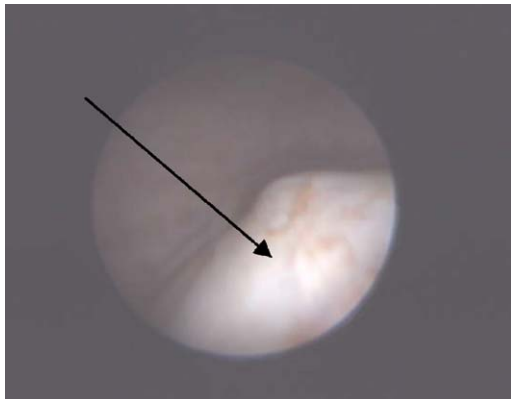


Fig. 6. Dextranomer/hyaluronic acid copolymer mound appearance (arrow) after injection.

allows for Deflux to be implanted along most of the submucosal tunnel (intraureteral). The adequacy of the injection is gauged by the resolution of the hydrodistention, which frequently results in the ureteral orifice acquiring a “grumpy” face appearance (Fig. 6). In addition to the technical refinement, we inject approximately 0.2 to 0.3 mL of Deflux anteriorly and laterally to the original mound to enhance its stability over time. The average volume of implanted Deflux is 1 mL.

Results

After surgical or endoscopic treatment, patients remain on prophylactic antibiotics until a follow-up VCUG is obtained 3 months later. An ultrasound study also may be obtained at that time. Recently, we used positional intraoperative cystography to assess the adequacy of the injection intraoperatively. Our preliminary results suggested a good correlation with the VCUG obtained at 3 months in carefully selected patients. If these findings are confirmed, a postoperative VCUG may not be required in all patients.

Open surgery in patients who have primary VUR results in a success rate that approaches 100% [60]. Recent advances in understanding of the anatomy and physiology of the vesicoureteral junction have led to modifications of the extravesical detrusorrhaphy (an extravesicular approach to the correction of VUR) [70,71]. The most recent study reported a 100% success rate in 50 patients who underwent bilateral extravesical detrusorrhaphy and were discharged the next day [72].

Kirsch and colleagues [73] recently reported an 89% cure rate with the modified hydrodistention implantation endoscopic technique. Although the success rate is lower than the open surgical procedures, so is the morbidity of the endoscopic approach. Failure of endoscopic correction does not preclude an open procedure later on. The Deflux is easily found and removed during open surgery.

Summary (surgical perspective)

With the advent of endoscopic therapy, the outlook for children who have VUR is improved. Early treatment obviates the need for antibiotic prophylaxis and lengthy follow-up, including the undesirable VCUG. The natural history of the disease is such that resolution takes an average of 5 years in children with lower grades of reflux and is less likely in children with higher grades of reflux [54]. The risk of a UTI during this lengthy period of time is significant in this patient population. Standard therapy consists of antibiotic prophylaxis while allowing time for VUR to resolve spontaneously. Although not all patients who have VUR are at risk for pyelonephritis, clinicians do not have the means to identify patients at risk, especially in infancy. All patients are placed on

prophylaxis and a VCUG is obtained periodically [51]. Patients, their parents, doctors, and radiology technicians have an aversion to this study. Sedation with oral midazolam has been shown to diminish the unfavorable impact of the VCUG [74]. These considerations, added to the low morbidity and high success rate of endoscopic treatment, have led to the proposal of a new treatment algorithm [75]. The proposed approach is based on the initial grade of VUR and age at presentation. Essentially, all patients (1–10 years of age) are treated initially with antibiotic prophylaxis. If at the end of 1 year VUR does not resolve, endoscopic therapy is recommended for patients with lower grades of reflux. A second injection may be attempted if the first one fails; otherwise reflux may be treated with open surgery. Patients with higher grades of reflux may be treated with open surgery from the outset.

The evaluation and treatment of primary VUR in children are evolving. Long-term follow-up and cost-effectiveness studies are required to define the optimal treatment strategy.

Prognosis

The long-term outcome of VUR is related directly to the degree of renal scarring [76]. Patients with renal scarring are at risk for hypertension and chronic renal failure [77]. Hypertension is more likely in patients with more extensive scarring and bilateral scarring [77]. The results of long-term follow-up studies suggest that the risk of hypertension in adults with scarred kidneys is approximately 20% [76,78]. Most adults with hypertension or chronic renal failure caused by renal scarring had evidence of renal dysfunction or elevated blood pressures as children [76].

Women with persistent VUR have an increased risk of pyelonephritis during pregnancy [79]. A high rate of UTIs during pregnancy also occurs in women who had surgical repair of VUR [76,80]. Renal scarring increases the risk of a complication during pregnancy [76], although the risk of serious complications seems to be low unless renal dysfunction is present [79,81].

References

- [1] Lebowitz RL, Olbing H, Parkkulainen KV, et al. International system of radiographic grading of vesicoureteric reflux. *International Reflux Study in Children. Pediatr Radiol* 1985;15(2):105–9.
- [2] Chandra M, Maddix H. Urodynamic dysfunction in infants with vesicoureteral reflux. *J Pediatr* 2000;136(6):754–9.
- [3] Greenfield SP, Ng M, Wan J. Experience with vesicoureteral reflux in children: clinical characteristics. *J Urol* 1997;158(2):574–7.
- [4] Jakobsson B, Soderlundh S, Berg U. Diagnostic significance of 99mTc-dimercaptosuccinic acid (DMSA) scintigraphy in urinary tract infection. *Arch Dis Child* 1992;67(11):1338–42.
- [5] Cleper R, Krause I, Eisenstein B, et al. Prevalence of vesicoureteral reflux in neonatal urinary tract infection. *Clin Pediatr (Phila)* 2004;43(7):619–25.

- [6] Wennerstrom M, Hansson S, Jodal U, et al. Disappearance of vesicoureteral reflux in children. *Arch Pediatr Adolesc Med* 1998;152(9):879–83.
- [7] Jacobson SH, Hansson S, Jakobsson B. Vesico-ureteric reflux: occurrence and long-term risks. *Acta Paediatr Suppl* 1999;88(431):22–30.
- [8] Jodal U, Lindberg U. Guidelines for management of children with urinary tract infection and vesico-ureteric reflux: recommendations from a Swedish state-of-the-art conference. *Swedish Medical Research Council. Acta Paediatr Suppl* 1999;88(431):87–9.
- [9] American Academy of Pediatrics. Practice parameter: the diagnosis, treatment, and evaluation of the initial urinary tract infection in febrile infants and young children. *Pediatrics* 1999;103(4):843–52.
- [10] Hansson S, Martinell J, Stokland E, et al. The natural history of bacteriuria in childhood. *Infect Dis Clin North Am* 1997;11(3):499–512.
- [11] Farhat W, McLorie G, Geary D, et al. The natural history of neonatal vesicoureteral reflux associated with antenatal hydronephrosis. *J Urol* 2000;164(3 Pt 2):1057–60.
- [12] Zerlin JM, Ritchey ML, Chang AC. Incidental vesicoureteral reflux in neonates with antenatally detected hydronephrosis and other renal abnormalities. *Radiology* 1993;187(1):157–60.
- [13] Jaswon MS, Dibble L, Puri S, et al. Prospective study of outcome in antenatally diagnosed renal pelvis dilatation [see comment]. *Arch Dis Child Fetal Neonatal Ed* 1999;80(2):F135–8.
- [14] Steele BT, De Maria J. A new perspective on the natural history of vesicoureteric reflux. *Pediatrics* 1992;90(1 Pt 1):30–2.
- [15] Ramage IJ, Schuckett B, McLorie GA, et al. Primary vesicoureteric reflux diagnosed in the 1st month of life. *Pediatr Nephrol* 1999;13(8):716–7.
- [16] Devriendt K, Groenen P, Van Esch H, et al. Vesico-ureteral reflux: a genetic condition? *Eur J Pediatr* 1998;157(4):265–71.
- [17] Jerkins GR, Noe HN. Familial vesicoureteral reflux: a prospective study. *J Urol* 1982;128(4):774–8.
- [18] Noe HN, Wyatt RJ, Peeden Jr JN, et al. The transmission of vesicoureteral reflux from parent to child. *J Urol* 1992;148(6):1869–71.
- [19] Scott JE, Swallow V, Coulthard MG, et al. Screening of newborn babies for familial ureteric reflux. *Lancet* 1997;350(9075):396–400.
- [20] Kaefer M, Curran M, Treves ST, et al. Sibling vesicoureteral reflux in multiple gestation births. *Pediatrics* 2000;105(4 Pt 1):800–4.
- [21] Rosenberg AR, Rossleigh MA, Brydon MP, et al. Evaluation of acute urinary tract infection in children by dimercaptosuccinic acid scintigraphy: a prospective study. *J Urol* 1992;148(5 Pt 2):1746–9.
- [22] Jakobsson B, Berg U, Svensson L. Renal scarring after acute pyelonephritis. *Arch Dis Child* 1994;70(2):111–5.
- [23] Ozen S, Alikasifoglu M, Saatci U, et al. Implications of certain genetic polymorphisms in scarring in vesicoureteric reflux: importance of ACE polymorphism. *Am J Kidney Dis* 1999;34(1):140–5.
- [24] Arar MY, Hogg RJ, Arant Jr BS, et al. Etiology of sustained hypertension in children in the southwestern United States. *Pediatr Nephrol* 1994;8(2):186–9.
- [25] Gill DG, Mendes de Costa B, Cameron JS, et al. Analysis of 100 children with severe and persistent hypertension. *Arch Dis Child* 1976;51(12):951–6.
- [26] Ardissino G, Dacco V, Testa S, et al. Epidemiology of chronic renal failure in children: data from the ItalKid project. *Pediatrics* 2003;111(4 Pt 1):e382–7.
- [27] Najmaldin A, Burge DM, Atwell JD. Reflux nephropathy secondary to intrauterine vesicoureteric reflux. *J Pediatr Surg* 1990;25(4):387–90.
- [28] Marra G, Barbieri G, Dell'Agnola CA, et al. Congenital renal damage associated with primary vesicoureteral reflux detected prenatally in male infants. *J Pediatr* 1994;124(5 Pt 1):726–30.
- [29] Assael BM, Guez S, Marra G, et al. Congenital reflux nephropathy: a follow-up of 108 cases diagnosed perinatally. *Br J Urol* 1998;82(2):252–7.
- [30] Yeung CK, Godley ML, Dhillon HK, et al. The characteristics of primary vesico-ureteric reflux in male and female infants with pre-natal hydronephrosis. *Br J Urol* 1997;80(2):319–27.

- [31] Sommer JT, Stephens FD. Morphogenesis of nephropathy with partial ureteral obstruction and vesicoureteral reflux. *J Urol* 1981;125(1):67–72.
- [32] Hinchliffe SA, Chan YF, Jones H, et al. Renal hypoplasia and postnatally acquired cortical loss in children with vesicoureteral reflux. *Pediatr Nephrol* 1992;6(5):439–44.
- [33] Crabbe DC, Thomas DF, Gordon AC, et al. Use of ^{99m}technetium-dimercaptosuccinic acid to study patterns of renal damage associated with prenatally detected vesicoureteral reflux. *J Urol* 1992;148(4):1229–31.
- [34] Marra G, Oppezzo C, Ardissino G, et al. Severe vesicoureteral reflux and chronic renal failure: a condition peculiar to male gender? Data from the ItalKid Project. *J Pediatr* 2004;144(5):677–81.
- [35] Esbjorner E, Berg U, Hansson S. Epidemiology of chronic renal failure in children: a report from Sweden 1986–1994. Swedish Pediatric Nephrology Association. *Pediatr Nephrol* 1997; 11(4):438–42.
- [36] Smellie JM, Ransley PG, Normand IC, et al. Development of new renal scars: a collaborative study. *BMJ* 1985;290(6486):1957–60.
- [37] Benador D, Benador N, Slosman D, et al. Are younger children at highest risk of renal sequelae after pyelonephritis? *Lancet* 1997;349(9044):17–9.
- [38] Arant Jr BS. Medical management of mild and moderate vesicoureteral reflux: followup studies of infants and young children. A preliminary report of the Southwest Pediatric Nephrology Study Group. *J Urol* 1992;148(5 Pt 2):1683–7.
- [39] Smellie JM, Poulton A, Prescod NP. Retrospective study of children with renal scarring associated with reflux and urinary infection. *BMJ* 1994;308(6938):1193–6.
- [40] Rothwell DL, Constable AR, Albrecht M. Radionuclide cystography in the investigation of vesicoureteric reflux in children. *Lancet* 1977;1(8021):1072–5.
- [41] Edwards D, Normand IC, Prescod N, et al. Disappearance of vesicoureteric reflux during long-term prophylaxis of urinary tract infection in children. *BMJ* 1977;2(6082):285–8.
- [42] Birmingham Reflux Study Group. Prospective trial of operative versus non-operative treatment of severe vesicoureteric reflux in children: five years' observation. *BMJ* 1987;295(6592): 237–41.
- [43] Huang FY, Tsai TC. Resolution of vesicoureteral reflux during medical management in children. *Pediatr Nephrol* 1995;9(6):715–7.
- [44] McLorie GA, McKenna PH, Jumper BM, et al. High grade vesicoureteral reflux: analysis of observational therapy. *J Urol* 1990;144(2 Pt 2):537–40.
- [45] Goldraich NP, Goldraich IH. Followup of conservatively treated children with high and low grade vesicoureteral reflux: a prospective study. *J Urol* 1992;148(5 Pt 2):1688–92.
- [46] Skoog SJ, Belman AB, Majd M. A nonsurgical approach to the management of primary vesicoureteral reflux. *J Urol* 1987;138(4 Pt 2):941–6.
- [47] Upadhyay J, McLorie GA, Bolduc S, et al. Natural history of neonatal reflux associated with prenatal hydronephrosis: long-term results of a prospective study. *J Urol* 2003;169(5):1837–41.
- [48] Steele BT, Robitaille P, DeMaria J, et al. Follow-up evaluation of prenatally recognized vesicoureteric reflux. *J Pediatr* 1989;115(1):95–6.
- [49] Tamminen-Mobius T, Brunier E, Ebel KD, et al. Cessation of vesicoureteral reflux for 5 years in infants and children allocated to medical treatment: the International Reflux Study in Children. *J Urol* 1992;148(5 Pt 2):1662–6.
- [50] van Gool JD, Hjalmas K, Tamminen-Mobius T, et al. Historical clues to the complex of dysfunctional voiding, urinary tract infection and vesicoureteral reflux: the International Reflux Study in Children. *J Urol* 1992;148(5 Pt 2):1699–702.
- [51] Thompson M, Simon SD, Sharma V, et al. Timing of follow-up voiding cystourethrogram in children with primary vesicoureteral reflux: development and application of a clinical algorithm. *Pediatrics* 2005;115(2):426–34.
- [52] Smellie JM, Katz G, Gruneberg RN. Controlled trial of prophylactic treatment in childhood urinary-tract infection. *Lancet* 1978;2(8082):175–8.
- [53] Lohr JA, Nunley DH, Howards SS, et al. Prevention of recurrent urinary tract infections in girls. *Pediatrics* 1977;59(4):562–5.
- [54] Elder JS, Peters CA, Arant Jr BS, et al. Pediatric vesicoureteral reflux guidelines panel summary

- report on the management of primary vesicoureteral reflux in children. *J Urol* 1997;157(5):1846–51.
- [55] Koff SA, Wagner TT, Jayanthi VR. The relationship among dysfunctional elimination syndromes, primary vesicoureteral reflux and urinary tract infections in children. *J Urol* 1998;160(3 Pt 2):1019–22.
- [56] Upadhyay J, Bolduc S, Bagli DJ, et al. Use of the dysfunctional voiding symptom score to predict resolution of vesicoureteral reflux in children with voiding dysfunction. *J Urol* 2003;169(5):1842–6.
- [57] Olbing H, Smellie JM, Jodal U, et al. New renal scars in children with severe VUR: a 10-year study of randomized treatment. *Pediatr Nephrol* 2003;18(11):1128–31.
- [58] Thompson RH, Chen JJ, Pugach J, et al. Cessation of prophylactic antibiotics for managing persistent vesicoureteral reflux. *J Urol* 2001;166(4):1465–9.
- [59] Cooper CS, Chung BI, Kirsch AJ, et al. The outcome of stopping prophylactic antibiotics in older children with vesicoureteral reflux [see comment]. *J Urol* 2000;163(1):269–72.
- [60] Kramer SA. Vesicoureteral reflux. In: Belman AB, King LR, Kramer SA, editors. *Clinical pediatric urology*. 4th edition. London: Martin Dunitz Ltd.; 2004. p. 749–810.
- [61] O'Donnell B, Puri P. Treatment of vesicoureteric reflux by endoscopic injection of Teflon. *Br Med J (Clin Res Ed)* 1984;289(6436):7–9.
- [62] Malizia Jr AA, Reiman HM, Myers RP, et al. Migration and granulomatous reaction after periurethral injection of polytetrafluoroethylene (Teflon). *JAMA* 1984;251(24):3277–81.
- [63] Zaoutz M. Vesicoureteral reflux. In: Graham SD, Keane TE, Glenn JF, editors. *Glenn's urologic surgery*. 6th edition. Philadelphia: Lippincott Williams & Wilkins; 2004. p. 753–65.
- [64] Mesrobian HG, Kramer SA, Kelalis PP. Reoperative ureteroneocystostomy: review of 69 patients. *J Urol* 1985;133(3):388–90.
- [65] Heel RC, Morton P, Brogden RN, et al. Dextranomer: a review of its general properties and therapeutic efficacy. *Drugs* 1979;18(2):89–102.
- [66] Stenberg A, Larsson E, Lindholm A, et al. Injectable dextranomer-based implant: histopathology, volume changes and DNA-analysis. *Scand J Urol Nephrol* 1999;33(6):355–61.
- [67] Kirsch AJ, Perez-Brayfield MR, Scherz HC. Minimally invasive treatment of vesicoureteral reflux with endoscopic injection of dextranomer/hyaluronic acid copolymer: the Children's Hospitals of Atlanta experience. *J Urol* 2003;170(1):211–5.
- [68] Rubenstein JN, Maizels M, Kim SC, et al. The PIC cystogram: a novel approach to identify "occult" vesicoureteral reflux in children with febrile urinary tract infections. *J Urol* 2003;169(6):2339–43.
- [69] Kirsch AJ, Perez-Brayfield M, Smith EA, et al. The modified sting procedure to correct vesicoureteral reflux: improved results with submucosal implantation within the intramural ureter. *J Urol* 2004;171:2413–6.
- [70] David S, Kelly C, Poppas DP. Nerve sparing extravesical repair of bilateral vesicoureteral reflux: description of technique and evaluation of urinary retention. *J Urol* 2004;172(4 Pt 2):1617–20.
- [71] Leissner J, Allhoff EP, Wolff W, et al. The pelvic plexus and antireflux surgery: topographical findings and clinical consequences [see comment]. *J Urol* 2001;165(5):1652–5.
- [72] McAchran SE, Palmer JS. Bilateral extravesical ureteral reimplantation in toilet trained children: is 1-day hospitalization without urinary retention possible? *J Urol* 2005;174(5):1991–3.
- [73] Kirsch AJ, Perez-Brayfield M, Smith EA, et al. The modified sting procedure to correct vesicoureteral reflux: improved results with submucosal implantation within the intramural ureter. *J Urol* 2004;171(6 Pt 1):2413–6.
- [74] Elder JS, Longenecker R. Premedication with oral midazolam for voiding cystourethrography in children: safety and efficacy. *AJR Am J Roentgenol* 1995;164(5):1229–32.
- [75] Stenberg A, Hensle TW, Lackgren G. Vesicoureteral reflux: a new treatment algorithm. *Curr Urol Rep* 2002;3(2):107–14.
- [76] Smellie JM, Prescod NP, Shaw PJ, et al. Childhood reflux and urinary infection: a follow-up of 10–41 years in 226 adults. *Pediatr Nephrol* 1998;12(9):727–36.
- [77] Zhang Y, Bailey RR. A long term follow up of adults with reflux nephropathy. *N Z Med J* 1995;108(998):142–4.

- [78] Jacobson SH, Eklof O, Eriksson CG, et al. Development of hypertension and uraemia after pyelonephritis in childhood: 27 year follow up. *BMJ* 1989;299(6701):703–6.
- [79] Martinell J, Jodal U, Lidin-Janson G. Pregnancies in women with and without renal scarring after urinary infections in childhood. *BMJ* 1990;300(6728):840–4.
- [80] Mansfield JT, Snow BW, Cartwright PC, et al. Complications of pregnancy in women after childhood reimplantation for vesicoureteral reflux: an update with 25 years of followup. *J Urol* 1995;154(2 Pt 2):787–90.
- [81] el-Khatib M, Packham DK, Becker GJ, et al. Pregnancy-related complications in women with reflux nephropathy. *Clin Nephrol* 1994;41(1):50–5.