

Evaluation of hematuria in children

Kevin E.C. Meyers, MBBCh

*Division of Nephrology, Department of Pediatrics, Children's Hospital of Philadelphia,
University of Pennsylvania School of Medicine, 34th Street and Civic Center Boulevard,
Main Building, 2nd Floor, Philadelphia, PA 19104-4399, USA*

The detection of even microscopic amounts of blood in a child's urine alarms the patient, parents, and physician, and often prompts the performance of many laboratory studies. Hematuria is one of the most important signs of renal or bladder disease, but proteinuria is a more important diagnostic and prognostic finding, except in the case of calculi or malignancies. Hematuria is almost never a cause of anemia. The physician should ensure that serious conditions are not overlooked, avoid unnecessary and often expensive laboratory studies, reassure the family, and provide guidelines for additional studies if there is a change in the child's course [1]. This article provides an approach to the evaluation and management of hematuria in a child [2,3]. Many tests have been recommended for the child with hematuria, but no consensus exists on a stepwise evaluation. Although more research is needed to resolve certain controversies in management, the suggested approach aims to detect major or treatable problems and limit the anxiety, cost, and energy required by unnecessary testing.

Definitions

Macroscopic hematuria is visible to the naked eye, but *microscopic* hematuria usually is detected by a dipstick test during a routine examination. Hematuria is confirmed by microscopic examination of the spun urine sediment. Microscopic examination is performed with concentration of the urinary sediment by centrifugation. Ten milliliters of urine is spun at 2000 rpm for 5 minutes.

Nine milliliters is decanted and the sediment is resuspended and an aliquot examined. The urine is examined by microscopy by high power field (hpf) that is 400× magnification. Macroscopic hematuria often does not require concentration. Bright-red urine, visible clots, or crystals with normal-looking red blood cells (RBCs) suggests bleeding from the urinary tract. Cola-colored urine, RBC casts, and deformed (dysmorphic) RBCs suggest glomerular bleeding [4]. An absence of RBCs in the urine with a positive dipstick reaction suggests hemoglobinuria or myoglobinuria.

The sensitivity and specificity of the dipstick method for detecting blood in the urine vary. When tested on urine samples in which a predetermined amount of blood has been placed, dipsticks have a sensitivity of 100 and a specificity of 99 in detecting one to five RBCs/hpf [5]. This corresponds to approximately 5 to 10 intact RBCs/μL urine [6]. There is no consensus on the definition of microscopic hematuria, although more than 5 to 10 RBCs/hpf is considered significant [7,8]. The author and others recommend that at least two of three urinalyses show microhematuria over 2 to 3 weeks before further evaluation is performed [3,9]. The American Academy of Pediatrics recommends a screening urinalysis at school entry (4–5 years of age) and once during adolescence (11–21 years of age) as a component of well child-care.

Incidence and prevalence

Pediatricians frequently encounter hematuria in children. Macroscopic hematuria has an estimated incidence of 1.3 per 1000 [2]. Microscopic hematuria, although more common than gross

E-mail address: meyersk@email.chop.edu

hematuria, has a variably reported incidence depending on the definition used for making the diagnosis. The incidence of microscopic hematuria in schoolchildren was estimated at 0.41% when four urine samples per child were collected and 0.32% in girls and 0.14% in boys when five consecutive urine specimens were analyzed over 5 years [10,11]. Microscopic hematuria in two or more urine samples is found in 1% to 2% of children 6 to 15 years of age.

Pathophysiology

Hematuria may originate from the glomeruli, renal tubules and interstitium, or urinary tract (including collecting systems, ureters, bladder, and urethra) (Boxes 1 and 2). In children, the source of bleeding is more often from glomeruli than from the urinary tract. RBCs cross the glomerular endothelial-epithelial barrier and enter the capillary lumen through structural discontinuities in the capillary wall. These discontinuities seem to be at the capillary wall–mesangial cell reflections [12]. In most cases, proteinuria, RBC casts, and deformed (dysmorphic) RBCs in the urine accompany hematuria caused by any of the glomerulonephritides. The renal papillae are susceptible to necrotic injury from microthrombi and anoxia in patients with a hemoglobinopathy or in those exposed to toxins. Patients with renal parenchymal lesions may have episodes of transient microscopic or macroscopic hematuria during systemic infections or after moderate exercise. This may be the result of renal hemodynamic responses to exercise or fever by undetermined mechanisms.

Initial evaluation

Macroscopic hematuria

The evaluation of a child with gross hematuria differs from that of microscopic hematuria (Fig. 1). Macroscopic hematuria of glomerular origin usually is described as brown, tea-colored, or cola-colored, whereas macroscopic hematuria from the lower urinary tract (bladder and urethra) is usually pink or red. Macroscopic hematuria in the absence of significant proteinuria or RBC casts is an indication for a renal and bladder ultrasound to exclude malignancy or cystic renal disease. Referral to a urologist is required when clinical evaluation and workup indicates that there is a tumor, a structural urogenital abnormality, or an obstructing calculus. A urologist also should

Box 1. Causes of hematuria in children

Glomerular diseases

Recurrent gross hematuria (IgA nephropathy, benign familial hematuria, Alport's syndrome)
 Acute poststreptococcal glomerulonephritis
 Membranoproliferative glomerulonephritis
 Systemic lupus erythematosus
 Membranous nephropathy
 Rapidly progressive glomerulonephritis
 Henoch-Schonlein purpura
 Goodpasture's disease

Interstitial and tubular

Acute pyelonephritis
 Acute interstitial nephritis
 Tuberculosis
 Hematologic (sickle cell disease, coagulopathies von Willebrand's disease, renal vein thrombosis, thrombocytopenia)

Urinary tract

Bacterial or viral (adenovirus) infection–related
 Nephrolithiasis and hypercalciuria
 Structural anomalies, congenital anomalies, polycystic kidney disease
 Trauma
 Tumors
 Exercise
 Medications (aminoglycosides, amitriptyline, anticonvulsants, aspirin, chlorpromazine, coumadin, cyclophosphamide, diuretics, penicillin, thiorazine)

evaluate children with recurrent nonglomerular macroscopic hematuria of undetermined origin because cystoscopy may be warranted.

Microscopic hematuria

Microscopic hematuria, defined by more than five RBCs/hpf, almost always warrants referral to a nephrologist rather than an urologist. Figs. 2 and 3 give an approach to the evaluation of asymptomatic and symptomatic microscopic

Box 2. Causes of asymptomatic isolated microscopic hematuria*Common*

Undetermined
Benign familial
Idiopathic hypercalciuria
IgA nephropathy
Sickle cell trait or anemia
Transplant

Less common

Alport nephritis
Postinfectious glomerulonephritis
Trauma
Exercise
Nephrolithiasis
Henoch-Schonlein purpura

Uncommon

Drugs and toxins
Coagulopathy
Ureteropelvic junction obstruction
Focal segmental glomerulosclerosis
Membranous glomerulonephritis
Membranoproliferative
glomerulonephritis
Lupus nephritis
Hydronephrosis
Pyelonephritis
Vascular malformation
Tuberculosis
Tumor

(Adapted from Lieu TA, Grasmeder M, Kaplan BS. An approach to the evaluation and treatment of microscopic hematuria. *Pediatr Clin North Am* 1991;38:579–92.)

hematuria. Most children with isolated microscopic hematuria do not have a treatable or serious cause for hematuria and do not require an extensive evaluation. The presence of hematuria must be confirmed by microscopy examination of spun sediment of urine because other substances besides blood can produce red or brown urine or give a false positive dipstick test for blood (Box 3).

Once a positive dipstick result has been confirmed by microscopic examination of spun sediment of urine, it is advisable to redirect attention to more specific aspects of the history and physical examination (Box 4).

History

A history of dysuria, frequency, urgency, or flank or abdominal pain suggests a diagnosis of urinary tract infection or nephrolithiasis. Recent trauma, strenuous exercise, menstruation, or bladder catheterization may account for transient hematuria. A sore throat or skin infection within the past 2 to 4 weeks directs the evaluation toward postinfectious glomerulonephritis. Drugs and toxins may cause either hematuria or hemoglobinuria (Box 5). A careful family history must include questions about hematuria, hearing loss, hypertension, nephrolithiasis, renal diseases, renal cystic diseases, hemophilia, sickle cell trait, and dialysis or transplant.

Physical examination

The presence or absence of hypertension or proteinuria helps to decide how extensively to pursue the diagnostic evaluation. If the blood pressure is normal and the patient is passing normal amounts of urine, it is unlikely that microscopic hematuria, whatever its cause, warrants immediate treatment. If the blood pressure is elevated, the hematuria requires a more intensive diagnostic evaluation. The presence of fever or costovertebral angle tenderness may indicate a urinary tract infection. An abdominal mass may be caused by a tumor, hydronephrosis, multicystic dysplastic kidney, or polycystic kidney disease. Macroscopic hematuria with proteinuria suggests glomerulonephritis. Rashes and arthritis can occur in Henoch-Schonlein purpura and systemic lupus erythematosus. Edema is an important feature of the nephrotic syndrome (Table 1).

Laboratory studies

Only two diagnostic tests are required for a child with microscopic hematuria: (1) a test for proteinuria and (2) a microscopic examination of the urine for RBCs and RBC casts. Children with macroscopic hematuria require urine culture and renal imaging by ultrasound. Proteinuria may be present regardless of the cause of bleeding, but usually does not exceed 2+ (100 mg/dL) if the only source of protein is from the blood. This is especially true if the child has microscope hematuria. Patients with 1+ to 2+ proteinuria should be evaluated for orthostatic (postural) proteinuria. A patient with more than 2+ proteinuria should be investigated for glomerulonephritis and nephrotic syndrome. RBC casts, when present, are a highly specific marker for glomerulonephritis, but their

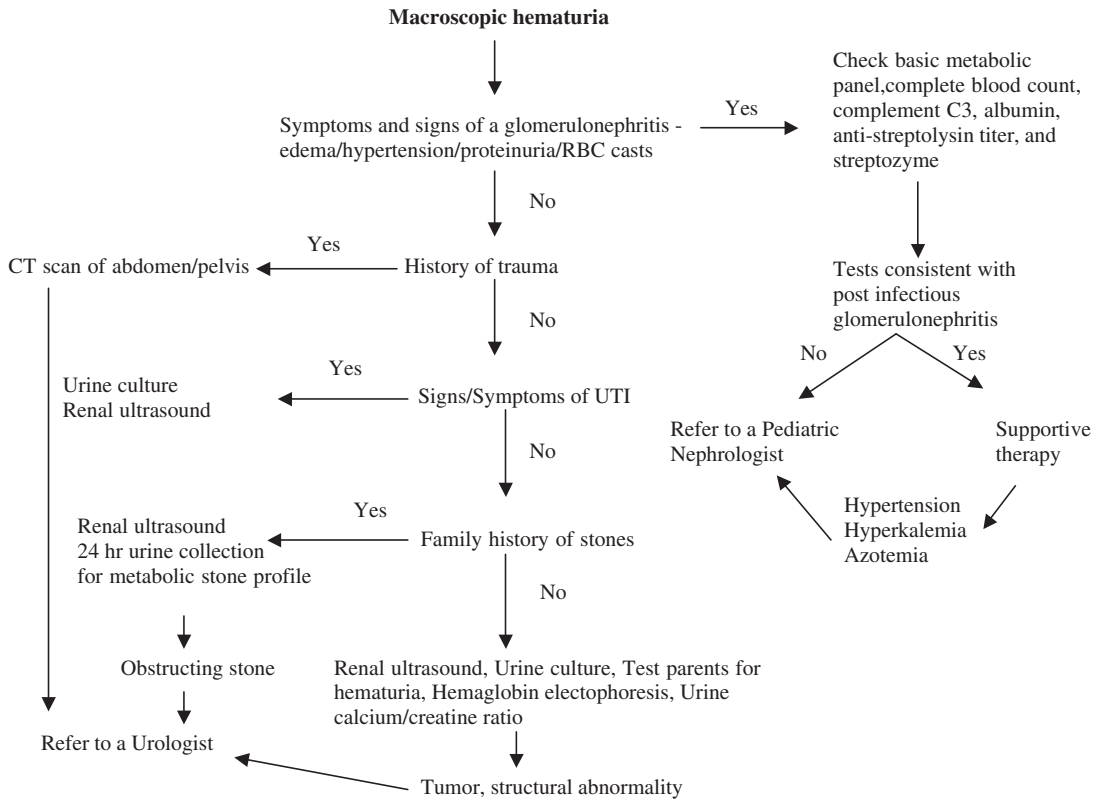


Fig. 1. Evaluation of a child with macroscopic hematuria.

absence does not rule out glomerular disease and their presence does not prove that glomerular injury has occurred. RBC casts should be searched for diligently, however. Distorted, misshapen erythrocytes (dysmorphic) also suggest a glomerular origin for bleeding.

Indications for prompt evaluation

The initial evaluation should be directed toward important and potentially life-threatening causes of hematuria in any child who has any of the following in addition to hematuria: hypertension, edema oliguria, significant proteinuria (more than 500 mg per 24 hours), or RBC casts. These causes include acute postinfectious glomerulonephritis (PIGN), Henoch-Schonlien purpura (HSP), hemolytic-uremic syndrome, membranoproliferative glomerulonephritis, IgA nephropathy, and focal segmental glomerulosclerosis.

This initial evaluation should include a complete blood count (hemolytic-uremic syndrome), throat culture, streptozyme panel and serum C3

concentration (acute poststreptococcal glomerulonephritis), and serum creatinine and potassium concentrations (if there is renal insufficiency). All children with macroscopic hematuria require renal ultrasound upon presentation. Pending the results of these tests, the child's blood pressure and urine output must be monitored frequently.

If the cause of the hematuria remains unclear after the results of the above tests have been obtained, a 24-hour urine collection for protein, creatinine, and calcium should be obtained. Children with microhematuria and protein excretion of less than 25 mg/dL (6 mg/h/m²) usually do not have a glomerulopathy and can be considered to have isolated microscopic hematuria. Some, however, may have IgA nephropathy, early or mild Alport's syndrome, or thin basement membrane disease. There is no specific treatment, however, for any of these conditions. The causes of microscopic hematuria with substantial proteinuria include minimal change nephrotic syndrome, IgA nephropathy, Alport's syndrome, membranoproliferative glomerulonephritis, membranous nephropathy, and

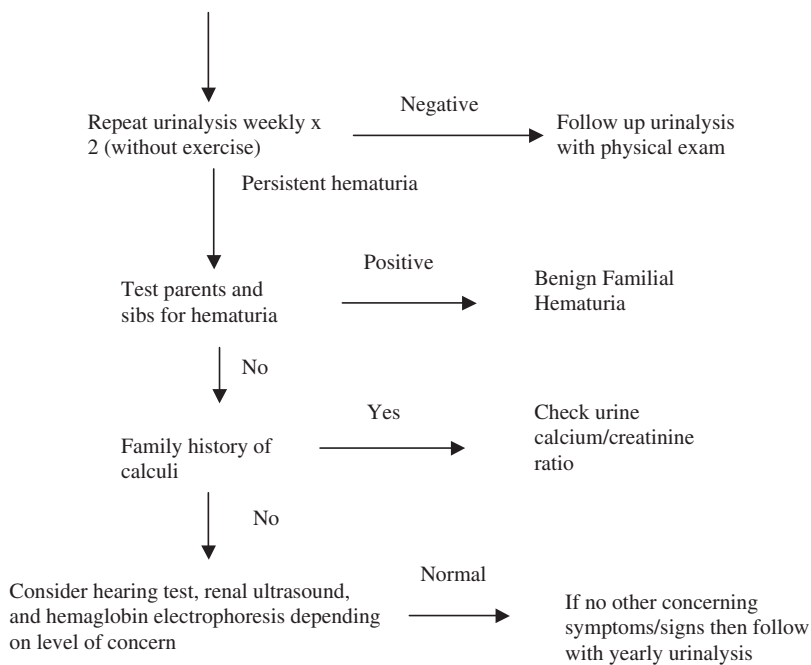
Isolated Microscopic Hematuria - Asymptomatic

Fig. 2. Evaluation of a child with asymptomatic microscopic hematuria.

focal segmental glomerulosclerosis. Additional investigations are warranted in this context, some may require treatment, and referral to a pediatric nephrologist should be considered.

Differential diagnosis and management of macrohematuria

Macroscopic hematuria requires prompt evaluation to exclude potentially life-threatening causes. A urinalysis must be performed to confirm the presence of RBCs and to look for casts and crystals. Occasionally, *Schistosoma hematobium* is diagnosed by finding ova in the urine of an immigrant child with unexplained macroscopic hematuria [16]. Painful gross hematuria usually is caused by infections, calculi, or urologic conditions. Glomerular causes of hematuria are painless. The most common glomerular causes of gross hematuria in children are poststreptococcal glomerulonephritis and IgA nephropathy.

A detailed history must be obtained to elicit the cause of hematuria. An antecedent sore throat, pyoderma, or impetigo proteinuria, edema, hypertension, or RBC casts suggests glomerulonephritis. If the antistreptolysin O titer, streptozyme test, and serum C3 concentration

are informative, the diagnosis is poststreptococcal glomerulonephritis. If these tests are not informative, further investigations are warranted to rule out other causes of glomerulonephritis. IgA nephropathy can cause recurrent macroscopic hematuria with flank or abdominal pain and may be preceded by an upper respiratory tract infection.

Fever, dysuria, and flank pain with or without voiding symptoms suggests a urinary tract infection, which is the most common cause of gross hematuria in children presenting to an emergency room. A CT scan of the abdomen and pelvis must be obtained promptly with a history of abdominal trauma and the child must be referred to a urologist. A family history of renal calculi or severe renal colic with gross hematuria suggests urinary calculi. Hypercalciuria can cause recurrent macroscopic or microscopic hematuria in the absence of calculi on imaging studies. If no obvious cause is found for macroscopic hematuria by history, physical, and preliminary studies, the differential diagnosis includes hypercalciuria, sickle cell trait, thin basement membrane disease, calculi, and vascular or bladder pathology.

Cystoscopic examination in children rarely reveals a cause for hematuria but should be done when bladder pathology is a consideration.

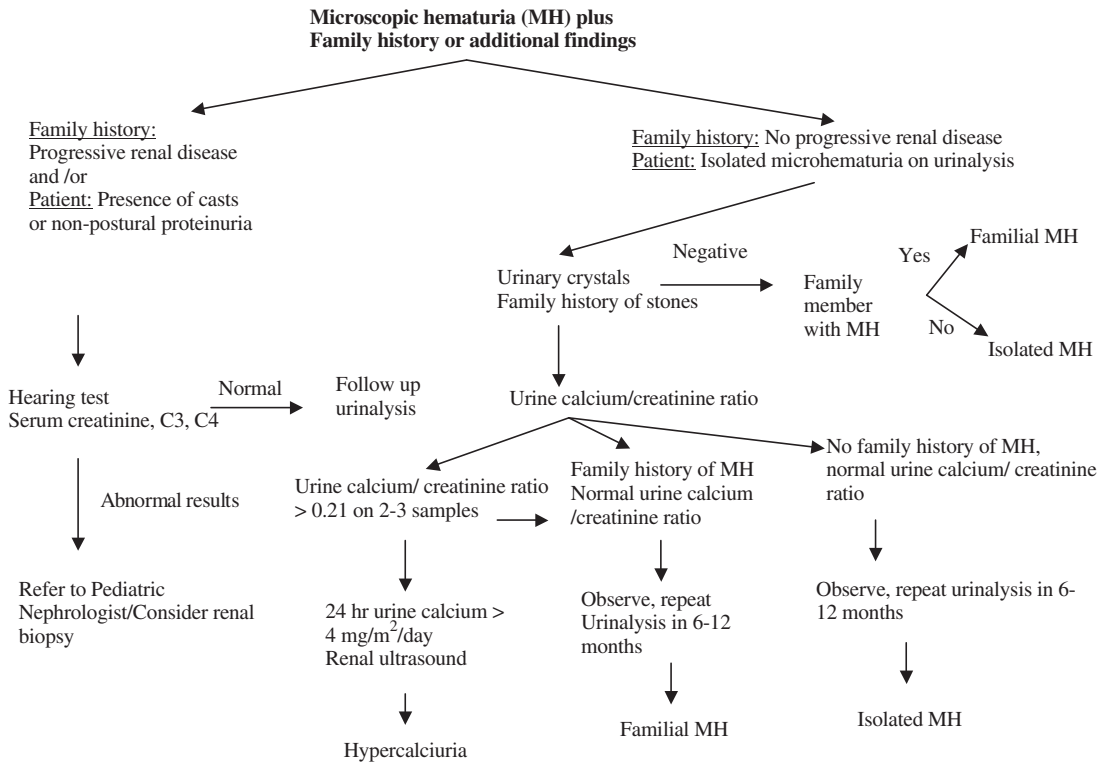


Fig. 3. Evaluation of a child with symptomatic microscopic hematuria.

Cystoscopy to lateralize the source of bleeding is performed best during active bleeding. In young girls with recurrent gross hematuria, it is important to inquire about a history of child abuse or insertion of a vaginal foreign body; the genital area must be examined for signs of injury.

Differential diagnosis of transient microhematuria

Blunt abdominal trauma may cause either microscopic or gross hematuria. Hematuria after minor blunt abdominal trauma may serve as a marker for congenital anomalies. In a study of suspected isolated renal trauma, 11 of 78 children had congenital anomalies, but only two required later surgical intervention [17]. A diagnostic study should be done only if there are at least 50 RBCs/hpf, however. Although intravenous urography traditionally has been the study of choice for suspected, isolated, blunt renal trauma, renal ultrasonography may be adequate if there are no other indications for immediate surgical intervention. Children with less than 50 RBCs/hpf are unlikely to have injuries or congenital anomalies

that require intervention [17,18]. Transient hematuria may be associated with strenuous exercise. The type of activity, as well as activity duration and intensity, contributes to its development [19,20]. If the hematuria disappears with rest, no further investigation is needed.

Differential diagnosis of persistent microhematuria

The precise frequencies of occurrence of the causes of persistent microscopic hematuria have not been established. Most series have included patients with macroscopic and microscopic hematuria as well as patients with and without proteinuria. In a study of 33 children with persistent microscopic hematuria, 27 did not have proteinuria. Two of these had ureteropelvic junction obstruction, and renal biopsies were done in 21 of the remaining 25 patients, two of which had IgA nephropathy, one had hereditary nephritis, eight had normal renal biopsies, and 10 had nonspecific abnormalities [21].

The author retrospectively studied 325 children with isolated persistent microscopic hematuria

Box 3. Urine color*Dark yellow or orange*

Normal concentrated urine
Rifampin pyridium

Dark brown or black

Methemoglobinemia
Bile pigments
Homogentestic acid, thymol, melanin,
tyrosinosis, alkaptonuria
Alanine, cascara, resorcinol

Red or pink urine

RBCs, free hemoglobin, myoglobin,
porphyrins
Benzene, chloroquine,
desferoxamine, phenazopyridine,
phenolphthalein
Beets, blackberries, red dyes in food
Urates

referred to the pediatric nephrology outpatient clinics at the Children's Hospitals of Buffalo and Philadelphia between 1985 and 1994. Hypercalciuria was present in 11%. Renal ultrasonography and voiding cystourethrography (VCUG) was performed in 87% and 24% of children. There were no clinically significant findings. Primary physicians or urologists ordered 75% of the VCUG before referral to a nephrologist [22]. In another study, 2 of 15 patients with persistent microscopic hematuria progressed to end-stage renal failure (one with Alport's syndrome after 14 years and one with focal segmental glomerulonephritis after 10 years), but it is not clear when in their courses these patients developed proteinuria. This study supports the author's minimalist approach to children with isolated persistent microscopic hematuria (see Fig. 2). Because the most common diagnoses in children with persistent microscopic hematuria without proteinuria are benign persistent or benign familial hematuria, idiopathic hypercalciuria, IgA nephropathy, and Alport's syndrome, a more extensive evaluation is indicated only when proteinuria or other indicators are present (see Fig. 3).

Management of microhematuria

When there are no indications for immediate intervention, the parents should be reassured that

Box 4. Specific history and physical examination in a patient with hematuria*History*

Trauma (recent bladder catheterization,
blunt abdominal trauma)
Exercise
Menstruation
Recent sore throat, skin infection
Viral illness
Dysuria, frequency, urgency, enuresis
Urine color; stream discolored at
initiation, throughout, or at
termination of micturition
Abdominal pain, costovertebral angle
pain, suprapubic pain
Medications (eg, cyclophosphamide),
environmental toxins, or herbal
compounds
Passage of a calculus
Joint or muscle pain

Family history

Hematuria
Deafness
Hypertension
Coagulopathy
Hemoglobinopathy
Calculi
Renal failure, dialysis, or transplant

Physical examination

Fever, arthritis, rash
Blood pressure
Edema
Nephromegaly
Costovertebral angle tenderness

(Adapted from Lieu TA, Grasmeder M, Kaplan BS. An approach to the evaluation and treatment of microscopic hematuria. *Pediatr Clin North Am* 1991;38:579–92.)

there are no life-threatening conditions, that there is time to plan a stepwise evaluation, and that most causes of isolated microscopic hematuria in children do not warrant treatment. In the author's experience, parents have two main concerns when they learn that their child has microscopic hematuria: (1) will chronic kidney damage occur, and (2) does my child have cancer (or leukemia)? Addressing these fears allays concerns and expen-

Box 5. Drugs and toxins associated with urine dipsticks positive for blood

Hemoglobinuria

Carbon monoxide

Mushrooms

Naphthalene

Sulfonamides

Tin compounds

Lead

Methicillin

Phenol

Sulfonamides

Turpentine

Ticlodipine [14]

Hematuria

Amitriptylene

Anticoagulants

Aspirin

Chlorpromazine

Cyclophosphamide

Toluene [13]

Ritonavir, indinavir [15]

(Adapted from Lieu TA, Grasmeder M, Kaplan BS. An approach to the evaluation and treatment of microscopic hematuria. *Pediatr Clin North Am* 1991;38:579–92.)

sive investigations. The plans for further testing and follow-up should be stated clearly from the outset. The dipstick and microscopic urinalysis should be repeated twice within 2 weeks after the initial specimen. If the hematuria resolves, no further tests are needed. If hematuria persists, with more than five RBCs/hpf and no evidence of hypertension, oliguria, or proteinuria on at least two of three consecutive samples, determination of the serum creatinine concentration is reasonable.

Renal ultrasonography should be considered as a screening test because it is noninvasive and provides tangible information on the presence or absence of stones, tumors, hydronephrosis, structural anomalies, renal parenchymal dysplasia, medical renal disease, inflammation of the bladder, bladder polyps, and posterior urethral valves. The yield of renal ultrasonography for evaluation of an asymptomatic child with microscopic hematuria remains unproven [22]. The value of a normal renal ultrasonographic examination in terms of reassurance, however, may justify its cost and time.

In the author's view, intravenous urography is of little value in the evaluation of persistent microscopic hematuria because renal ultrasonography is as reliable as intravenous urography for excluding macroscopic lesions. If the serum creatinine concentration and blood pressure are normal, it is reasonable to defer further investigations in an asymptomatic child with persistent microscopic hematuria who does not have hypertension, proteinuria, or RBC casts. The author suggests a follow-up examination at least every 12 months that includes microscopic urinalysis, a dipstick test for proteinuria, and blood pressure measurement.

In a study of 142 children with microscopic hematuria on two initial urine samples who had two subsequent urinalyses performed in the subsequent 4 to 6 months, 33 (23%) had persistent hematuria on both follow-up specimens [21]. The parents' urine should be tested with dipsticks [23,24]. Although phase-contrast microscopy and size-particle discrimination can distinguish glomerular from nonglomerular sources of hematuria, identification of dysmorphic RBC offers little additional information in the evaluation of microscopic hematuria in children. A thoughtful history and physical examination with microscopic urinalysis and dipstick for proteinuria provide equal diagnostic information. The author cannot recommend its routine use in the evaluation of microscopic hematuria in children [25,26].

Many other tests may be considered in the asymptomatic child with persistent microscopic hematuria, but the cost and time required for further testing must be weighed against the potential benefits, which are subjective and depend on how much importance the parents and physician place on establishing a more definite diagnosis and prognosis. These considerations apply especially to the advisability of performing a kidney biopsy on a patient with isolated microhematuria. Piqueras and colleagues [27] reviewed the clinical and renal biopsy findings in 322 children in whom nonglomerular causes of hematuria were excluded. Isolated microscopic hematuria was present in 155 children, 100 of whom had a thin basement membrane (TBM) or Alport's syndrome, 12 (7%) had IgA nephropathy, and 43 (28%) had normal or clinically insignificant glomerular findings. No child required therapy, but the argument was made that a precise diagnosis is required for prognosis, insurance purposes, and genetic counseling. In the author's opinion, renal biopsy should be deferred for this reason unless a specific indication exists.

Table 1
Distinguishing features of glomerular and nonglomerular hematuria

Feature	Glomerular hematuria	Nonglomerular hematuria
History		
Burning on micturition	No	Urethritis, cystitis
Systemic complaints	Edema, fever, pharyngitis, rash, arthralgias	Fever with urinary tract infections severe pain with calculi
Family history	Deafness in Alport's syndrome, renal failure	Usually negative; may be positive with calculi
Physical examination		
Hypertension	Often present	Unlikely
Edema	May be present	No
Abdominal mass	No	Important with Wilms' tumor, polycystic kidneys
Rash, arthritis	Lupus erythematosus, Henoch-Schonlein	No
Urine analysis		
Color	Brown, tea, cola	Bright red
Proteinuria	Often present	No
Dysmorphic red blood cells	Yes	No
Red blood cell casts	Yes	No
Crystals	No	May be informative

Isolated microscopic hematuria in the absence of a family history of hematuria in a close relative and episodes of macroscopic hematuria is unlikely to be associated with abnormal renal biopsy findings. The main exceptions are IgA nephropathy and TBM nephropathy, but there are no specific treatments for these conditions.

Specific conditions

This section focuses on the more common causes of hematuria in children and is organized according to the anatomic location for the bleeding. Box 6 outlines a suggested approach for referral of a child with hematuria.

Glomerular causes of hematuria

Postinfectious glomerulonephritis

Patients with acute PIGN often present with acute onset of tea-colored urine (macroscopic hematuria) consistent with glomerular bleeding, but the hematuria occasionally may be only microscopic [28]. Patients with PIGN may be asymptomatic or they may complain of malaise, headache, nausea, vomiting, abdominal pain, and oliguria. The physical examination may reveal edema and an elevated blood pressure that can be severe enough to cause encephalopathy. PIGN is accredited most commonly to pharyngitis or skin

infection with Group A beta-hemolytic streptococci.

Clinical features of the nephritis manifest 7 to 21 days after the preceding infection. Antistreptolysin O titers may be negative early in the course, but the

Box 6. A suggested approach for referral of a child with hematuria

Nephrologist

Acute poststreptococcal glomerulonephritis if the patient has hypertension, azotemia, or hyperkalemia

Other forms of glomerulonephritis (particularly if the patient has proteinuria, hypertension, or persistent hypocomplementemia)

Family history of renal failure

Systemic disease

Urologist

Reassurance

Abnormal genitourinary anatomy

Trauma

Stones (nephrologist for metabolic work-up)

Tumor

Nonglomerular gross hematuria

streptozyme test is often positive within 10 days of the onset of symptoms [29]. Almost all patients have decreased levels of C3 early in the clinical course that normalize 6 to 8 weeks later. The C4 concentration is usually normal or only slightly decreased. If the C3 is persistently low, the patient should be further investigated for other causes of a persistent hypocomplementemic glomerulonephritis, including membranoproliferative glomerulonephritis, systemic lupus erythematosus, and chronic bacteremia. Urinalysis typically reveals RBC casts and proteinuria. Blood urea nitrogen and creatinine can be normal or elevated. In most patients hematuria and proteinuria resolves within a few weeks. Microscopic hematuria may persist for as long as 2 years. The prognosis is excellent. There are no data that indicate an untoward outcome of PIGN in a patient whose only manifestation was microscopic hematuria.

Henoch-Schonlein purpura

Approximately half of children with a clinical diagnosis of HSP manifest renal involvement [30]. Renal manifestations include hematuria, proteinuria, nephrotic syndrome, glomerulonephritis, and acute renal failure. Hematuria and proteinuria are usually transient but may persist for several months. Relapses and remissions are seen during the course of the disease and may manifest with episodes of gross hematuria. The long-term prognosis of HSP directly depends on the severity of renal involvement. In an unselected population of children with HSP, an estimated 2% develop long-term renal impairment [31]. This figure is considerably higher in specialized pediatric centers [32]. All patients with HSP who have renal involvement should be referred to a pediatric nephrologist.

IgA nephropathy

IgA nephropathy is probably the most common cause of hematuria in children [33]. The condition is diagnosed by histopathologic demonstration of mesangial deposition of IgA. IgA nephropathy usually is detected after periods of gross hematuria that follow minor infections [34]. Microscopic hematuria may be present between episodes of gross hematuria. In a school-screening program in Japan, dipstick urinalysis detects most children with microscopic hematuria who have IgA nephropathy on renal biopsy [35]. Predictors of a poorer outcome include crescentic glomerulonephritis and an older age of onset, hypertension, and nephrotic range proteinuria. There is also evidence suggesting that recurrent bouts of macroscopic hematuria predict a more guarded out-

come in IgA nephropathy [36]. The prognosis of IgA nephropathy varies, and up to one third of children have a guarded long-term renal prognosis [37]. There is no specific treatment for IgA nephropathy and no evidence supports the need to make a definitive diagnosis in a child whose only manifestation is microscopic hematuria. The author disagrees with Schena's [38] and Piqueras's [39] recommendation that a renal biopsy should be done in patients with microscopic hematuria and suspected IgA nephropathy to confirm the diagnosis and to increase awareness of the prognosis of patients with IgA nephropathy in the Western world. In a few patients, IgA nephropathy may be inherited, and has been localized to 6q22-23 [40,41].

Rapidly progressive glomerulonephritis

Rapidly progressive glomerulonephritis presents with symptoms and signs similar to PIGN, and although uncommon, requires the urgent attention of a pediatric nephrologist. Laboratory studies show acute renal failure, and renal biopsy demonstrates glomerular crescents. Untreated RPGN can result in end-stage renal disease (ESRD) in a few weeks. Many of the causes of glomerulonephritis listed in Fig. 1 can present with rapid progression, or RPGN can be idiopathic [42]. Prompt diagnosis and pulsed methylprednisolone therapy may prevent progression to ESRD [43].

Alport hereditary nephritis

Alport's syndrome is a progressive, inherited glomerulonephritis accounting for 1% to 2% of patients who develop ESRD, with an estimated gene frequency of approximately 1 in 5000 [44]. Alport's syndrome is characterized by episodes of recurrent or persistent microscopic hematuria, occasionally gross hematuria, proteinuria, progressive renal insufficiency, and progressive, high-frequency, sensorineural hearing loss. The phenotype and the course vary widely. Ocular defects include anterior lenticonus and yellow-white to silver flecks within the macular and midperipheral regions of the retina [45]. Hematuria that is usually microscopic is the usual initial finding in children. In the absence of RBC casts or proteinuria, the diagnosis may be delayed or unsuspected, but this does not have serious consequences for the child unless there are hearing problems.

A careful family history and urine examinations must be obtained in every patient who

presents with microscopic hematuria. If there is any reason to suspect familial renal disease, a hearing test should be done to prevent speech or educational handicap. Men manifest signs and symptoms earlier than women, and approximately 30% can progress to ESRD. Patients who receive a renal allograft have a small risk for developing Goodpasture disease posttransplant [46]. Some women may have a hearing deficit without any urinary abnormalities. Alport's syndrome is a genetically heterogeneous disease, usually is inherited as an X-linked semidominant trait, caused by mutations in *COL4A5* gene on the X-chromosome, and in less than 10% of cases is caused by mutations of the *COL4A3* or the *COL4A4* gene on chromosome 2q.

Thin glomerular basement membrane nephropathy

Thin basement membrane nephropathy (TBMN) or *benign familial hematuria* is the most common cause of persistent glomerular bleeding in children and occurs in at least 1% of the population [47]. Benign familial hematuria may be inherited in an autosomal dominant or autosomal recessive manner, and may be associated with mutations in type IV collagen [48,49]. Proteinuria, progressive renal insufficiency, hearing deficits, or ophthalmologic abnormalities almost never occur in patients with TBMN or their family members [50]. The hematuria is usually microscopic, the RBCs may be dysmorphic, and there may be RBC casts. Occasionally, frank hematuria may occur with an upper respiratory tract infection. The histopathologic changes are thinning of glomerular basement membranes. A renal biopsy is warranted in TBMN only if there are atypical features, or if IgA disease or X-linked Alport's syndrome cannot be excluded clinically [47].

Renal parenchymal causes of hematuria

Tumors

Children with Wilms' tumor most commonly present with flank mass or macroscopic hematuria. Although a tumor is listed frequently in the differential diagnosis of hematuria, neither the author's search of the literature nor the author's experience has produced documented cases of tumors presenting with isolated microscopic hematuria. Bladder tumors usually manifest with voiding difficulties or occasionally with macroscopic hematuria [51].

Nephrocalcinosis

Nephrocalcinosis implies an increase in calcium content in the kidney and is distinct from urolithiasis, although the two conditions often coexist. Nephrocalcinosis may be focal, occurring in an area of previously damaged parenchyma, or generalized. It is often associated with hypercalciuria. The most frequent cause of nephrocalcinosis is prematurity with and without furosemide treatment [52]. Nephrocalcinosis associated with hyperoxaluria involves the cortex and medulla, whereas the corticomedullary junction is involved most often with metabolic disease. The clinical manifestations of nephrocalcinosis include abdominal pain, dysuria, incontinence, and urinary tract infection in more than one third of patients. Microscopic hematuria usually occurs in the context of hypercalciuria or coexistent renal stone disease [53]. The diagnosis of nephrocalcinosis usually is made by renal ultrasonography [54]. The offending agent (loop diuretic, excess vitamin D) must be withdrawn if possible, and any underlying disorder (distal renal tubular acidosis) must be treated. Nephrocalcinosis rarely progresses to end stage renal failure.

Interstitial nephritis

Interstitial nephritis in children with associated microscopic or macroscopic hematuria is uncommon. Analgesics and antibiotics are implicated most frequently with resolution occurring after discontinuation of the offending medication [55,56].

Cystic renal disease

Cysts often are discovered incidentally after mild trauma or when abdominal ultrasound is performed for other indications [57]. Cysts may be solitary, associated with dysplasia, or associated with polycystic renal disease. Patients with cystic renal disease or with a family history of cystic disease should be referred to a pediatric nephrologist. Bleeding associated with cystic disease may be considerable and may require immediate nephrologic or urologic evaluation.

Hypercalciuria

An association between hematuria and hypercalciuria was first noted in 1981 in children with asymptomatic macroscopic or microscopic hematuria without signs of renal stones [58,59]. These children had increased urinary excretion calcium despite normal serum calcium levels. Some were otherwise asymptomatic, but others eventually developed urolithiasis. Because of this, the

measurement of urinary calcium excretion has become a standard part of the evaluation of hematuria in children.

Many conditions can result in hypercalciuria, including hyperparathyroidism, immobilization, vitamin D intoxication, and idiopathic hypercalciuria. (See later discussion and recent reviews of idiopathic hypercalciuria [60,61].)

Idiopathic hypercalciuria may result from a tubular leak of calcium (*renal hypercalciuria*) or from increased gastrointestinal absorption of calcium (*absorptive hypercalciuria*). The mechanism whereby hypercalciuria causes hematuria is unclear. It has been assumed either that hematuria is the result of irritation of the uroepithelium by microcalculi or that microscopic areas of nephrocalcinosis cause bleeding. Urine erythrocytes are shaped normally and RBC cast are absent. There is often a family history of renal stones, and some authors recommend evaluation of parents and siblings for hypercalciuria. In contrast to benign, idiopathic hematuria, macroscopic bleeding and occasional blood clots may be seen in patients with hypercalciuria. Symptoms may include dysuria, suprapubic pain, or renal colic. The author does not restrict calcium in children because osteopenia may result, and reserves therapy with thiazide diuretics (to enhance calcium reclamation from the glomerular filtrate) for patients with recurrent episodes of macroscopic hematuria or a family history of urolithiasis, or those who develop a stone [62].

Renal transplant

Children with renal transplants are at risk for developing urolithiasis, the only manifestation of which may be hematuria [63]. Review of 21 patients showed that one third had persistent microscopic hematuria. Patients with and without hematuria had similar baseline characteristics. The etiology of hematuria was pre-existing (one patient), recurrent IgA nephropathy (one patient), cytomegalovirus nephritis (one patient), and unexplained (four patients). None had renal calculi or hypercalciuria. Three of the four patients with unexplained hematuria have chronic allograft nephropathy, and the fourth (original disease dysplasia) had hypocomplementemia. Five years after onset of hematuria, all patients are alive with stable allograft function. Causes of posttransplant hematuria, although diverse, are stone disease in less than 2% of patients. Whether chronic allograft nephropathy causes hematuria remains to be determined. Renal biopsies should be performed to

look for recurrent or de novo glomerulonephritis with onset of hematuria if proteinuria or deterioration of renal function is seen.

Urinary tract and vascular infection

In children the most common cause of hematuria is urinary tract infection. (Please see the article by Shortliffe elsewhere in this issue for further exploration of urinary infection.)

Trauma

Pelvic fractures and abdominal/chest injuries help identify patients who require evaluation of the genitourinary tract. The need for genitourinary tract evaluation in pediatric trauma patients is based as much on clinical judgment as on the presence of hematuria [64]. Children with microscopic hematuria of greater than 50 RBC/hpf or macroscopic hematuria, even in the presence of a benign abdominal examination, should undergo imaging with an abdominal CT scan [18]. Significant renal injuries are unlikely in pediatric patients with blunt renal trauma but no gross or less than 50 RBC/hpf microscopic hematuria [18]. Most children with renal injury are managed conservatively [65]. When blood is present at the urethral meatus, cystourethrography is required to look for urethral or bladder injury [66].

Hemangiomas and polyps

Hemangiomas in the urinary tract may cause hematuria, but these are often impossible to locate and are only clinically significant if there is gross bleeding; therefore, hemangiomas require diagnostic testing and treatment only if they manifest with macroscopic hematuria [67]. The most common presenting symptoms of urinary tract polyps are hematuria and urinary tract obstruction. Transurethral resection is curative [68].

Loin pain hematuria syndrome

Loin pain hematuria syndrome (LPHS) was first reported in 1967 by Little and colleagues [69] and refers to episodes of unilateral or bilateral lumbar pain accompanied by macroscopic or microscopic hematuria. The diagnosis is made by exclusion after patients are shown to have normal renal function, normal genitourinary system, no infection, no malignancy, no hypercalciuria or nephrolithiasis, and no previous trauma. Most patients are women between 20 and 40 years of age, but there are reports of LPHS in children [70,71]. The pathogenesis of LPHS is unresolved; although a vascular cause seems most likely, renal

biopsy is not helpful [72]. The symptoms of LPHS are similar to those found in parents of children with Munchausen syndrome by proxy (MSBP). MSBP must be excluded in all children where LPHS is considered. Almost 50% of patients with LPHS have psychopathologic disturbances [73,74]. The author agrees with Gusmano [75] in questioning the existence of LPHS, particularly in children.

Idiopathic urethrorrhagia

Urethrorrhagia usually presents in prepubertal boys. Symptoms included urethrorrhagia (terminal urethral hematuria) and dysuria (33%). Cystourethroscopy reveals bulbar urethral inflammation. Routine radiographic, laboratory, and endoscopic evaluation is unnecessary for evaluating urethrorrhagia. Spontaneous resolution occurs in over 90% of children. Watchful waiting is indicated. In children with prolonged urethrorrhagia, evaluation should be considered because urethral stricture may be identified [76].

References

- [1] Lieu TA, Grasmeyer M, Kaplan BS. An approach to the evaluation and treatment of microscopic hematuria. *Pediatr Clin North Am* 1991;38:579–92.
- [2] Ingelfinger JR, Davis AE, Grupe WE. Frequency and etiology of gross hematuria in a general pediatric setting. *Pediatrics* 1977;59:557–61.
- [3] Feld LG, Waz WR, Perez LM, et al. Hematuria: an integrated medical and surgical approach. *Pediatr Clin North Am* 1997;44:1191–210.
- [4] Tomita M, Kitamoto Y, Nakayama M, et al. A new morphological classification of urinary erythrocytes for differential diagnosis of glomerular hematuria. *Clin Nephrol* 1992;37:84–9.
- [5] Moore GP, Robinson M. Do urine dipsticks reliably predict microhematuria? *Ann Emerg Med* 1988;17:257–60.
- [6] Strasinger SK. *Urinalysis and body fluids*. 3rd edition. Philadelphia: F.A. Davis Company; 1994.
- [7] Dodge WF, West EF, Smith EH, et al. Proteinuria and hematuria in schoolchildren: epidemiology and early natural history. *J Pediatr* 1976;88:327–47.
- [8] Fassett RG, Horgan BA, Mathew TH. Detection of glomerular bleeding by phase-contrast microscopy. *Lancet* 1982;1:1432–4.
- [9] Diven SC, Travis LB. A practical primary care approach to hematuria in children. *Pediatr Nephrol* 2000;14:65–72.
- [10] Vehaskari VM, Rapola J, Koskimies O, et al. Microscopic hematuria in school children: epidemiology and clinicopathologic evaluation. *J Pediatr* 1979;95:676–84.
- [11] Dodge WF, West EF, Smith EH, et al. Proteinuria and hematuria in schoolchildren: epidemiology and early natural history. *J Pediatr* 1976;88:327–47.
- [12] Collar JE, Ladva S, Cairns TD, Cattell V. Red cell traverse through thin glomerular basement membranes. *Kidney Int* 2001;59:2069–72.
- [13] Zabedah MY, Razak M, Zakiah I, Zuraidah AB. Profile of solvent abusers (glue sniffers) in East Malaysia. *Malays J Pathol* 2001;23:105–9.
- [14] Turken O, Ozturk A, Orhan B, Kandemir G, Yaylaci M. Thrombotic thrombocytopenic purpura associated with ticlopidine. *Acta Haematol* 2003;109:40–2.
- [15] Wilde JT. Protease inhibitor therapy and bleeding. *Haemophilia* 2000;6:487–90.
- [16] Kaplan BS, Meyers KEC. Images in clinical medicine. Schistosoma haematobium. *N Engl J Med* 2000;343:1085.
- [17] Lieu TA, Fleisher GR, Mahboubi S, Schwartz JS. Hematuria and clinical findings as indications for intravenous pyelography in pediatric blunt renal trauma. *Pediatrics* 1988;82:216–22.
- [18] Morey AF, Bruce JE, McAninch JW. Efficacy of radiographic imaging in pediatric blunt renal trauma. *J Urol* 1996;156:2014–8.
- [19] Holmes FC, Hunt JJ, Sevier TL. Renal injury in sport. *Curr Sports Med Rep* 2003;2:103–9.
- [20] McInnis MD, Newhouse IJ, von Duvillard SP, Thayer R. The effect of exercise intensity on hematuria in healthy male runners. *Eur J Appl Physiol Occup Physiol* 1998;79:99–105.
- [21] Vehaskari VM, Rapola J, Koskimies O, et al. Microscopic hematuria in schoolchildren: epidemiology and clinicopathological classification. *J Pediatr* 1979;96:676–84.
- [22] Feld LG, Meyers KE, Kaplan BS, et al. Limited evaluation of microscopic hematuria in pediatrics. *Pediatrics* 1998;102:E42.
- [23] Blumenthal SS, Fritsche C, Lemann J. Establishing the diagnosis of benign familial hematuria. *JAMA* 1988;259:2263–6.
- [24] Moghal NE, Milford DV, White RH, Raafat F, Higgins R. Coexistence of thin membrane and Alport nephropathies in families with haematuria. *Pediatr Nephrol* 1999;13:778–81.
- [25] Game X, Soulie M, Fontanilles AM, Benoit JM, Corberand JX, Plante P. Comparison of red blood cell volume distribution curves and phase-contrast microscopy in localization of the origin of hematuria. *Urology* 2003;61:507–11.
- [26] Ward JF, Kaplan GW, Mevorach R, et al. Refined microscopic urinalysis for red blood cell morphology in the evaluation of asymptomatic microscopic hematuria in a pediatric population. *J Urol* 1998;160:1492–5.
- [27] Piqueras AI, White RH, Raafat F, Moghal N, Milford DV. Renal biopsy diagnosis in children

- presenting with hematuria. *Pediatr Nephrol* 1998; 12:386–91.
- [28] Robson WL, Leung AK. Post-streptococcal glomerulonephritis with minimal abnormalities in the urinary sediment. *J Singapore Paediatr Soc* 1992;34: 232–4.
- [29] Ofek I, Kaplan R, Bergner- Rabinowitz S, et al. Antibody tests in streptococcal pharyngitis. Strep- tozyme versus conventional methods. *Clin Pediatr* 1973;12:341–4.
- [30] Rai A, Nast C, Adler S. Henoch-Schonlein purpura nephritis. *J Am Soc Nephrol* 1999;10:2637–44.
- [31] Koskimies O, Mir S, Rapola J, et al. Henoch- Schonlein nephritis: long-term prognosis of un- selected patients. *Arch Dis Child* 1981;56:482–4.
- [32] Coppo R, Mazzucco G, Cagnoli L, Lupo A, Schena FP. Long-term prognosis of Henoch-Schonlein nephritis in adults and children. Italian Group of Renal Immunopathology. Collaborative Study on Henoch-Schonlein purpura. *Nephrol Dial Transplant* 1997;12:2277–83.
- [33] Utsunomiya Y, Koda T, Kado T, Okada S, Hayashi A, Kanzaki S, et al. Incidence of pediatric IgA nephropathy. *Pediatr Nephrol* 2003;18:511–5.
- [34] Southwest Pediatric Nephrology Study Group. A multicenter study of IgA nephropathy in children. *Kidney Int* 1982;22:643–52.
- [35] Utsunomiya Y, Koda T, Kado T, et al. Incidence of pediatric IgA nephropathy. *Pediatr Nephrol* 2003; 18:511–5.
- [36] Feehally J. Predicting prognosis in IgA nephropa- thy. *Am J Kidney Dis* 2001;38:881–3.
- [37] Hunley TE, Kon V. IgA nephropathy. *Curr Opin Pediatr* 1999;11:152–7.
- [38] Schena FP. A retrospective analysis of the natural history of primary IgA nephropathy worldwide. *Am J Med* 1990;89:209–15.
- [39] Piqueras AI, White RH, Raafat F, Moghal N, Milford DV. Renal biopsy diagnosis in children presenting with hematuria. *Pediatr Nephrol* 1998; 12:386–91.
- [40] Gharavi AG, Yan Y, Scolari F, et al. IgA nephropathy, the most common cause of glomeru- lonephritis, is linked to 6q22–23. *Nat Genet* 2000; 26:354–7.
- [41] Scolari F. Inherited forms of IgA nephropathy. *J Nephrol* 2003;16:317–20.
- [42] Hoschek JC, Dreyer P, Dahal S, Walker PD. Rapidly progressive renal failure in childhood. *Am J Kidney Dis* 2002;40:1342–7.
- [43] West CD, McAdams AJ, Witte DP. Acute non- proliferative nephritis: a cause of renal failure unique to children. *Pediatr Nephrol* 2000;14: 786–93.
- [44] Pescucci C, Longo I, Bruttini M, Mari F, Renieri A. Type-IV collagen related diseases. *J Nephrol* 2003; 16:314–6.
- [45] McCarthy PA, Maino DM. Alport syndrome: a review. *Clin Eye Vis Care* 2000;12:139–50.
- [46] Hudson BG, Tryggvason K, Sundaramoorthy M, Neilson EG. Alport's syndrome, Goodpasture's syndrome, and type IV collagen. *N Engl J Med* 2003;348:2543–56.
- [47] Savige J, Rana K, Tonna S, et al. Thin basement membrane nephropathy. *Kidney Int* 2003;64: 1169–78.
- [48] Longo I, Porcedda P, Mari F, et al. COL4A3/ COL4A4 mutations: from familial hematuria to autosomal-dominant or recessive Alport syndrome. *Kidney Int* 2002;61:1947–56.
- [49] Lemmink HH, Nillesen WN, Mochizuki T, et al. Benign familial hematuria due to mutation of the type IV collagen alpha 4 gene. *J Clin Invest* 1996;98: 1114–8.
- [50] Blumenthal SS, Fritsche C, Lemann J. Establishing the diagnosis of benign familial hematuria: the importance of examining the urine sediment of family members. *JAMA* 1988;259:2263–6.
- [51] Defoor W, Minevich E, Sheldon C. Unusual bladder masses in children. *Urology* 2002;60: 911–3.
- [52] Ronnefarth G, Misselwitz J. Nephrocalcinosis in children: a retrospective survey. *Pediatr Nephrol* 2000;14:1016–21.
- [53] Moxey-Mims MM, Stapleton FB. Hypercalciuria and nephrocalcinosis in children. *Curr Opin Pediatr* 1993;5:186–90.
- [54] Alon US. Nephrocalcinosis. *Curr Opin Pediatr* 1997;9:160–5.
- [55] Schaller S, Kaplan BS. Acute nonoliguric renal failure in children associated with nonsteroidal antiinflammatory agents. *Pediatr Emerg Care* 1998;14:416–8.
- [56] Whelton A. Renal effects of over-the-counter analgesics. *J Clin Pharmacol* 1995;35:454–63.
- [57] Klein AJ, Kozar RA, Kaplan LJ. Traumatic hematuria in patients with polycystic kidney disease. *Am Surg* 1999;65(5):464–6.
- [58] Kalia A, Travis LB, Brouhard BH. The association of idiopathic hypercalciuria and asymptomatic gross hematuria in children. *J Pediatr* 1981;99:716–9.
- [59] Roy S, Stapleton FB, Noe HN, Jerkins G. Hema- turia preceding renal calculus formation in children with hypercalciuria. *J Pediatr* 1981;99:712–5.
- [60] Stapleton FB. Childhood stones. *Endocrinol Metab Clin North Am* 2002;31:1001–15.
- [61] Frick KK, Bushinsky DA. Molecular mechanisms of primary hypercalciuria. *J Am Soc Nephrol* 2003; 14:1082–95.
- [62] Parekh DJ, Pope JC, Adams MC, Brock JW. The association of an increased urinary calcium-to- creatinine ratio, and asymptomatic gross and micro- scopic hematuria in children. *J Urol* 2002;167:272–4.
- [63] Butani L, Berg G, Makker SP. Microhematuria after renal transplantation in children. *Pediatr Nephrol* 2002;17:1038–41.
- [64] Abou-Jaoude WA, Sugarman JM, Fallat ME, Casale AJ. Indicators of genitourinary tract injury

- or anomaly in cases of pediatric blunt trauma. *J Pediatr Surg* 1996;31:86–90.
- [65] Smith EM, Elder JS, Spirnak JP. Major blunt renal trauma in the pediatric population: is a non-operative approach indicated? *J Urol* 1993;149:546–8.
- [66] Shalaby-Rana E, Lowe LH, Blask AN, et al. Imaging in pediatric urology. *Pediatr Clin North Am* 1997;44:1065–89.
- [67] Pumberger W, Gindl K, Amann G, Geissler W. Polypoid fibro-haemangioma of the kidney in a child with gross haematuria. *Scand J Urol Nephrol* 1999;33:344–6.
- [68] Gleason PE, Kramer SA. Genitourinary polyps in children. *Urology* 1994;44:106–9.
- [69] Little PJ, Sloper JS, de Wardener HE. A syndrome of loin pain and hematuria associated with disease of peripheral renal arteries. *Q J Med* 1967;36:253–9.
- [70] Nicholls AJ, Muirhead N, Edward N, et al. Loin pain and haematuria in young women: diagnostic pitfalls. *Br J Urol* 1982;54:209–11.
- [71] Burke JR, Hardie IR. Loin pain haematuria syndrome. *Pediatr Nephrol* 1996;10:216–20.
- [72] Fletcher P, Al-Khader AA, Parsons V, Aber GM. The pathology of intrarenal vascular lesions associated with the loin-pain-hematuria syndrome. *Nephron* 1979;24:150–4.
- [73] Kelly B. Psychological aspects of loin-pain/haematuria syndrome. *Lancet* 1992;340:1294.
- [74] Kelly B. Psychiatric issues in the “loin pain and haematuria syndrome”. *Aust N Z J Psychiatry* 1994;28:302–6.
- [75] Gusmano RG. Could this be loin pain hematuria syndrome? *Pediatr Nephrol* 1998;12:800–1.
- [76] Walker BR, Ellison ED, Snow BW, Cartwright PC. The natural history of idiopathic urethrorrhagia in boys. *Pediatr Nephrol* 2001;16:232–7.