


# Critical Role of Intraoperative Neurophysiologic Monitoring (IONM) in the Early Detection of Cerebrovascular Ischemia: Case Report from the Endovascular Suite

Eric Jones, R EEG T/EP T, CNIM, CLTM<sup>1</sup>, Dru Sigmon, CNIM<sup>1</sup>, Huy Do, MD<sup>3</sup>, Jaime López, MD<sup>2</sup>, Viet Nguyen, MD<sup>2</sup>, Leslie Lee, MD<sup>2</sup>

<sup>1</sup>Neurodiagnostic Labs, Stanford Hospital and Clinics, Stanford, CA

<sup>2</sup>Department of Neurology and Neurological Sciences, <sup>3</sup>Department of Radiology, Stanford University School of Medicine, Stanford, CA



## Introduction

Intraoperative neurophysiologic monitoring (IONM) in the endovascular suite presents the technologist with many unique challenges. Knowledge of neurovascular anatomy, available interventions, and safety considerations are essential for successful monitoring.

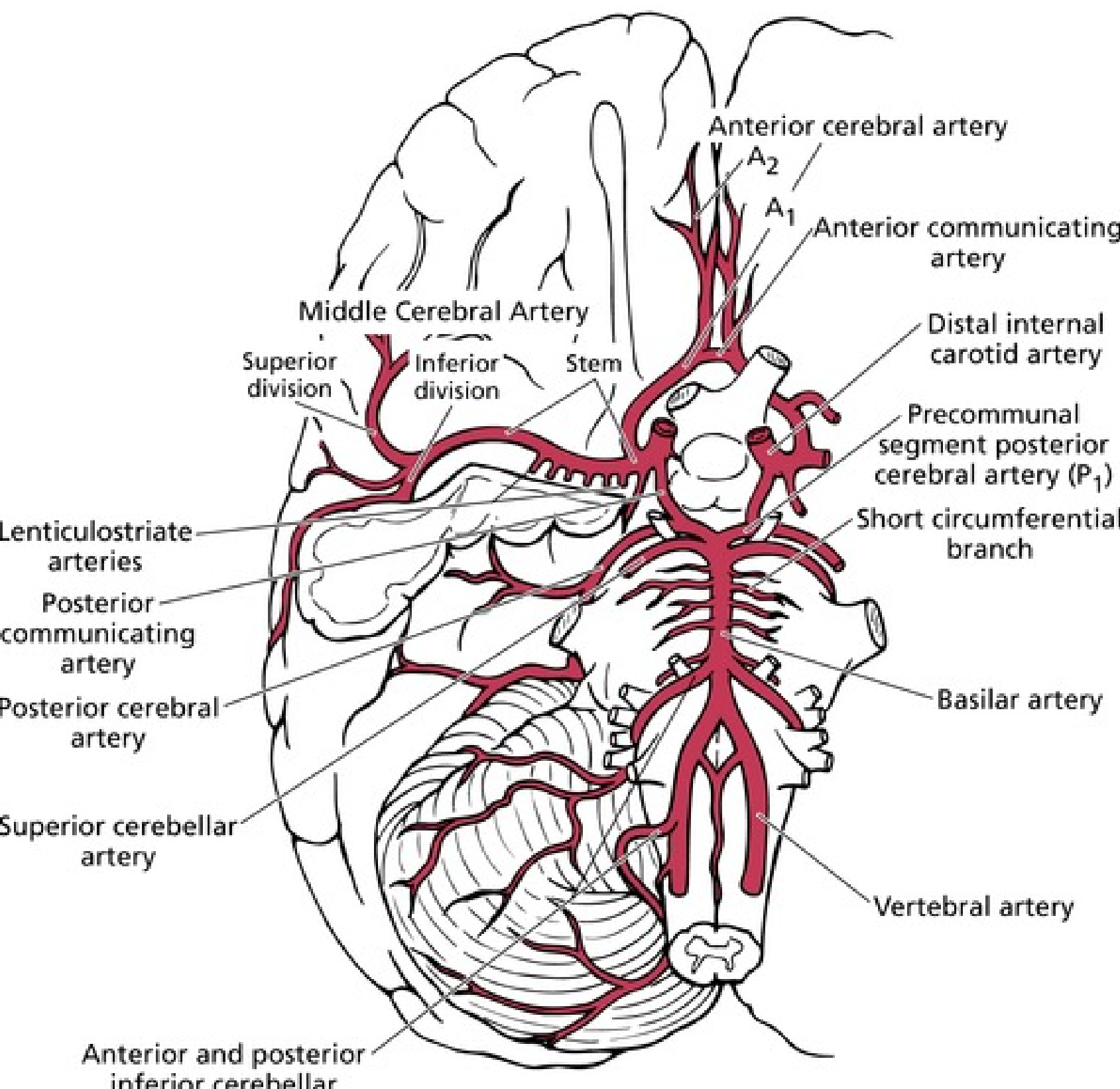


Figure 1. Circle of Willis.

We present a case in which IONM played a critical role in the early recognition of cerebrovascular ischemia, enabling subsequent treatment interventions, and optimizing post-procedural patient outcome.

## Methods

A 32-channel Cadwell Cascade Elite system was used to monitor somatosensory evoked potentials (SSEPs) following upper and lower extremity stimulation over bilateral median and posterior tibial nerves, respectively. Eight channels of electroencephalography (EEG) were recorded utilizing a referential, parasagittal montage. We also monitored transcranial electrical motor evoked potentials (tcMEPs) recorded bilaterally from the abductor pollicis brevis-first dorsal interosseous complex (hand), tibialis anterior (TA) and abductor hallucis (foot) muscles.

Subdermal needle electrodes were placed at standard scalp montage and peripheral muscle sites after anesthesia induction and prior to the initial angiogram. Adhesive stimulation electrodes were placed at the median and posterior tibial nerve sites.

A 45 year-old gentleman developed the acute onset of headache and loss of consciousness. Imaging revealed a tri-lobed anterior communicating artery aneurysm (AComm) with neck measuring 3.5 mm and secondary subarachnoid hemorrhage.

The aneurysm was felt to be amenable to endovascular treatment, and the patient was brought to the endovascular suite for coiling. IONM was requested for the procedure.

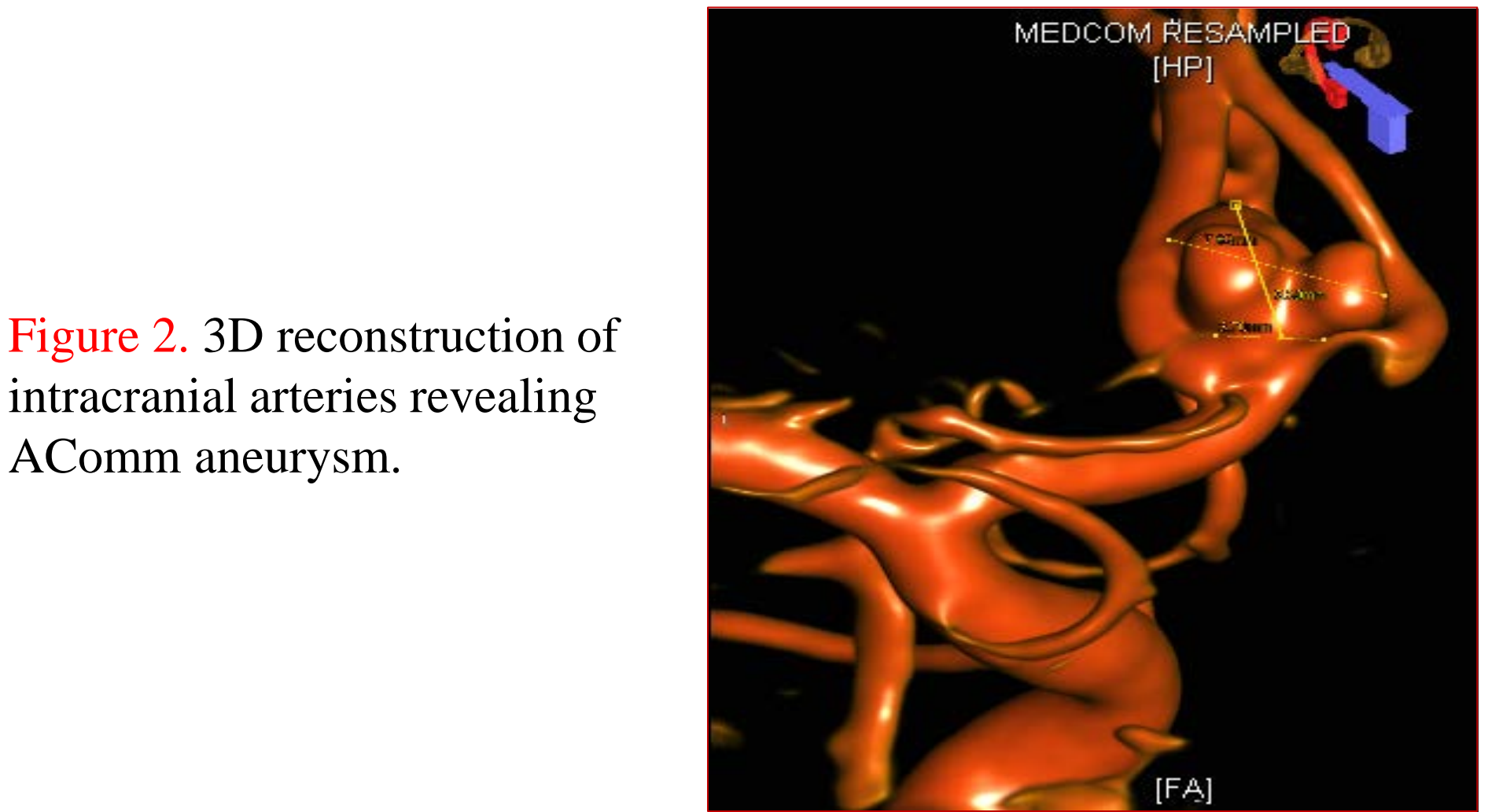


Figure 2. 3D reconstruction of intracranial arteries revealing AComm aneurysm.

Preoperatively, reproducible upper extremity and lower extremity SSEP's and MEP's were obtained bilaterally. EEG symmetry was noted.

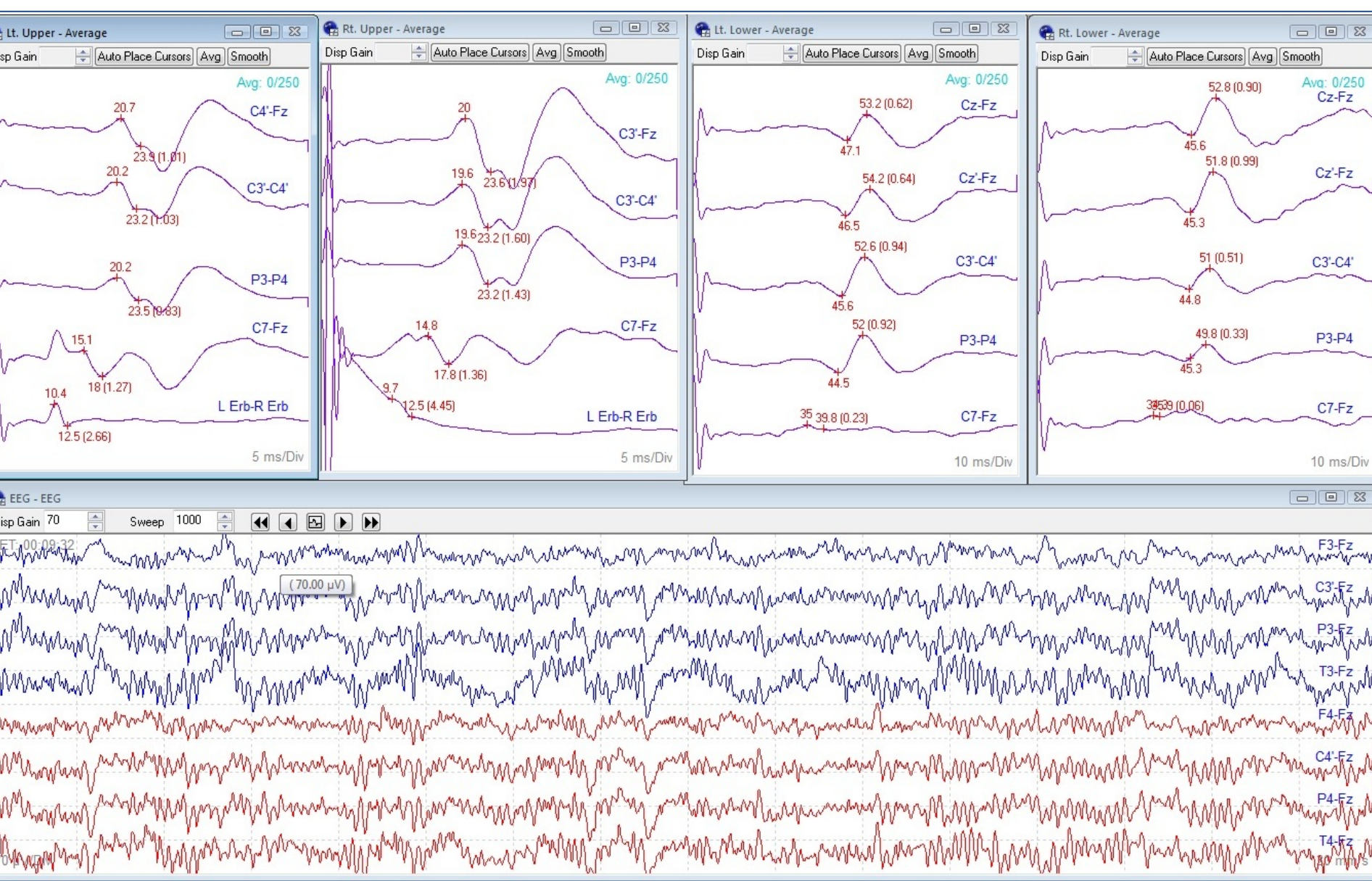


Figure 3. Baseline SSEPs and EEG.

Neuromuscular blocking agent was administered, per radiologist's request, prior to baselines and intermittently throughout the procedure. Reproducible tcMEPs were elicited at 300 Volts, with slightly variable responses.

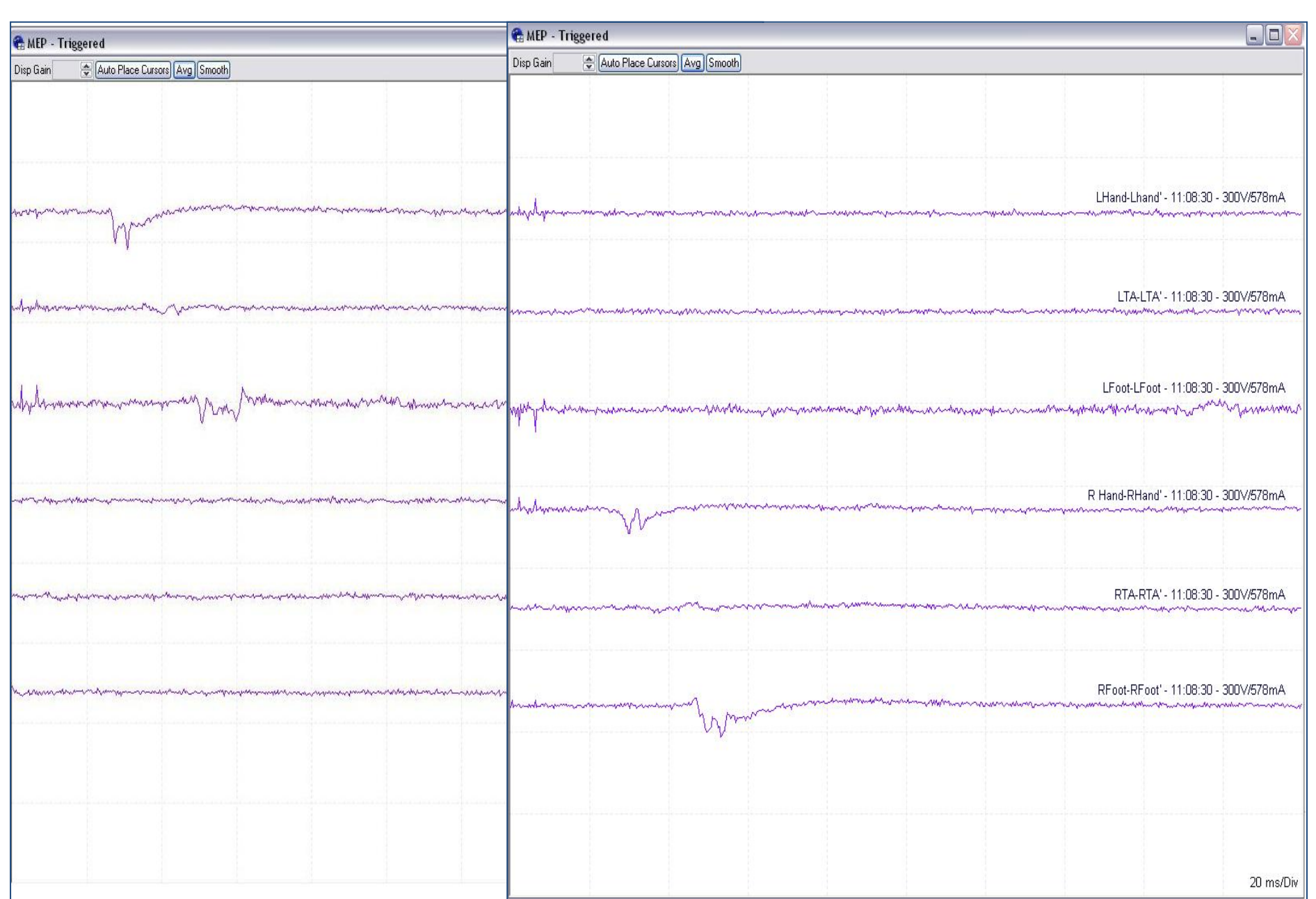


Figure 4. Baseline left tcMEPs (left) and right tcMEPs (right). These remained consistent throughout the case.

## Case Report

EEG remained symmetric and SSEPs remained unchanged throughout the coiling procedure. Anesthesia (isoflurane, nitrous oxide, remifentanyl) was stable during the case.

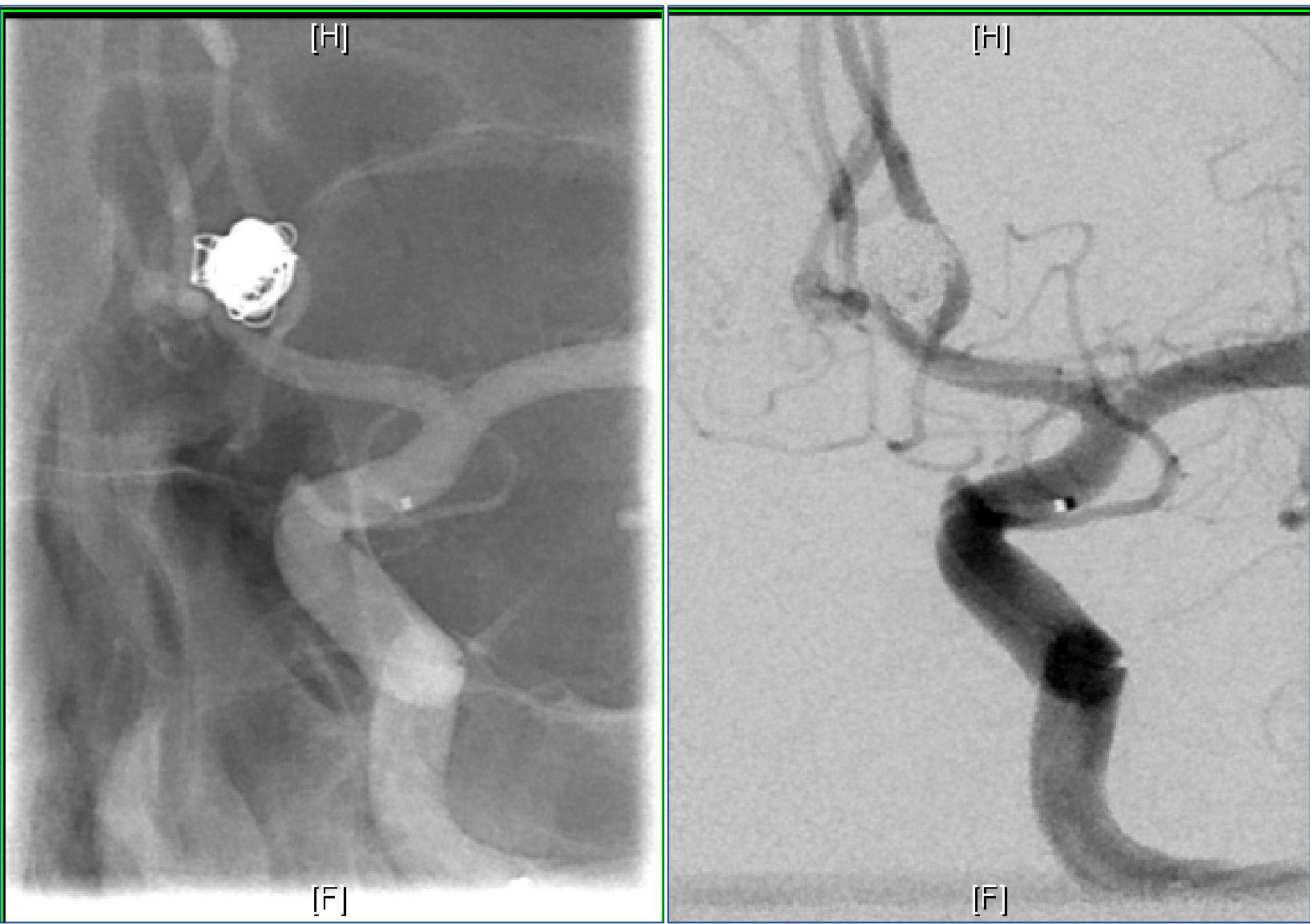


Figure 5. Post-coiling angiograms.

During the post-coiling angiogram, an isolated focal change involving the right lower extremity (RLE) SSEP was identified. No EEG or tcMEP changes were noted.

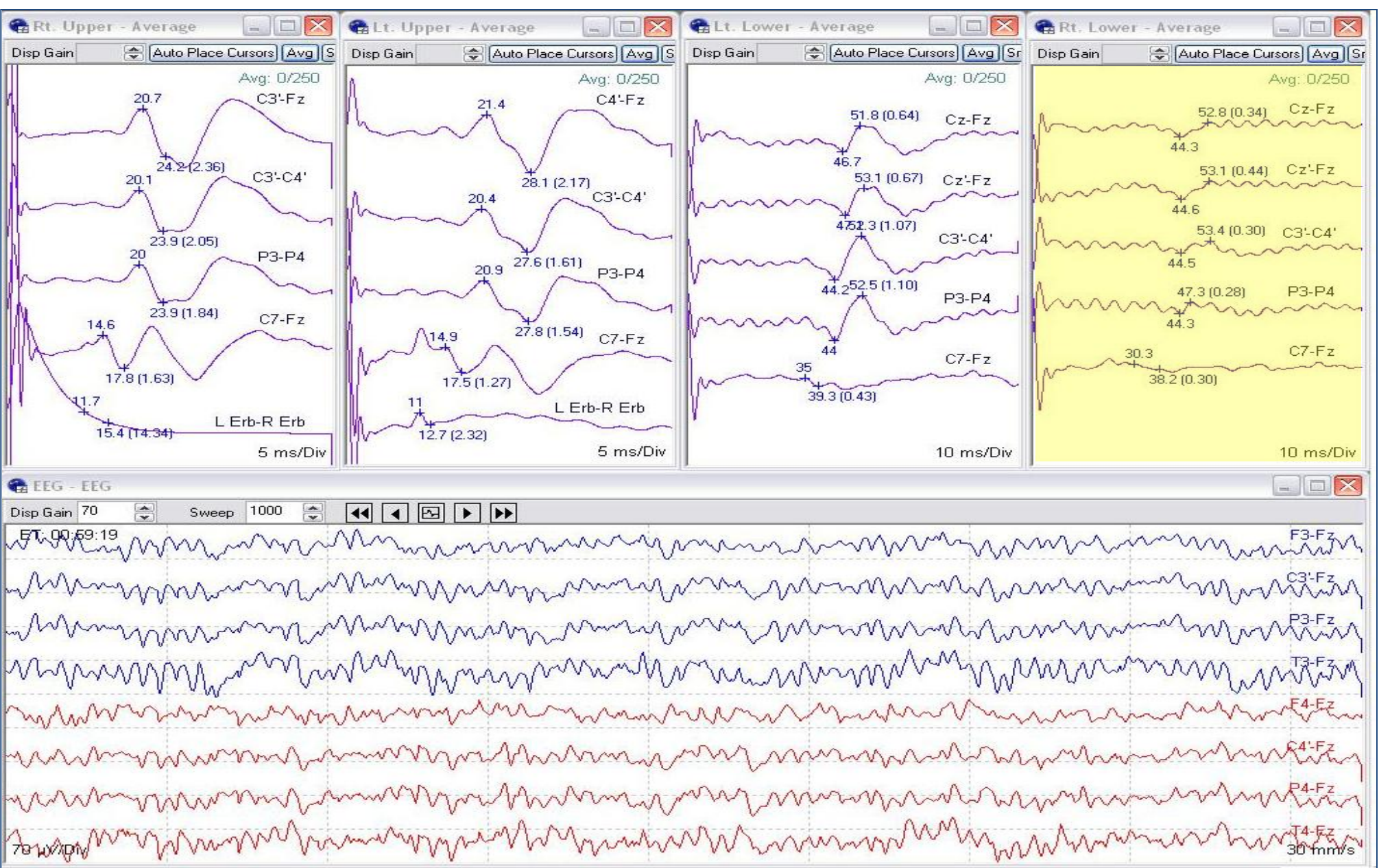


Figure 6. Focal RLE SSEP amplitude decrease of 50%.

This critical IONM change was reported to the supervising attending neurologist and Interventional Radiology (IR) team. Consequently, additional imaging was performed which revealed a thrombus causing occlusion of the left anterior cerebral artery (ACA).

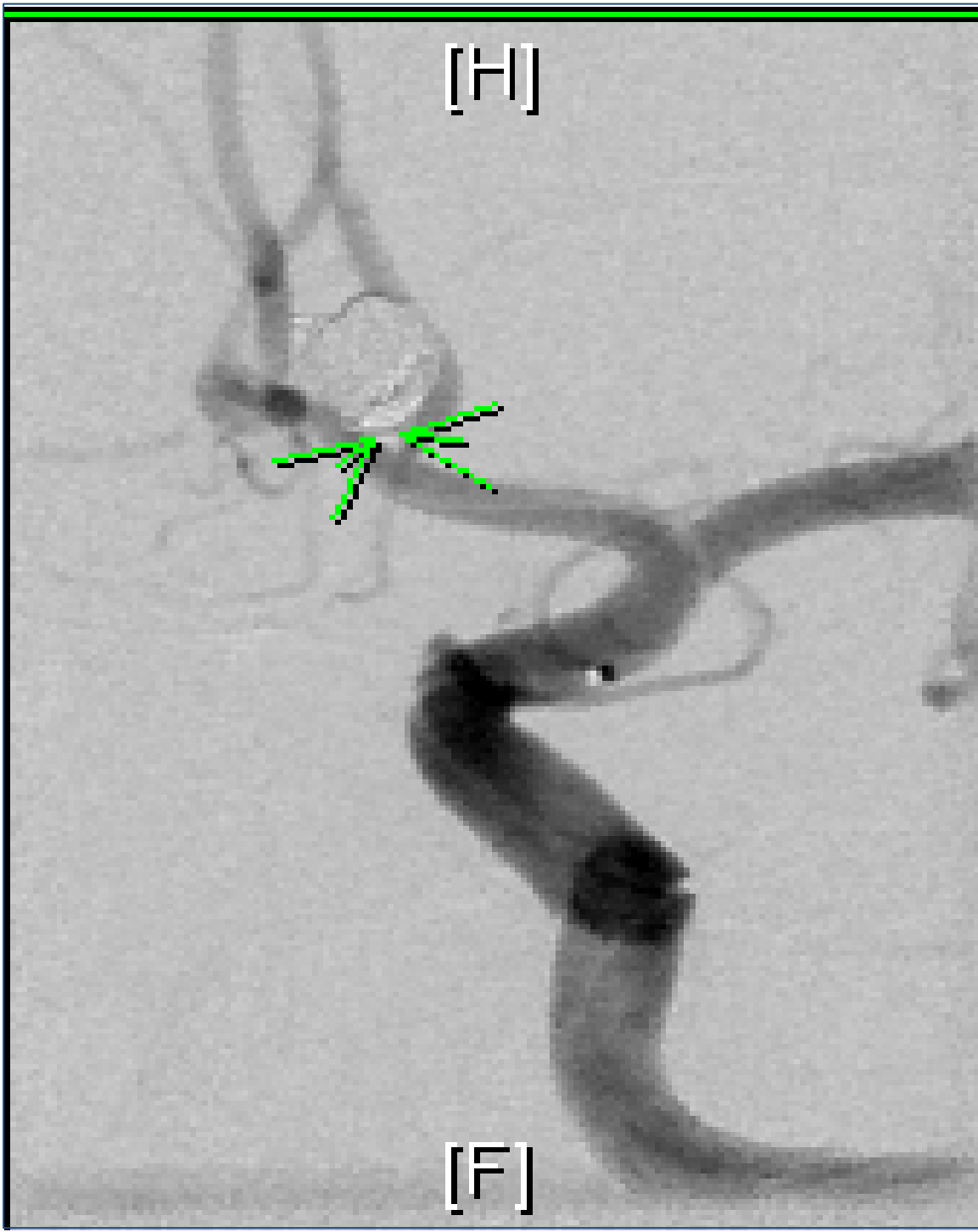

Figure 7. Protruding coil with thrombus at left ACA.

Immediate interventions were performed, including the administration of eptifibatide (Integrilin) and balloon-assisted coil remodeling.

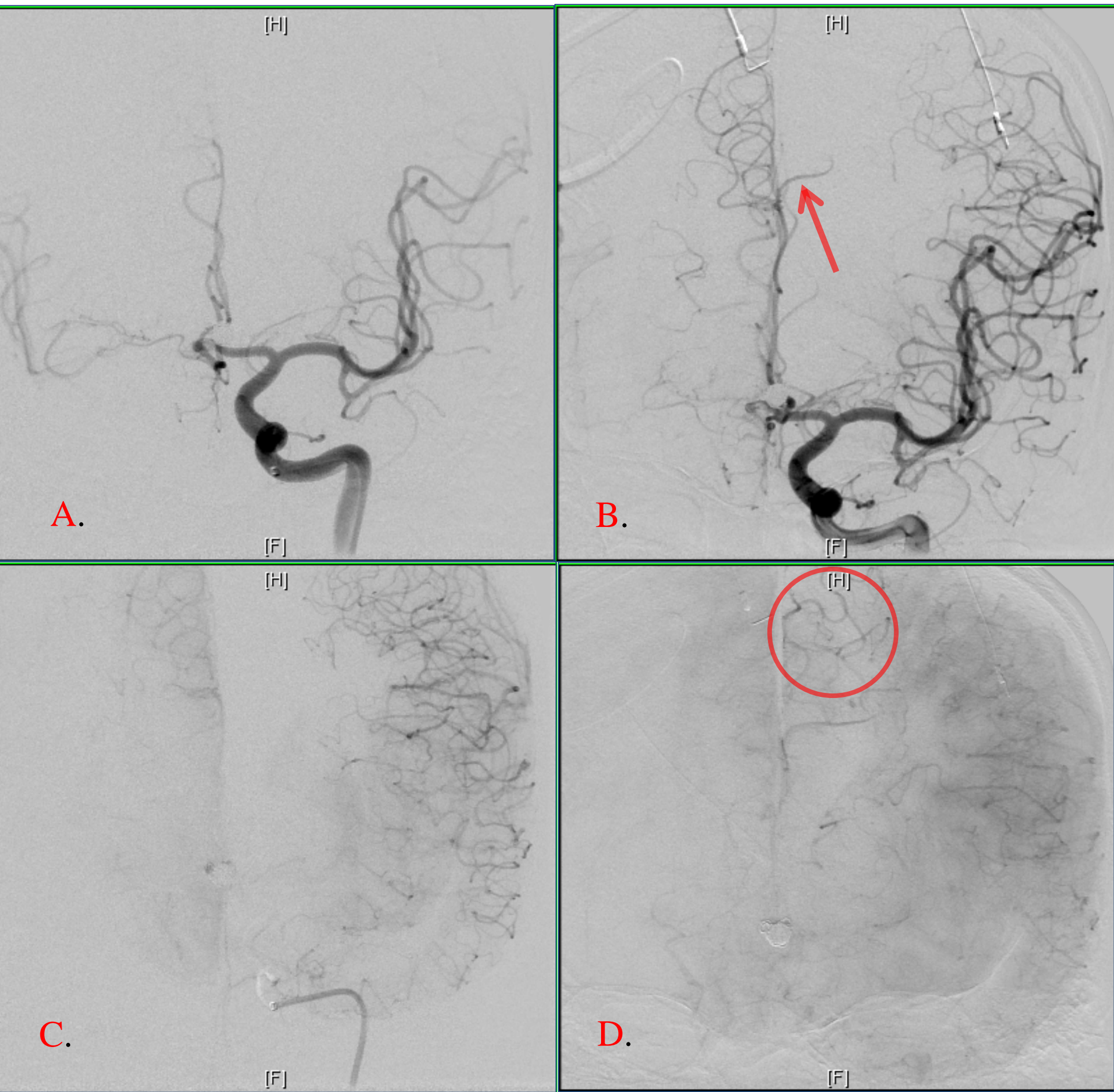


Figure 8. A and C. Angiograms showing thrombus causing left ACA occlusion. B and D. Angiograms showing resolution of thrombus (arrow) with restored flow (circle) to left ACA status-post administration of eptifibatide.

Within minutes after restoration of cerebral blood flow, the RLE SSEP returned to near-baseline amplitude. The patient awoke with no new post-procedural deficits.

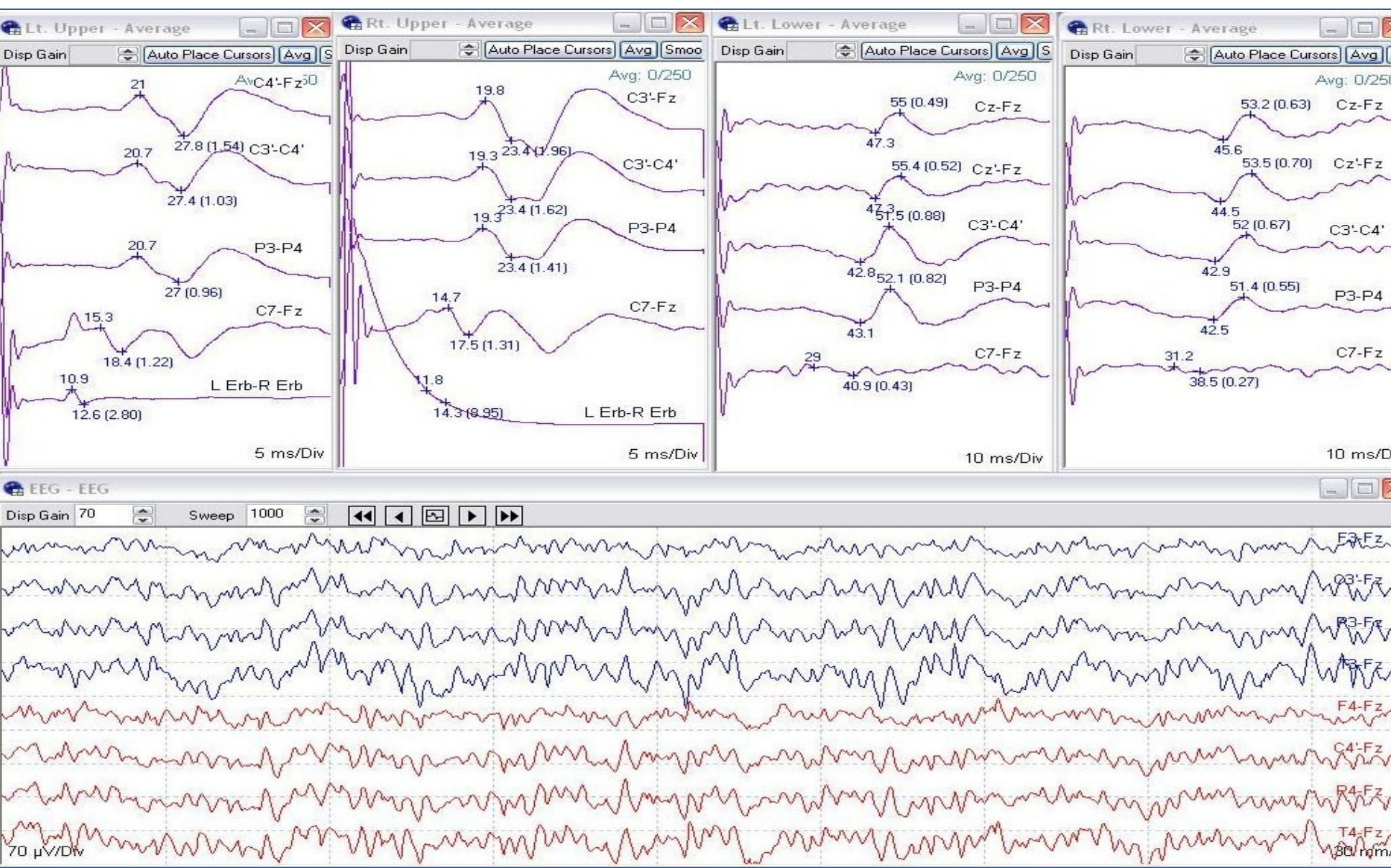


Figure 9. RLE SSEP return to near baseline.

The patient continued on an eptifibatide drip for 12 hours to prevent reformation of thrombus. As a consequence of the ongoing need for antiplatelet therapy, there was prolonged bleeding after removal of the subdermal needles at the scalp.

## Discussion

- We emphasize the critical role of IONM in identifying early signs of cerebral ischemia for endovascular cases.
- Knowledge of neurovascular anatomy is critical for the technologist when monitoring in the endovascular suite. In the case discussed here, being aware of cerebral and vascular structures at risk, and the significance of associated changes in neurophysiologic monitoring parameters, aided in the detection of early ischemic changes that were amenable to prompt intervention.
- Utilizing a multimodality monitoring approach is advantageous in that it allows for redundancies. SSEPs, EEG, and tcMEPs are all valuable tools in detecting ischemia. In this case we observed a focal RLE SSEP change, without associated EEG or tcMEP changes. Monitoring EEG or tcMEPs alone, for example, would not have detected the neurophysiologic changes observed in this case.
- Patient safety should be considered a priority when monitoring in the endovascular suite. Patients may require aggressive antiplatelet therapy which can exacerbate bleeding or even lead to hematomas when subdermal needle electrodes are used. Special care should be taken, and alternate non-invasive electrodes used during the setup in these instances. The patient in this case was not receiving antiplatelet agents prior to this procedure. However, during the intervention, an eptifibatide drip was administered that resulted in the potential for excessive bleeding at the scalp from subdermal needle sites post-procedurally. As this was an unexpected intervention during the procedure, it is important for the technologist to help prevent and to be prepared for potential bleeding events, measures which in this case included application of a pressure dressing head wrap and frequent assessments.

## Acknowledgements

Special thanks to Mark Burdelle, R. EEG/EP T, Stanford Medical Center Neurodiagnostic Lab Manager