

CHAPTER TWENTY *Intraaortic*

Balloon

Down

Counterpulsation

11

CHAPTER TWENTY *Intraaortic*

The most common form of mechanical circulatory support is provided by counterpulsation using an intraaortic balloon pump (IABP). Three general methods are used to trigger the cycling period of the IABP. The most common triggering source is the ECG waveform. With ECG triggering, the balloon inflates on the T wave (onset of diastole) and deflates on the R wave (end of diastole, onset of systole). If the ECG signal is inconsistent, for example, because of electrical artifacts produced by the electrosurgical unit in the operating room, the arterial pressure waveform can be used as the trigger, with balloon inflation set at the dicrotic notch and deflation set just prior to the systolic pressure upstroke. Finally, the IABP can be set to cycle independently at a fixed rate in the absence of intrinsic cardiac electrical (ECG) or mechanical (arterial pressure) activity. This manual or internal mode of IABP triggering might be selected to provide some degree of pulsatile flow during nonpulsatile cardiopulmonary bypass.

The physiologic benefits of IABP counterpulsation are ascribed to both an increase in diastolic coronary perfusion and decrease in systolic left ventricular afterload. By inflating during diastole, the balloon augments diastolic aortic pressure and coronary perfusion pressure, thereby helping to relieve myocardial ischemia. Balloon deflation immediately prior to onset of systole reduces left ventricular afterload, thereby aiding ventricular ejection and increasing stroke volume and cardiac output.^{3,4,7} Finally, counterpulsation reduces left atrial pressure and causes a reflex slowing of the heart rate, which may further improve myocardial oxygen balance.⁴ Thus, counterpulsation should ameliorate myocardial ischemia, both through an increase in oxygen supply during diastole and a decrease in oxygen demand during systole.

Recent physiologic investigations have questioned the precise mechanism by which the IABP exerts its beneficial clinical effects. Kimura et al² have shown that the increased diastolic aortic pressure generated by the IABP is not transmitted effectively beyond a severe coronary stenosis and consequently does not lead to an increase in distal flow in diseased coronary vessels. Using transesophageal echocardiography in patients undergoing cardiac surgery, Cheung et al¹ have shown that the predominant acute effect of counterpulsation is a reduction in left ventricular systolic wall stress. Both of these studies point to the important role of afterload reduction as the mechanism by which the beneficial effects of the IABP are realized. Since optimal timing of the IABP is required in order to provide successful afterload reduction, this chapter provides a detailed consideration of IABP timing guided by arterial blood pressure monitoring.

IABP TIMING

Timing of balloon inflation and deflation becomes critically important if the beneficial effects of counterpulsation are to be achieved and detrimental circulatory effects are to be

avoided. Although triggering of balloon inflation and deflation is often provided by the ECG, optimal timing of the balloon cycle requires an arterial pressure trace, since the precise duration of the mechanical cardiac events of interest (systole and diastole) cannot be determined accurately from the electrical ECG signal alone. Balloon inflation should occur with closure of the aortic valve, which is marked by the dicrotic notch on the arterial pressure waveform (also see Ch. 8). Balloon deflation should occur just prior to aortic valve opening and the systolic pressure upstroke (Fig. 20.1). When timed properly, balloon inflation during diastole will raise mean diastolic pressure, and balloon deflation prior to systole will lower peak systolic pressure as well as reduce the pressure at onset of systolic ejection. In most patients, the increment in diastolic pressure will exceed the decrement in systolic pressure, and as a result, mean arterial pressure will increase (Fig. 20.1).

The arterial blood pressure waveform thus assumes a characteristic morphology when the IABP is in place and properly timed during the cardiac cycle (Figs. 20.1 and 20.2; compare Fig. 8.1). The most notable feature of the arterial waveform is the double pressure peak that occurs with each cardiac cycle. The first peak corresponds to the normal systolic pressure peak, and the second results from balloon inflation during diastole. In most instances, the diastolic pressure peak, termed the *augmented diastolic pressure*, exceeds the systolic pressure peak. Note that balloon inflation occurs at the dicrotic notch, producing a sharp V shape, while balloon deflation occurs at end-diastole, creating an end-diastolic or *presystolic dip* and a reduced peak systolic pressure following balloon deflation (Fig. 20.2). Both the presystolic dip and the reduced peak systolic pressure are the hallmarks of successful afterload reduction.

It should now be evident that accurate IABP timing requires the clinician to examine both balloon-assisted beats as well as unassisted beats, in order to recognize all of the pertinent morphologic changes introduced in the arterial pressure waveform. *Consequently, balloon timing always should be adjusted with every other beat assisted by the balloon, generally termed a balloon-assist ratio of 1:2.* In the examples in Figures 20.1 and 20.2, this pattern of a 1:2 balloon-assist ratio is readily apparent. Note all of the important arterial pressure waveform changes described above: a steep rise in diastolic pressure beginning at the dicrotic notch, an augmented diastolic pressure peak exceeding systolic pressure, a presystolic pressure dip, and an ensuing peak systolic pressure that is lower than the systolic pressure generated following an unassisted beat (Fig. 20.2). After balloon timing has been adjusted to achieve these goals, the IABP-assist interval can be increased to 1:1, thereby providing maximal hemodynamic support to the patient.

The digital display of arterial blood pressure values on the bedside monitor may be confusing when a patient is receiv-

ing IABP support. First, the pressure displayed as "systolic" arterial pressure may be the diastolic augmented pressure peak rather than the true blood pressure during systole. This occurs when the algorithm in the bedside monitor inappropriately identifies the diastolic pressure peak as the systolic pressure peak, owing to its being the highest pressure during the cardiac cycle. In addition, the pressure displayed as "diastolic" pressure may be the presystolic dip or nadir pressure produced by IABP deflation. This extremely low "diastolic" pressure value belies the fact that mean diastolic pressure is actually very high because of balloon inflation during this portion of the cardiac cycle. In the example in Figure 20.2, the bedside monitor displays a blood pressure of 126/18 mmHg and erroneously records the diastolic augmented pressure as the "systolic" pressure and the presystolic nadir pressure as the "diastolic" pressure.

Although some monitors have a "smart" IABP pressure monitoring mode, the digital values for systolic and diastolic pressure may be misleading, and it is best to focus simply on mean arterial pressure. During intraaortic balloon counterpulsation, mean arterial pressure should remain accurate and continue to provide the most reliable estimate for overall systemic arterial perfusion pressure. As mentioned earlier, *properly timed IABP counterpulsation will augment mean diastolic pressure more than it reduces systolic pressure, resulting in a small increase in mean arterial pressure in most patients.*³

IABP TIMING PROBLEMS

By scrutinizing the arterial blood pressure trace, one should be able to determine whether balloon inflation and deflation are timed optimally during the cardiac cycle. Timing errors fall into four different categories: early inflation, late inflation, early deflation, and late deflation (Fig. 20.3). When the balloon is *inflated too early*, aortic pressure rises prematurely, before aortic valve closure and before inscription of the dicrotic notch in the arterial pressure trace. As a result, the left ventricle is forced to empty against an increased pressure or afterload, resulting in premature aortic valve closure, and consequently, reduced systolic ejection, stroke volume, and cardiac output. In contrast, *late balloon inflation* shortens the duration of diastolic augmentation in aortic pressure and diminishes the potential benefit provided by the balloon in augmenting coronary perfusion pressure. Late inflation of the IABP is recognized by the delayed rise in diastolic pressure, which occurs after the dicrotic notch and gives a U shape to the pressure rise rather than the ideal sharp V shape described above. Note that late inflation provides suboptimal IABP support, while early inflation may actually worsen the patient's condition because of the unintended increase in left ventricular afterload.

Like late balloon inflation, *early balloon deflation* diminishes the potential beneficial effects of balloon counterpul-

sation, because the duration of diastolic augmentation in aortic pressure is reduced. Early deflation may also cause a reduction in aortic pressure during diastole and thereby promote retrograde flow from the brachiocephalic and coronary arteries into the aorta.³ Finally, early balloon deflation allows aortic pressure to rise to the normal unassisted end-diastolic value, prior to onset of systole. As a result, left ventricular afterload reduction does not occur. Inspection of the arterial pressure trace reveals this timing problem. The presystolic dip is no longer evident, and arterial pressure actually rises from its mid-diastolic nadir value to a higher pressure at end-diastole. Thus, the peak systolic pressure following a balloon-assisted beat is no lower than the peak systolic pressure generated after an unassisted beat, and afterload reduction is not realized.

The final timing problem is *late balloon deflation*. Like early inflation, late deflation may actually worsen the patient's condition by forcing the left ventricle to begin its ejection against an increased afterload imposed by the inflated balloon. When the balloon is not deflated appropriately at end-diastole, the arterial pressure trace will not display the normal presystolic dip in pressure, and instead, the arterial pressure at end-diastole is higher than that seen in an unassisted beat. Furthermore, the ensuing peak systolic pressure may be severely reduced, not because of afterload reduction, but resulting instead from failure of left ventricular ejection produced by excessive afterload imposed by the inflated aortic balloon.

In summary, proper timing of IABP inflation and deflation can be determined by careful observation of the arterial pressure waveform with a balloon-assist ratio of 1:2. Although late balloon inflation and early balloon deflation limit the therapeutic benefits of counterpulsation therapy, early balloon inflation or late balloon deflation are *unsafe* and may worsen the patient's medical condition because of increased left ventricular afterload resulting from balloon inflation during systole.

IABP TIMING: INFLUENCE OF PRESSURE MONITORING SITE

Current intraaortic balloons have a central lumen that permits direct arterial pressure monitoring from the balloon tip located in the proximal portion of the descending thoracic aorta (Fig. 20.4). Although the site of arterial pressure monitoring used for IABP timing has not been specified in the previous discussion, the central aortic pressure is the preferred site for optimal IABP timing. Alternatively, radial artery pressure monitoring should yield similar results. In both situations, the monitored pressures are recorded from sites above or proximal to the balloon and provide an estimate of aortic root pressure during diastole, when the balloon is fully inflated and nearly occluding the descend-

ing thoracic aorta (Fig. 20.4).⁷ In most clinical situations, the central aortic pressure is displayed on the IABP console, and timing adjustments are guided by this pressure waveform. If the radial artery pressure is used for IABP timing, some authors have suggested that balloon inflation should appear approximately 50 msec earlier in this pressure waveform than it would in a central aortic pressure trace.^{3,5} Presumably, this results from the IABP inflation pressure wave reaching the radial artery catheter slightly before the aortic valve would normally be inscribed. This small timing difference appears to be of minor importance in clinical practice. Consequently, radial artery pressure waveforms closely resemble central aortic pressure waveforms when the two are recorded simultaneously during IABP counterpulsation.

In contrast to radial artery pressure monitoring, femoral artery pressure monitoring presents unique problems in determining proper balloon timing. Unlike pressure monitoring from the IABP central lumen or radial artery, femoral artery pressure is recorded below or distal to the balloon, and the IABP pressure wave will arrive at the femoral recording site significantly earlier than the arterial pressure wave that originates from the heart (Fig. 20.4). As a result, the balloon inflation pressure wave arrives at a femoral artery recording site noticeably early, prior to the aortic valve closure, and gives the appearance of early balloon inflation. In the example in Figure 20.5, balloon inflation appears approximately 60 msec earlier than the apparent aortic valve closure. Although some authors have suggested that balloon inflation should be set to occur as much as 120 msec prior to the appearance of the aortic valve closure in the femoral artery pressure trace,^{3,5,6} the safety of this timing method is not well established and introduces the theoretical risk that the balloon would be inflated prior to aortic valve closure. Thus, a more prudent approach to femoral artery timing of the IABP is to trigger balloon inflation approximately 40 to 80 msec prior to the position of the aortic valve closure in the femoral artery pressure trace.

Another consideration with femoral artery pressure monitoring is that balloon inflation produces occlusion or near-

occlusion of the descending thoracic aorta, and consequently, the arterial vasculature is separated into two separate systems during diastole, one above and one below the balloon, each with different runoff characteristics. Although the pressures recorded above and below the balloon may be nearly identical when the IABP is in place but turned off, these pressures may be quite different when the IABP is on and the arterial vasculature is separated into these two distinct proximal and distal vascular beds. In the example in Figure 20.6, femoral artery pressure (102/48 mmHg, mean 66 mmHg) and radial artery pressure (108/48 mmHg, mean 68 mmHg) are essentially equal until 1:1 IABP counterpulsation begins. At this point, radial and femoral artery pressure traces take on different appearances, and the mean radial artery pressure (80 mmHg) exceeds the mean femoral artery pressure (70 mmHg) (Fig. 20.6). This highlights the functional separation of the arterial vasculature located above and below the balloon and underscores the fact that central aortic or radial artery pressure monitoring provides a better estimate of proximal aortic root pressure in these patients. Note also that balloon inflation appears 80 msec earlier in the femoral artery trace than in the radial artery trace in this example (Figs. 20.6 and 20.7), owing to the anatomic considerations related to these different monitoring sites described earlier.

Pressure monitoring from the femoral artery may also be subject to high-frequency artifacts, which distort the pressure signal and make IABP timing difficult. Owing to the proximity of the IABP drive line in the distal aorta, when the IABP is set in motion, the femoral artery pressure trace may display high-frequency artifacts associated with balloon movement during inflation and deflation (Figs. 20.6 and 20.7). These artifacts may distort the central aortic pressure trace as well (Fig. 20.8) but rarely compromise the fidelity of the radial artery pressure trace (Figs. 20.6 and 20.7). These artifacts arise from the motion of the IABP balloon and drive line during balloon inflation and deflation and are more readily transmitted to the central aortic pressure lumen or a nearby femoral or iliac artery catheter than the more remote radial artery catheter.

Illustrations for Intraaortic Balloon Counterpulsation

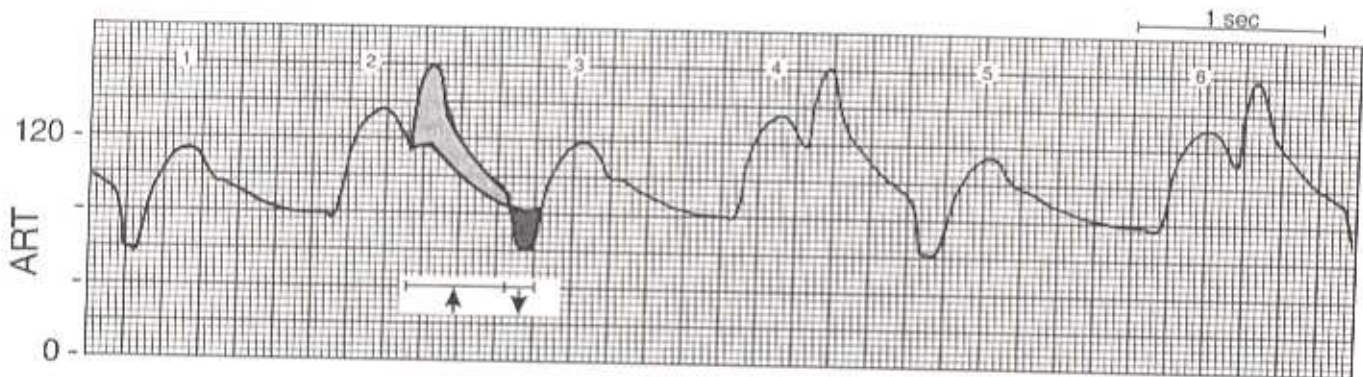


Figure 20.1 Intraaortic balloon counterpulsation produces a characteristic alteration in the arterial blood pressure (ART) waveform. With a balloon-assist ratio of 1:2, balloon inflation during every other heart beat creates a double peaked waveform (beats 2, 4, and 6). Properly timed balloon inflation beginning at the diastolic notch causes an increase in diastolic pressure throughout most of diastole (*up arrow, light shading*). Prior to the systolic upstroke in ART, balloon deflation produces a transient decrease in aortic pressure, thereby reducing the pressure at onset of systolic ejection and the systolic pressure peak of the following beat (*down arrow, dark shading*). (Note that the balloon remains deflated beyond the down arrow and until the next balloon inflation at the diastolic notch of beat 4.) This combination of effects results in an increased pressure gradient for coronary artery perfusion during diastole and left ventricular afterload reduction during systole. Note that the shaded areas of the diastolic portion of beat 2 illustrate the distortion in the ART waveform produced by the action of the intraaortic balloon pump, as well as the increase in mean arterial pressure resulting from counterpulsation. Compare beats 1, 3, and 5 with beats 2, 4, and 6. See text for more detail.

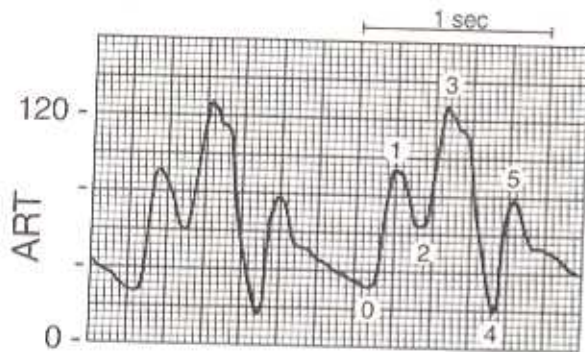


Figure 20.2 Characteristic arterial blood pressure (ART) waveform seen during intraaortic balloon counterpulsation with a 1:2 balloon-assist ratio. Four cardiac cycles are shown, two with balloon assistance and two without. Six points in the ART waveform are identified: (0) unassisted end-diastolic pressure (32 mmHg); (1) unassisted systolic pressure (92 mmHg); (2) aortic valve closure (64 mmHg); (3) assisted or augmented diastolic pressure (126 mmHg); (4) end-diastolic or presystolic dip (18 mmHg); and (5) assisted systolic pressure (78 mmHg). The actions of the intraaortic balloon create the augmented diastolic pressure and the presystolic dip and may cause the digital values displayed on the bedside monitor to be erroneous. Evidence for effective afterload reduction is provided by the observation that the presystolic dip (4) is lower than unassisted end-diastolic pressure (0), and the assisted systolic pressure peak (5) is lower than the unassisted systolic pressure peak (1). Compare these ART waveform components with those seen in a normal arterial pressure waveform (Fig. 8.1). See text for more detail.

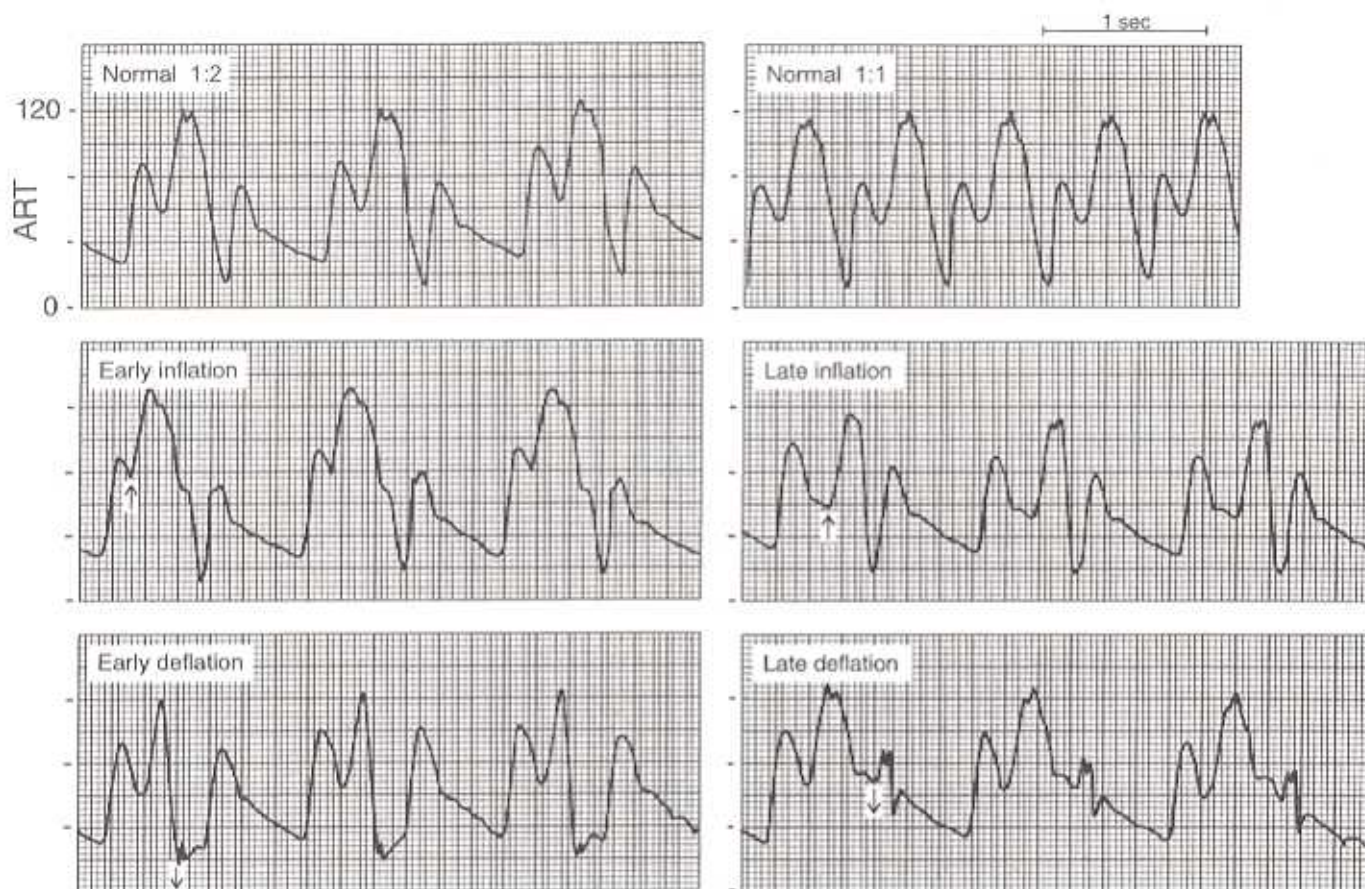
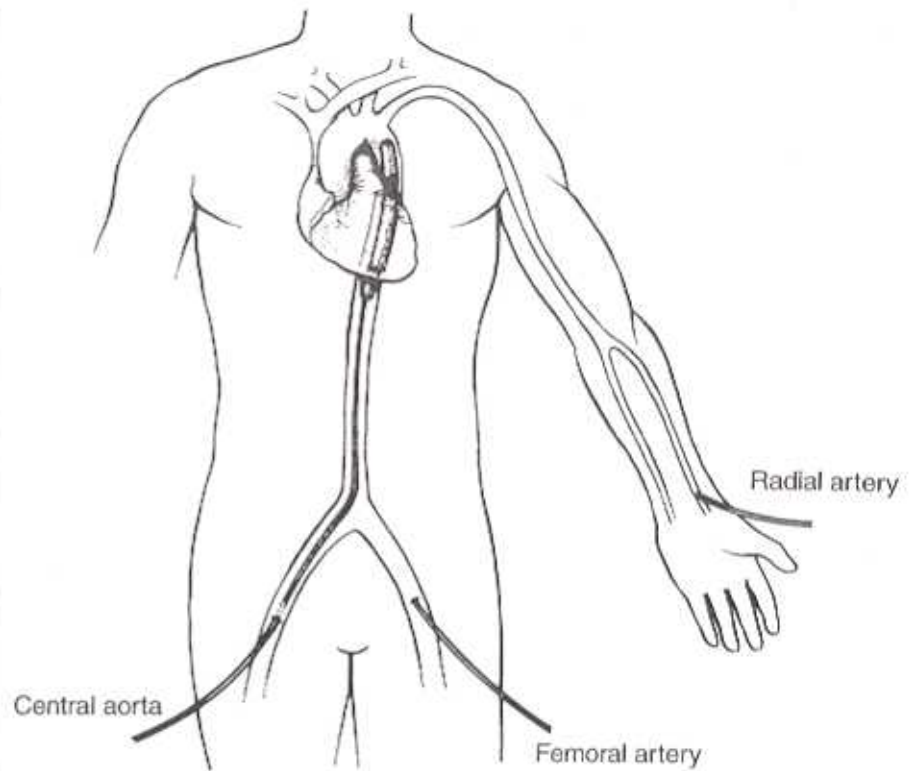


Figure 20.3 Intraaortic balloon counterpulsation timing problems. Arterial blood pressure (ART) waveforms during normal 1:2 and 1:1 counterpulsation are shown in the top two panels. Timing errors are shown in the other four panels. *Early inflation* (up arrow), prior to the normal diastolic notch, causes an increase in left ventricular afterload, premature aortic valve closure, and reduced systolic ejection. *Late inflation* (up arrow), after the diastolic notch shortens the duration of diastolic augmentation and may be recognized by the U shape of the diastolic pressure rise, rather than the normal V shape. *Early deflation* (down arrow) prior to end-diastole reduces the duration of diastolic augmentation and does not provide effective afterload reduction, because the presystolic dip in pressure is lost, aortic pressure rises to the normal unassisted end-diastolic value, and the ensuing systolic pressure peak is no lower than peak systolic pressure generated following an unassisted beat. *Late deflation* (down arrow) after the onset of systolic ejection results in an increased left ventricular afterload and diminished systolic ejection. This may be recognized by the absence of the presystolic pressure dip and the distorted systolic pressure peak that follows. Although late inflation and early deflation reduce the potential therapeutic benefits of counterpulsation, early inflation and late deflation may actually worsen the patient's condition, because balloon inflation during systole increases left ventricular afterload. The ART pressure scale is identical in all six panels. See text for more detail.

Figure 20.4 Three common sites for arterial pressure monitoring during intraaortic balloon counterpulsation. The preferred site is the central aorta monitored from the central lumen of the balloon, which records the pressure at its tip located in the proximal descending thoracic aorta. Another acceptable alternative is the radial artery, which monitors arterial pressure above or proximal to the balloon and provides another estimate for aortic root pressure. Femoral artery pressure monitoring is less desirable because it monitors pressure below or distal to the balloon. Proper balloon timing from a femoral artery pressure trace is more difficult because pressure waves resulting from balloon inflation will arrive at the femoral recording site earlier than pressure waves originating from the actions of the heart, making it difficult to identify optimal timing patterns. See text for more detail.



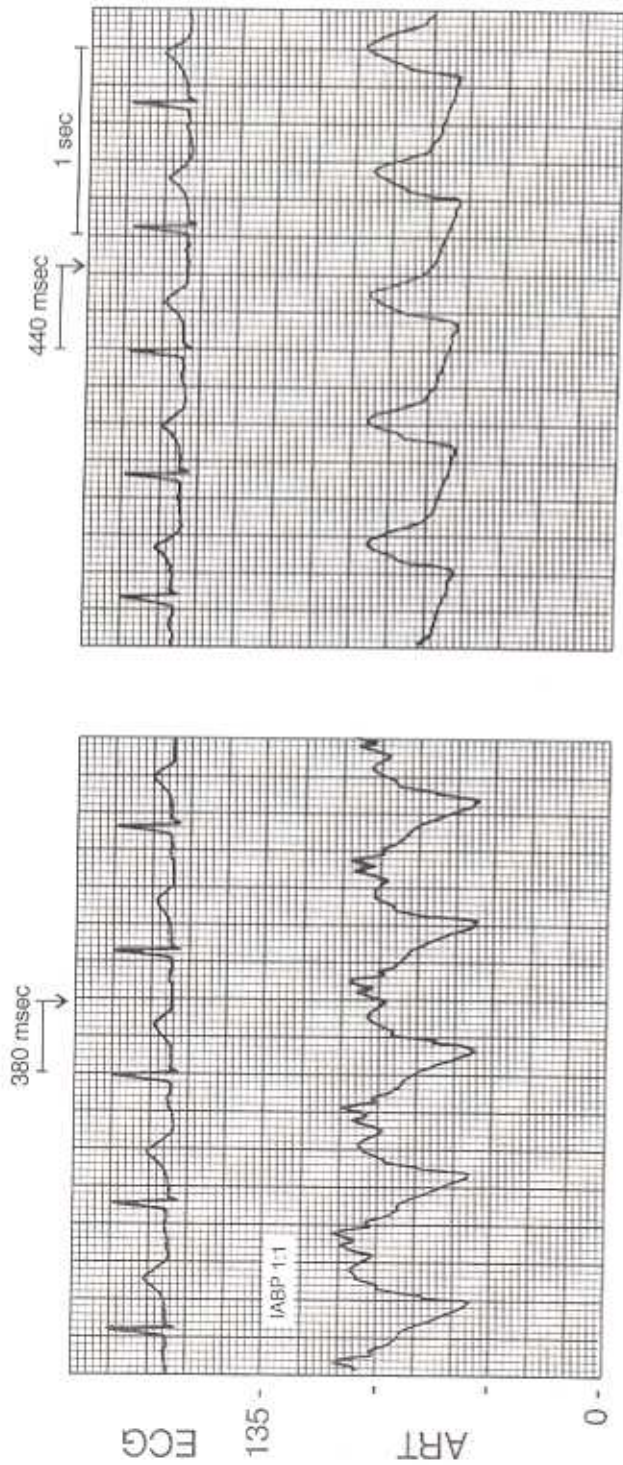


Figure 20.5 Femoral arterial blood pressure (ART) monitoring during 1:1 intraaortic balloon counterpulsation (IABP 1:1). Because the femoral ART is measured below or distal to the balloon, the balloon pressure wave arrives at this recording site significantly earlier than arterial pressure waves originating from the heart. Consequently, the femoral ART trace gives the appearance of early balloon inflation prior to the dirotic notch during 1:1 counterpulsation (*left panel*). Although the precise location of the dirotic notch in the femoral ART trace is hard to discern even with the balloon off (*right panel*), it appears that the balloon is inflating approximately 60 msec earlier than the dirotic notch would normally appear. Balloon inflation occurs 380 msec after the ECG R wave in the left panel, and the position of the dirotic notch appears closer to 440 msec after the ECG R wave in the right panel with the balloon pump off.