## Molecular Imaging Instrumentation Lab

(Craig Levin)


MIPS
Molecular Imaging Program at Stanford

Stanford University
School of Medicine
Department of Radiology

## Research interests (by imaging modality)

I. High resolution radionuclide imaging:
- positron emission tomography (PET)
- single photon emission computed tomography (SPECT)

II. Optical tomography:
- Bioluminescence tomography (BLT)
- Fluorescence tomography (FLT)

## Research interests (by imaging technology)

- New photon sensors
- Low noise electronics
- Data acquisition systems and software
- Computer simulation and modeling
- Image reconstruction algorithms
- Image analysis algorithms
- Integrating components into new imaging systems

MIPS
Molecular Imaging Program at Stanford

Stanford University
School of Medicine
Department of Radiology

## Two new radionuclide cameras under development

I. Miniature gamma ray camera for surgical cancer staging

II. Dedicated breast PET system to help resolve difficulties with breast cancer detection, diagnosis and staging

MIPS
Molecular Imaging Program at Stanford

Stanford University
School of Medicine
Department of Radiology

# I. Cancer staging problem

Localization and biopsy of "sentinel" lymph node is important for cancer staging (e.g. melanoma and breast cancer) to avoid unnecessary dissection of the lymphatic system

Sentinel node negative ⟶ Cancer has not spread

Identification of sentinel node requires:

- *Radiotracer that accumulates in node*
- *Pre-operative Lymphoscintigraphy*
- *Sensitive Radiation Detector Probe*



# Standard Non-imaging Radiation Detector Probe for Surgical Cancer Staging




Features:
- Audio tone generator
- LCD display
- Digital count readout
- Automated energy windowing

Neoprobe, Inc.



# Summary of the Sentinel Node Method

## Desirable characteristics

- High accumulation in the sentinel node(s)
- High detection sensitivity of the non imaging radiation detector
- Location of sentinel node(s) can be identified prior to any incisions

## Limitations of the method

- Poor labeling efficiency
- Inappropriate size of colloid particle
- Disruption of lymphatic flow
- Inappropriate injection dose or volume
- Procedure is time consuming and at times quite invasive
- Learning curve is significant
- Sentinel node is not identified during lymphoscintigraphy
- Node is within or near the injection site or bolus activity
- Node relatively deep within tissue
- Node cannot be distinguished from other secondary nodes or colloid migration path in lymphatic channels
- Node is too small or its activity is too low

COULD BE RESOLVED WITH A SMALL CAMERA

## Lymphoscintigraphy of the Sentinel Node

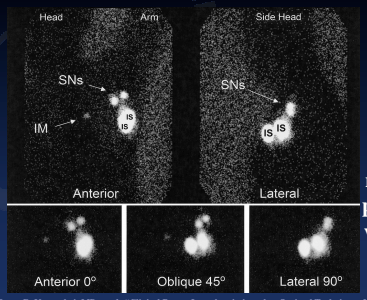


Challenging case: node could not be detected by non-imaging probe since it was too close to injection site

Borys R. Krynyckyi, MD, *et al.* "Clinical Breast Lymphoscintigraphy: Optimal Techniques for Performing Studies, Image Atlas, and Analysis of Image", Radiographics. 2004 Jan-Feb;24(1):121-45; discussion 139-45.

MIPS Molecular Imaging Program at Stanford

Stanford University School of Medicine Department of Radiology

## Miniature Gamma Ray Camera for Improved Surgical Staging of Cancer

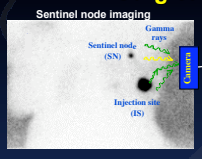


Small camera visualizes and measures gamma ray count rate variations from injected radio-colloid (5x5 cm² FOV)


Camera front-end assembly


Can visualize 3 mm nodes in 5 seconds!




Node detection studies

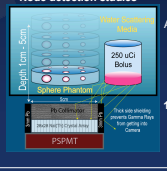


Nodes 3cm deep 4 cm deep

Acquis. Time 5 sec

10 sec

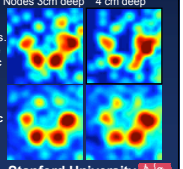

MIPS Molecular Imaging Program at Stanford

Stanford University School of Medicine Department of Radiology

## II. Difficulties with breast cancer detection, diagnosis and staging

**Detection**: ~ 25% of screened cases are inconclusive (due to dense/distorted tissue)

**Diagnosis**: Mammographic breast cancer signatures are only 20-30% specific
---> ~ 600,000 unnecessary biopsies are performed annually in this country ($1-3K)

**Staging**: Missed nodes and unnecessary axillary lymph node dissections
---> non-invasive techniques are needed

➔ Need to investigate sensitive, specific, non-invasive techniques

MIPS Molecular Imaging Program at Stanford

Stanford University School of Medicine Department of Radiology

## Can radionuclide imaging help with breast cancer screening/diagnosis/staging?

- Can the lesion/node be easily detected (high sensitivity)?
- Does the radiotracer has a very high affinity/accumulation for cancer/nodes (high specificity)?
- Is the cost of the imaging procedure reasonable?
- Can the study be performed reasonably quick?



## Drawbacks of the Standard PET Camera for Breast Imaging

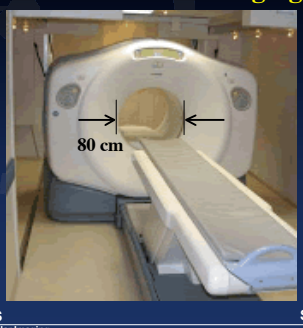




## Drawbacks of the Standard PET Camera for Breast Imaging

- Large and awkward for breast and axilla imaging
- Inability for close-proximity imaging ---> poor spatial resolution (6-12mm)
  ---> poor detection efficiency (<1%)
- Accepts activity from outside organs---> background haze
- Relative high cost per study

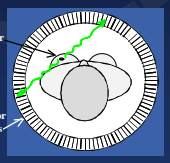


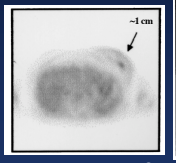


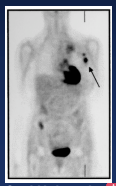

## PET camera dedicated to breast imaging

Potential Roles:

- Screening indeterminate cases?
- Reducing rate of false positives??
- Staging of axillary nodes?
- Detecting recurrence?
- Monitoring therapy?

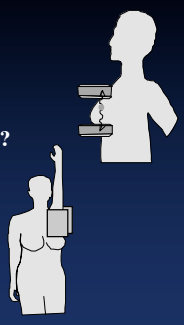

MIPS
Molecular Imaging Program at Stanford

Stanford University
School of Medicine
Department of Radiology

## PET camera dedicated to breast cancer imaging










Activity concentration ratio--Tumors:Breast:Heart:Torso=10:1:10:1

Breast tumor detection simulations

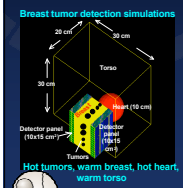


Hot tumors, warm breast, hot heart, warm torso

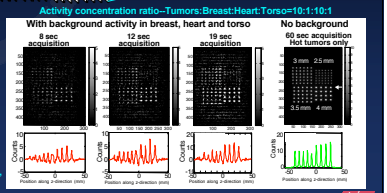


Simulations predict: can see 3 mm tumors in 10 sec.

MIPS
Molecular Imaging Program at Stanford

Stanford University
School of Medicine
Department of Radiology