T2-weighted Imaging for Improved Lesion Characterization in Breast MRI

Catherine J. Moran, PhD

NCI Cancer Imaging Fellowship Seminar
June 20, 2012

1. Motivation and Background

2. Evaluation of 3D T2-weighted Imaging

3. Double Echo Steady State T2-mapping: Initial Results

1. Motivation and Background

Clinical Motivation

- ✧ Most commonly diagnosed cancer
- ✧ Second most deadly cancer
- ✧ MRI: diagnosis and treatment planning

Source: American Cancer Society, 2009.

Clinical Motivation

- ✧ Most commonly diagnosed cancer
- ✧ Second most deadly cancer
- ✧ MRI: diagnosis and treatment planning

- ✧ Improve lesion characterization with MRI

Source: American Cancer Society, 2009.

Breast MRI

- Centerpiece of breast MRI is Dynamic Contrast Enhanced (DCE-MRI)
- T1-weighted contrast
- Intravenous paramagnetic contrast agent that shortens T1
- Uptake of contrast greatly improves conspicuity of lesions

Breast MRI

- Centerpiece of breast MRI is Dynamic Contrast Enhanced (DCE-MRI)
- T1-weighted contrast
- Intravenous paramagnetic contrast agent that shortens T1

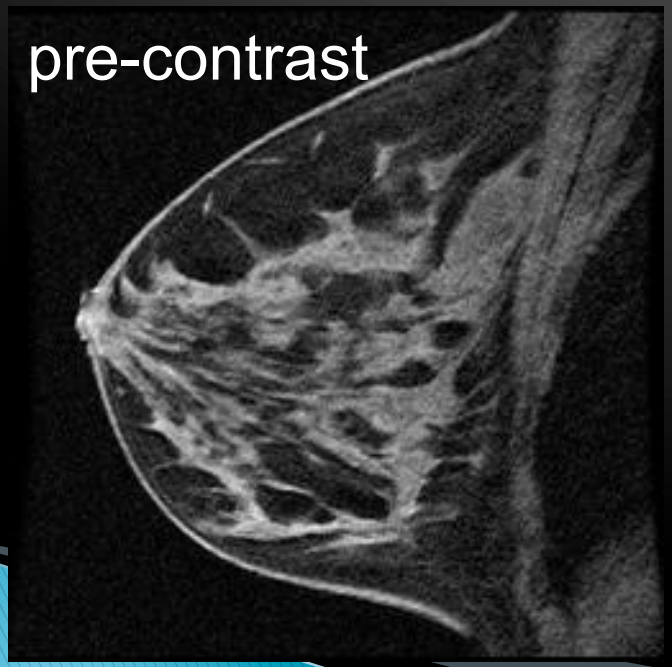

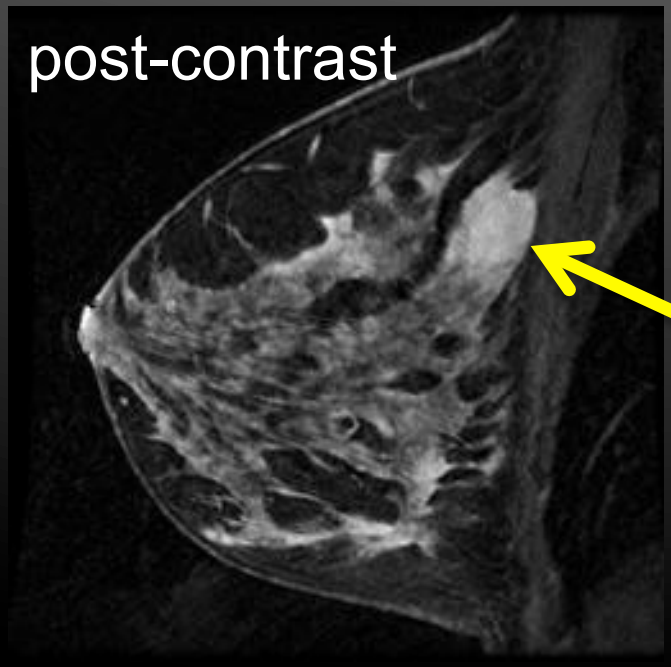

DCE MRI in the Breast

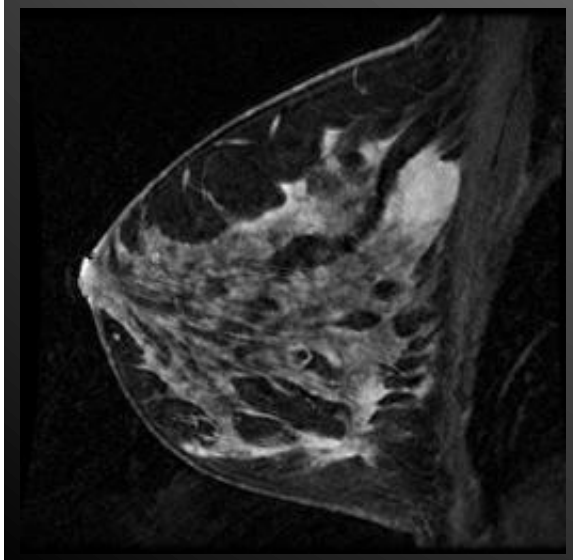

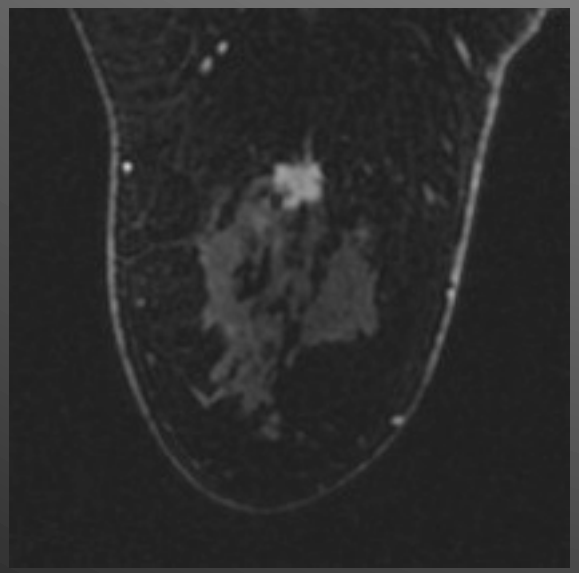

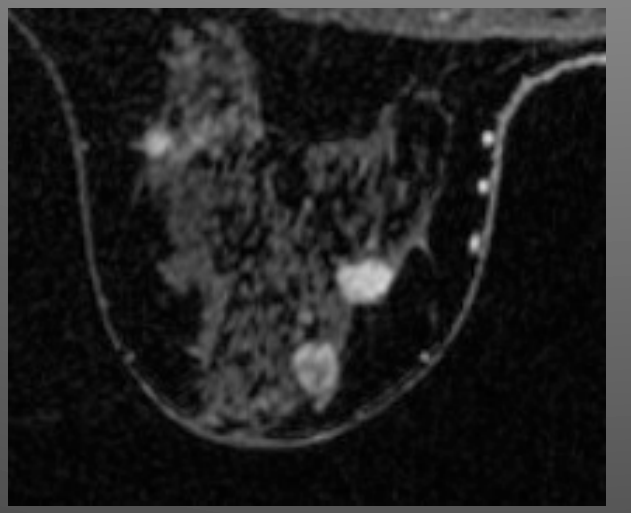

- DCE-MRI has very high sensitivity (89-100%)[1]

Majid, AS, Radiographics, 23, 2003: 881-895

DCE MRI in the Breast

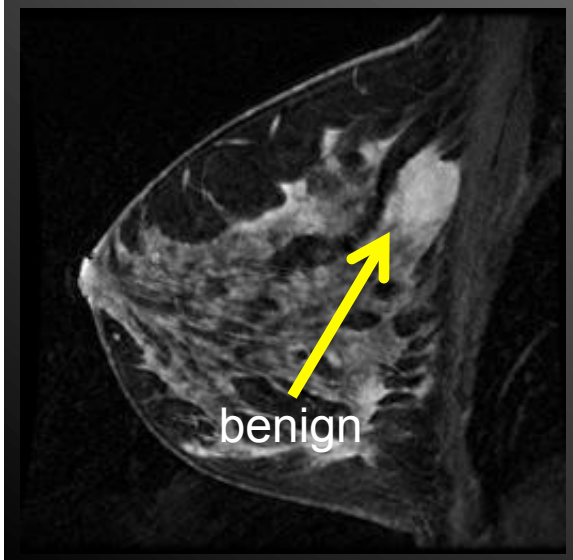

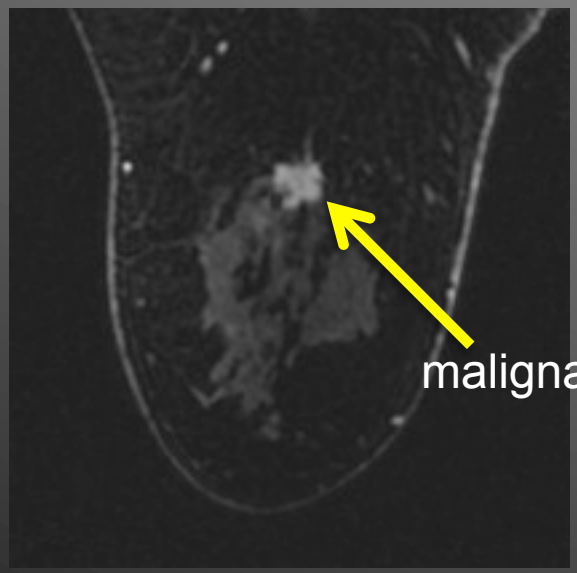

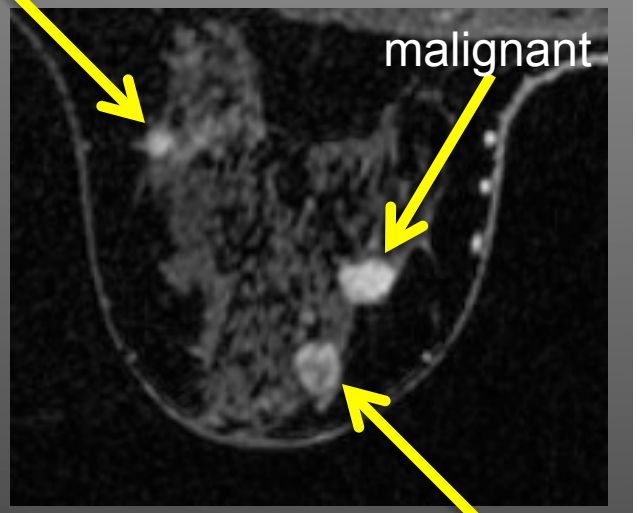

- DCE-MRI has very high sensitivity (89-100%)[1]

Majid, AS, Radiographics, 23, 2003: 881-895

DCE MRI in the Breast

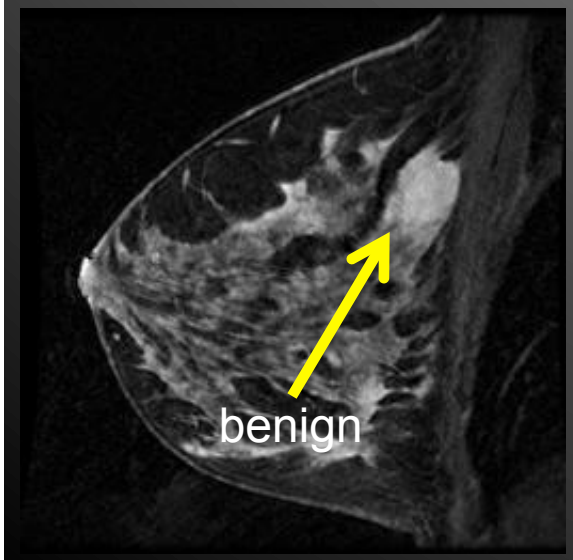

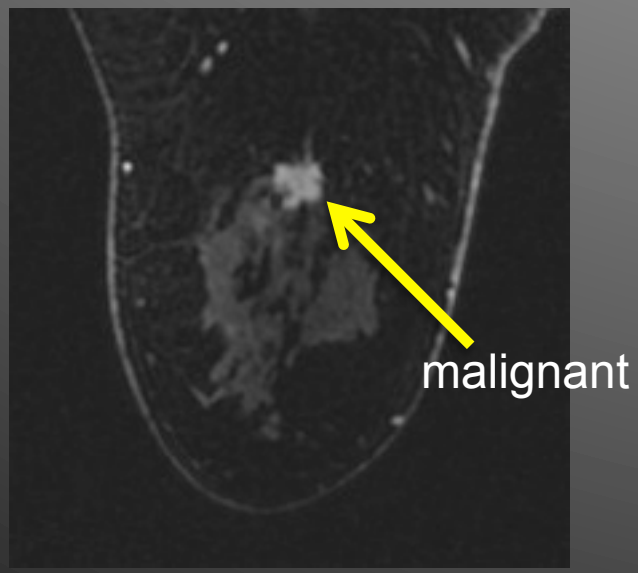

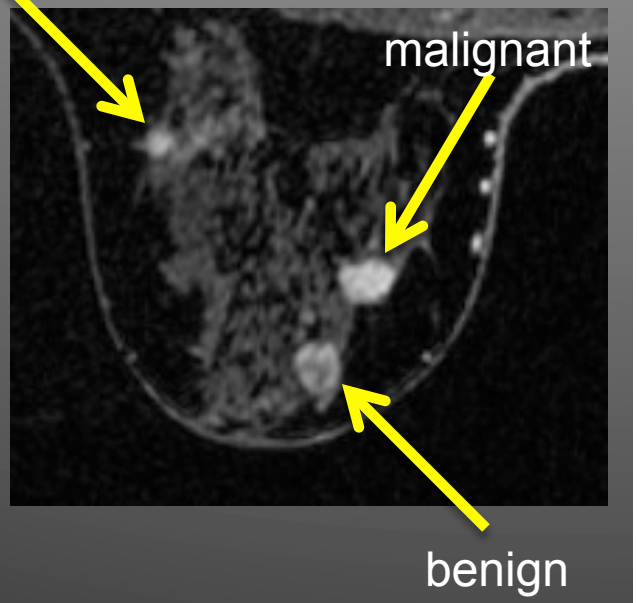

- DCE-MRI has very high sensitivity (89-100%)[1]
- Specificity of breast MRI is variable (30-97%)[2]

[1]Kuhl, et al., *Radiology*, 2007, [2]Harms, et al., Radiology, 1993

Majid, AS, Radiographics, 23, 2003: 881-895

T2-Weighted Imaging in Breast MRI

- Adjunct to Dynamic Contrast Enhanced Images
- Routine part of Breast MRI, identification of cysts
- Information that can contribute to lesion characterization

1. Contrast of lesion to surrounding fibroglandular tissues
    - Malignant lesions tend to have low T2 weighted signal
    - Benign lesions tend to have high T2 weighted siganl
2. Lesion morphology

T2-Weighted Imaging in Breast MRI

Pre Contrast Injection

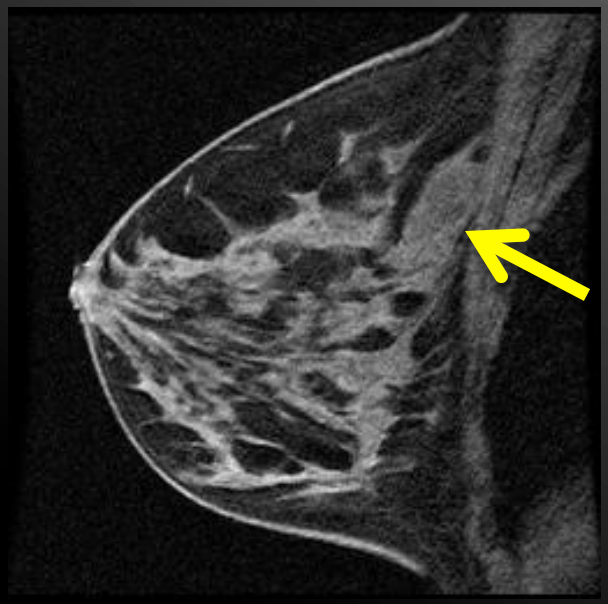

DCE (Contrast Enhanced)

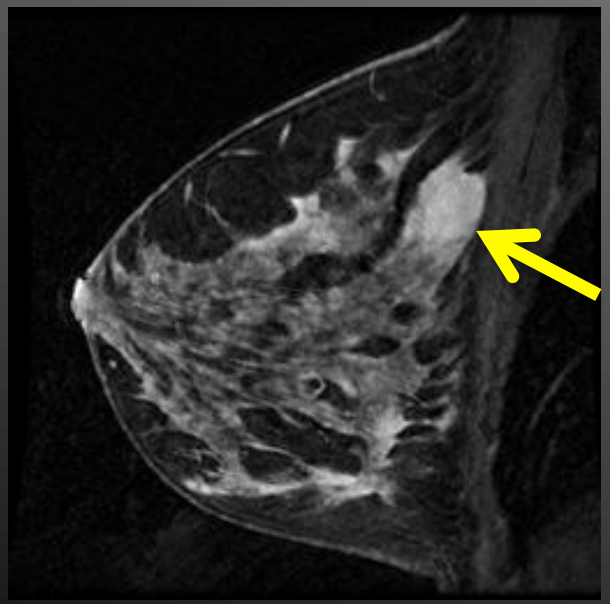

T2 Weighted

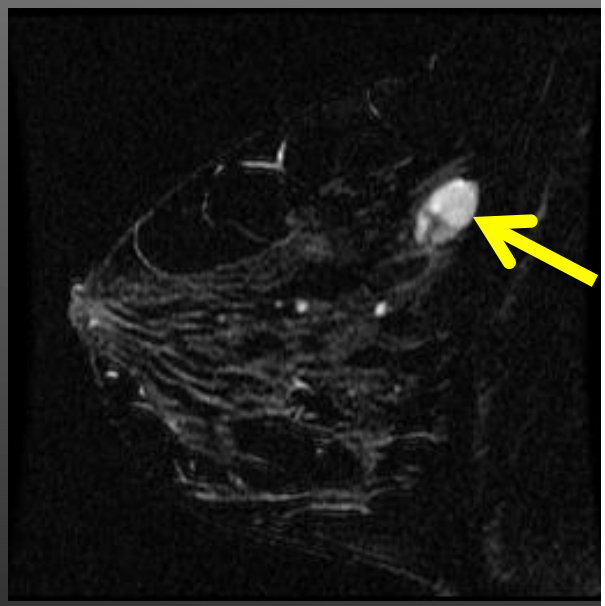

Limitations of T2-weighted Imaging

- Necessity for long TR, short signal duration

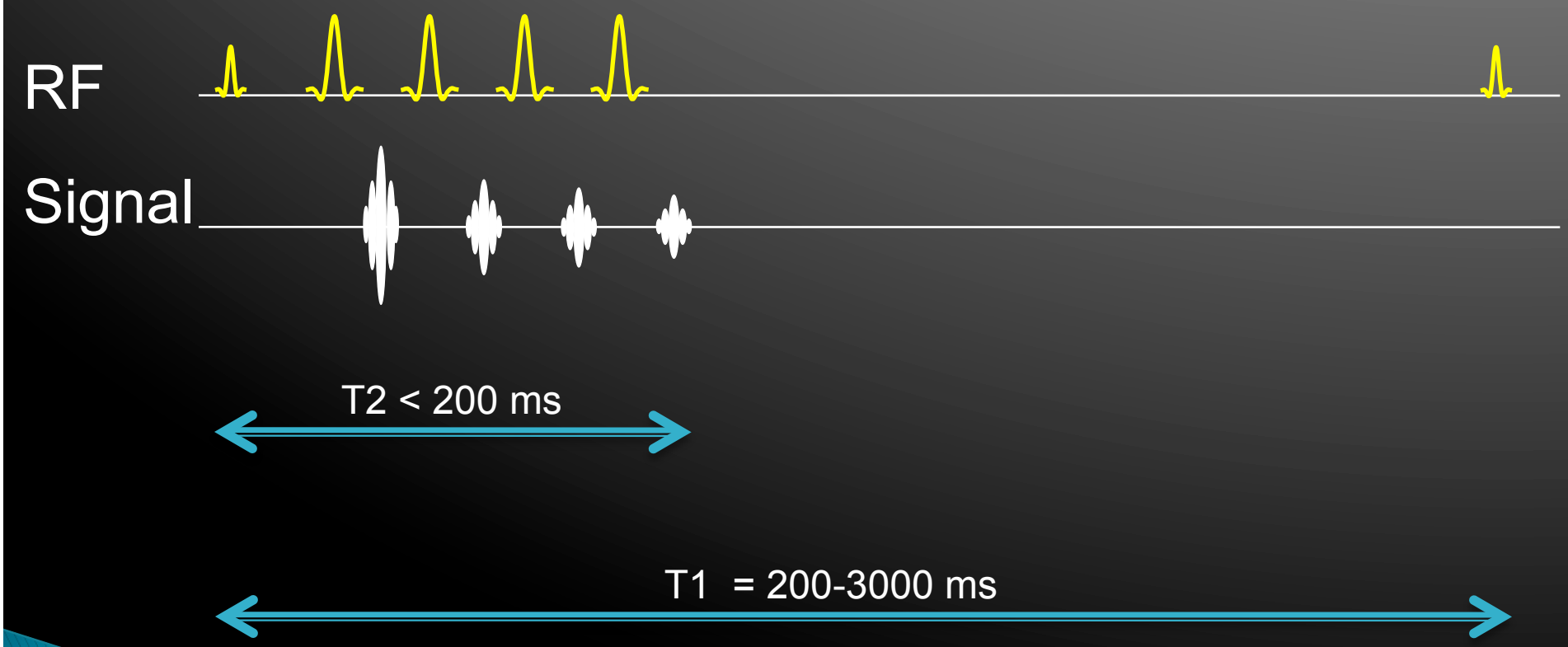

Limitations of T2-weighted Imaging

- Necessity for long TR, short signal duration

- Long scan times for high resolution
- Acquired in 2D with low through-plane resolution

Limitations of T2-weighted Imaging

- Necessity for long TR, short signal duration

- Partial volume effect can obscure lesion morphology
- Poor alignment with DCE images

Summary: T2-weighted Imaging in breast MRI

- ✧ Variable specificity
- ✧ Diagnostic information in T2-weighted imaging
- ✧ Inherent limitations of T2-imaging
- ✧ Undervalued and underutilized

1. Motivation and Background

2. Evaluation of 3D T2-weighted Imaging

3. Double Echo Steady State T2-mapping: Initial Results

2. Evaluation of 3D T2-weighted Imaging

Extended Echo Train T2-weighted Imaging

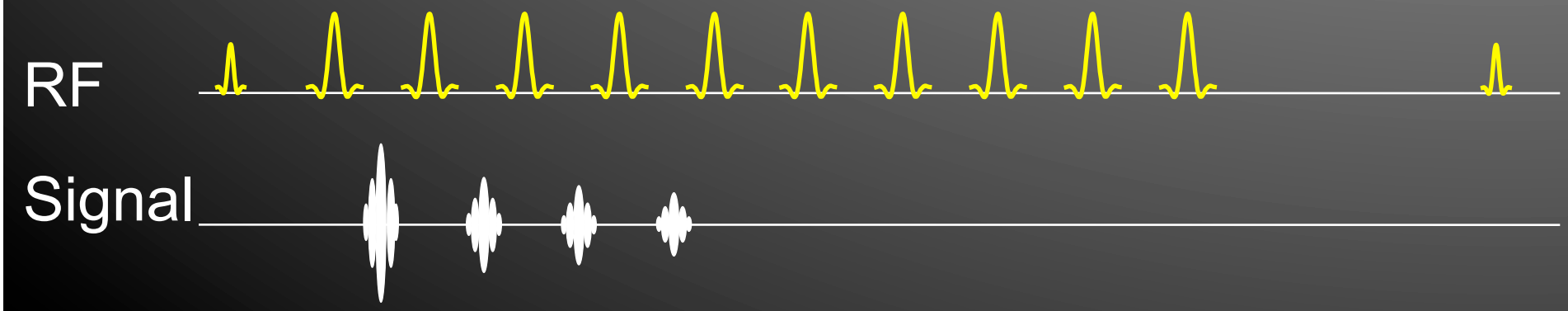

Extended Echo Train T2-weighted Imaging

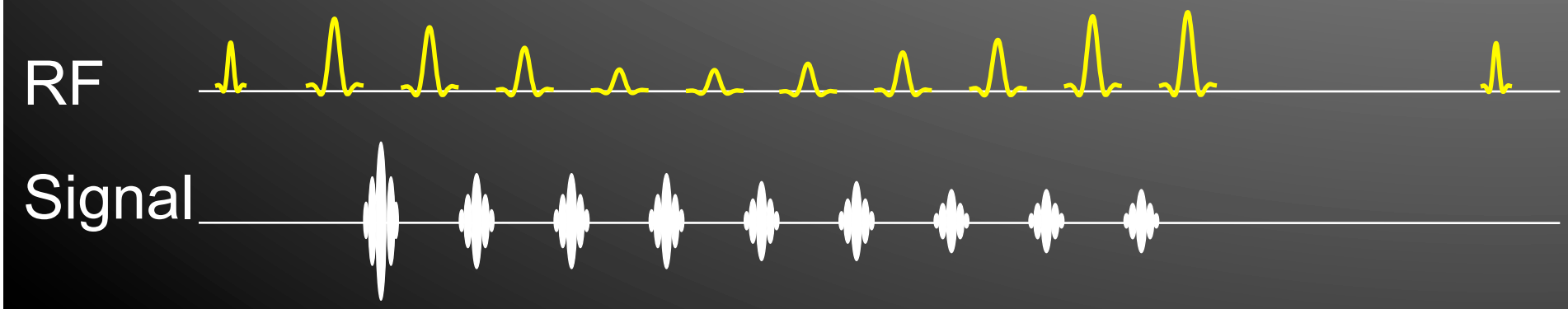

+ 3D T2-weighted imaging

- Not purely T2-weighted

3D T2-weighted Imaging

- clinically available
  - CUBE (GE)
  - SPACE (Siemens)
  - VISTA (Phillips)

- validation in vivo
  - Meniscus (Kijowski, et al., *Skel Rad*, 2011)
  - Ganglion cysts (Shahid, et al., *JMRI*, 2010)
  - Ankle (Stevens, et al., *Radiology*, 2008)
  - Uterine abnormalities (*Agrawal*, et al., AJR, 2009)

*Mugler, JP, *et al*. *Radiology*, 2000, Hennig, J, *et al*., *MRM*, 2003, Busse, RF, *et al*., *MRM*, 2006.

3D Extended Echo Train Breast MRI

Goal of this work to assess the 3D T2-weighted CUBE sequence, in vivo in the breast in comparison to a conventional 2D Fast Spin Echo Sequence

- Contrast between lesions and surrounding tissues
- Impact of improved resolution

3D Extended Echo Train Imaging in the Breast

Subjects

- 27 patients
- CUBE and FSE acquired as part of breast MRI
- Clinically indicated breast MRIs
    - High-risk screening (12)
    - Preoperative staging (5)
    - Response to treatment (5)
    - Diagnostic (5)

3D Extended Echo Train Imaging in the Breast

Subjects

- 27 patients
- 17 lesions
  - 7 Invasive Ductal Carcinomas (IDC)
  - 5 fibroadenomas, 1 papilloma, 3 cysts, 1 cyst/hematoma

Imaging Parameters

	FSE	CUBE	DCE
Matrix	320 x 256	320 x 256	236 x 366
Slice Thickness	4 mm	2 mm	1 mm
Number Slices	46	192	364
Scan Time	5 min	5 min	----

3D Extended Echo Train Imaging in the Breast

Analysis

- Lesion-to-fibroglandular tissue signal
- Unblinded review by radiologist
- Effect of resolution

Lesion-to-Fibroglandular Tissue Signal Ratio

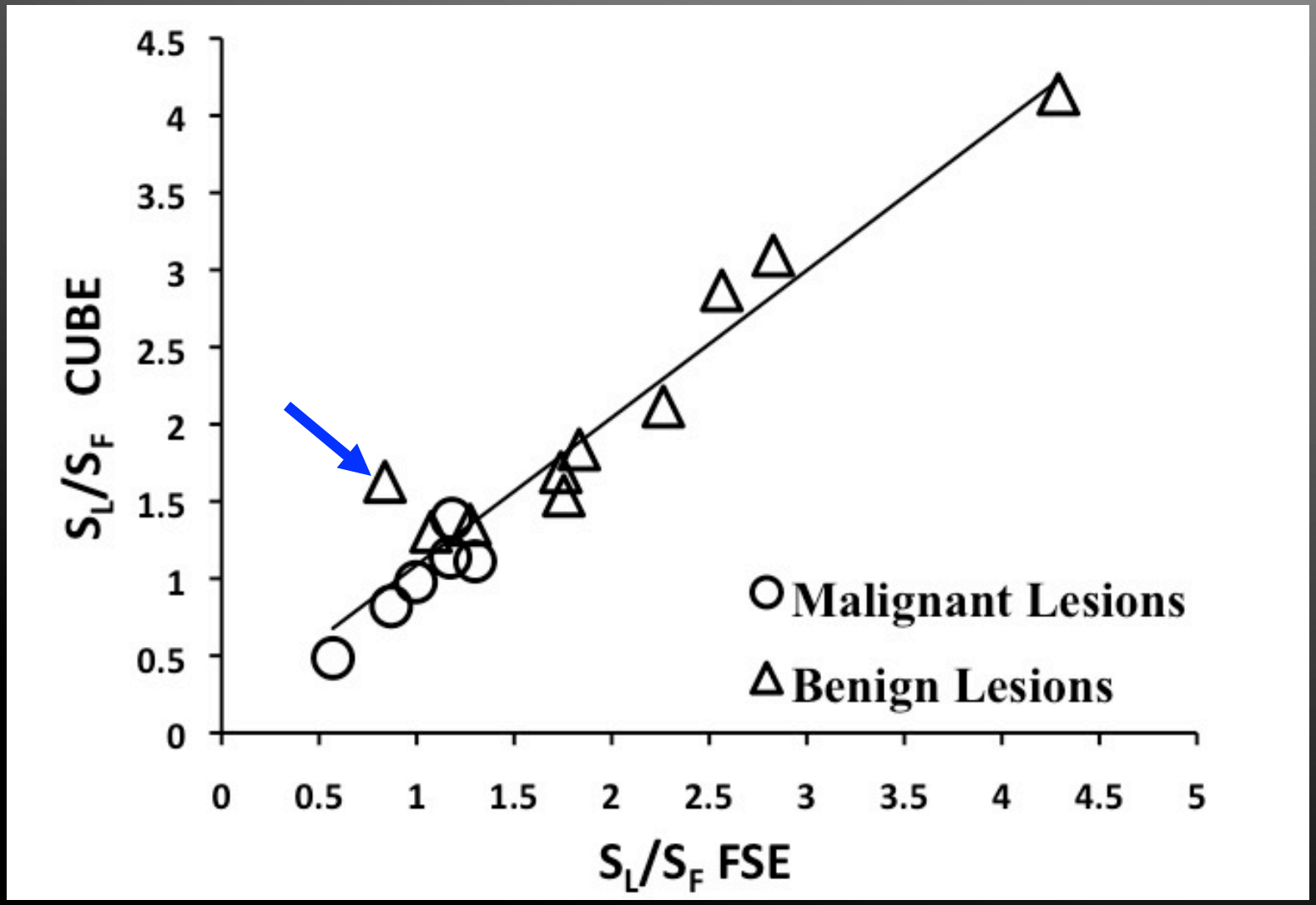

Small Enhancing Fibroadenoma

DCE

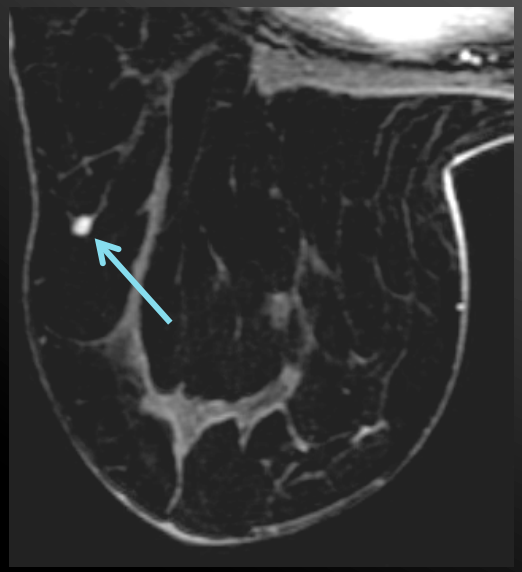

FSE

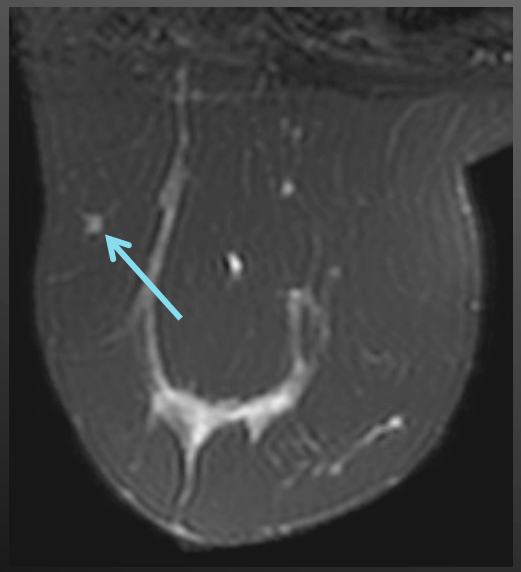

CUBE

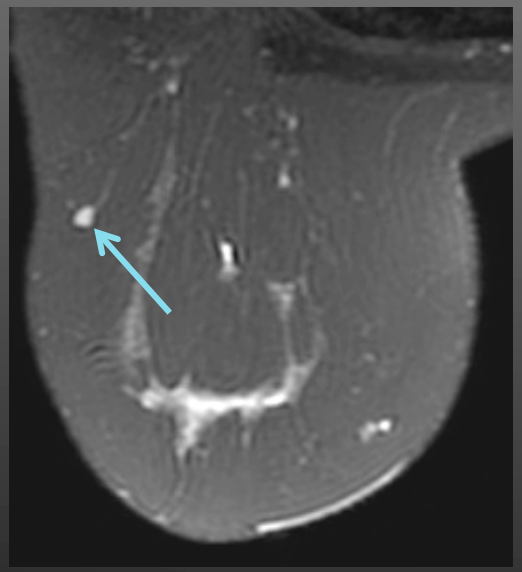

Benign Papilloma

DCE - Axial

FSE - Axial

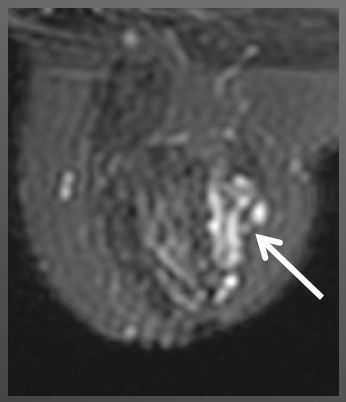

CUBE - Axial

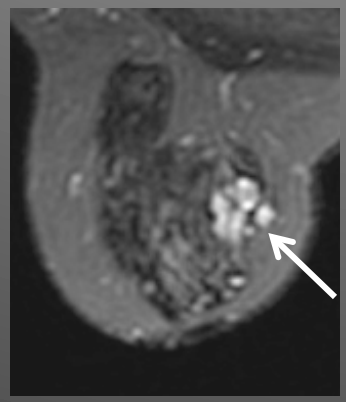

DCE - Sagittal

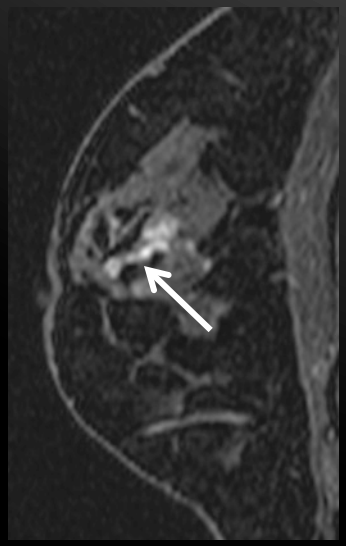

FSE - Sagittal

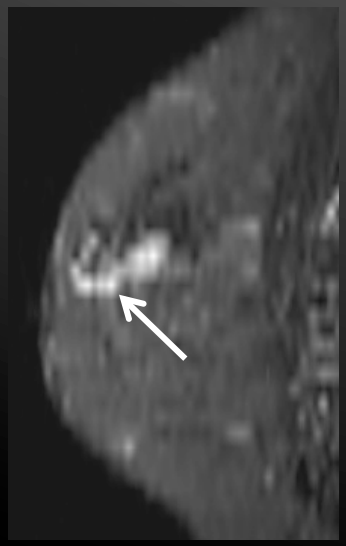

CUBE - Sagittal

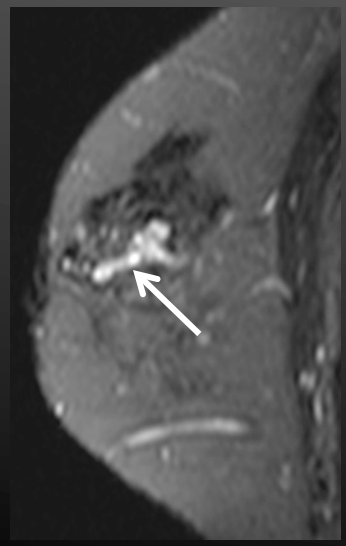

3D Extended Echo Train Imaging in the Breast

Contrast

- Lesion-to-fibroglandular tissue contrast well correlated
- More accurate depiction of contrast in small lesions

Resolution

- Improved alignment with DCE findings
- Improved depiction of lesion morphology

3D Extended Echo Train Imaging in the Breast

Conclusion:

3D T2-weighted acquisitions may improve the contribution of T2-weighted imaging in breast MRI through higher resolution without detriment to T2-weighted contrast

** based on this initial assessment, CUBE is now the T2-weighted sequence utilized clinically at Stanford

1. Motivation and Background

2. Evaluation of 3D T2-weighted Imaging

3. Double Echo Steady State T2-mapping: Initial Results

3. Double Echo Steady State T2-mapping: Initial Results

Quantitative T2-mapping in the breast

- Lesion signal intensity on T2-weighted images is relative
- Large variability in signal intensity across normal tissue

T2-weighted

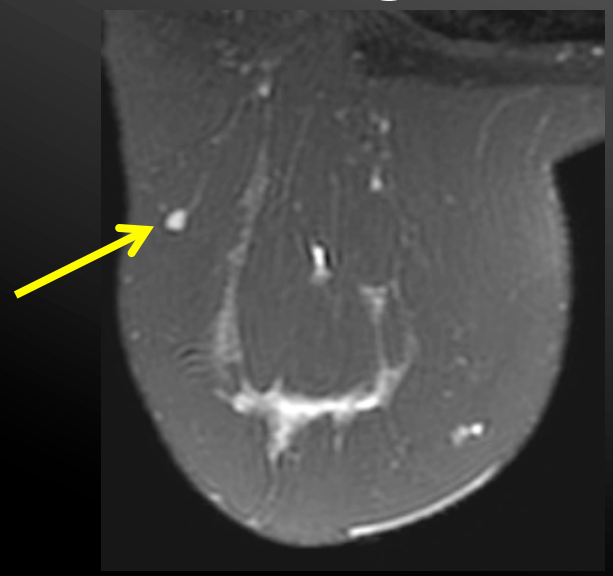

Quantitative T2-mapping in the breast

- Signal intensity on T2-weighted images is relative
- Large variability in signal intensity across normal tissue
- Two previous studies of T2-values in breast lesions
- Early on – low resolution, image quality

T2-mapping

- Time consuming
- Not practical in-vivo

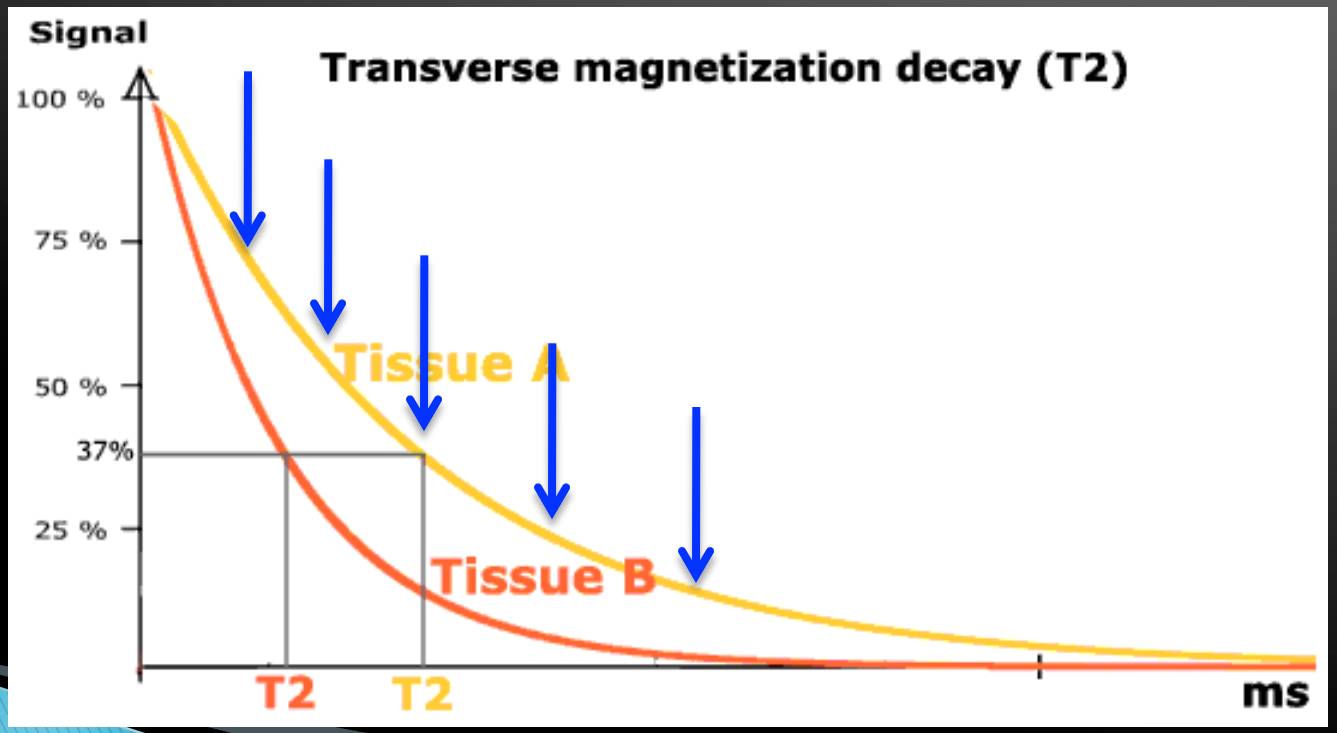

DESS

- Dual Echo Steady State
- Gradient echo so more efficient than spin echo methods

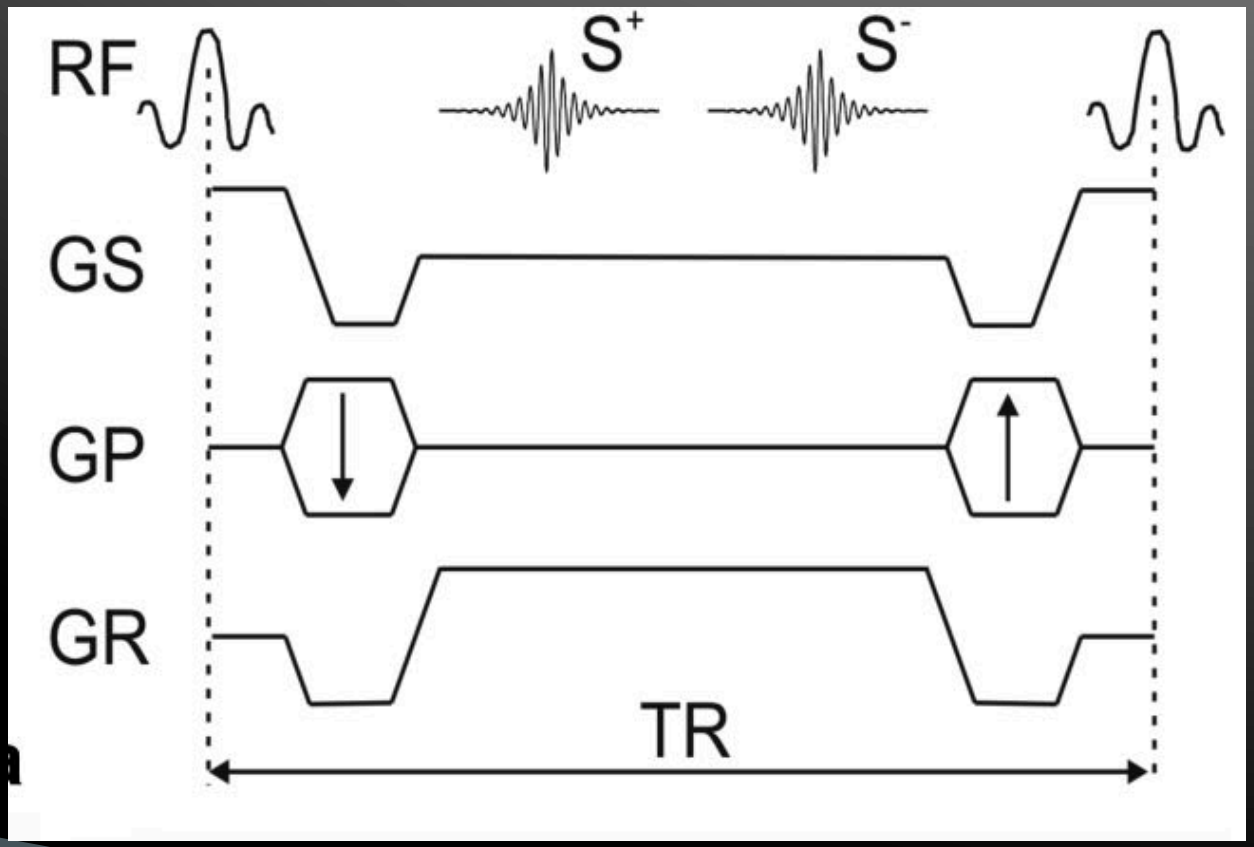

Wlesch, GH. MRM (62). 2009: 544-549.

T2-mapping with DESS

$$T2 = \frac{2 \cdot (TR - TE)}{\ln(S^{+}/S^{-})}$$

- Calculation of T2 is only valid for flip angles of 90°
- However at 90° SNR is very low

Wlesch, GH. MRM (62). 2009: 544-549.

DESS

- Diffusion between the two echoes can limit the accuracy
- qDESS: both ADC and T2

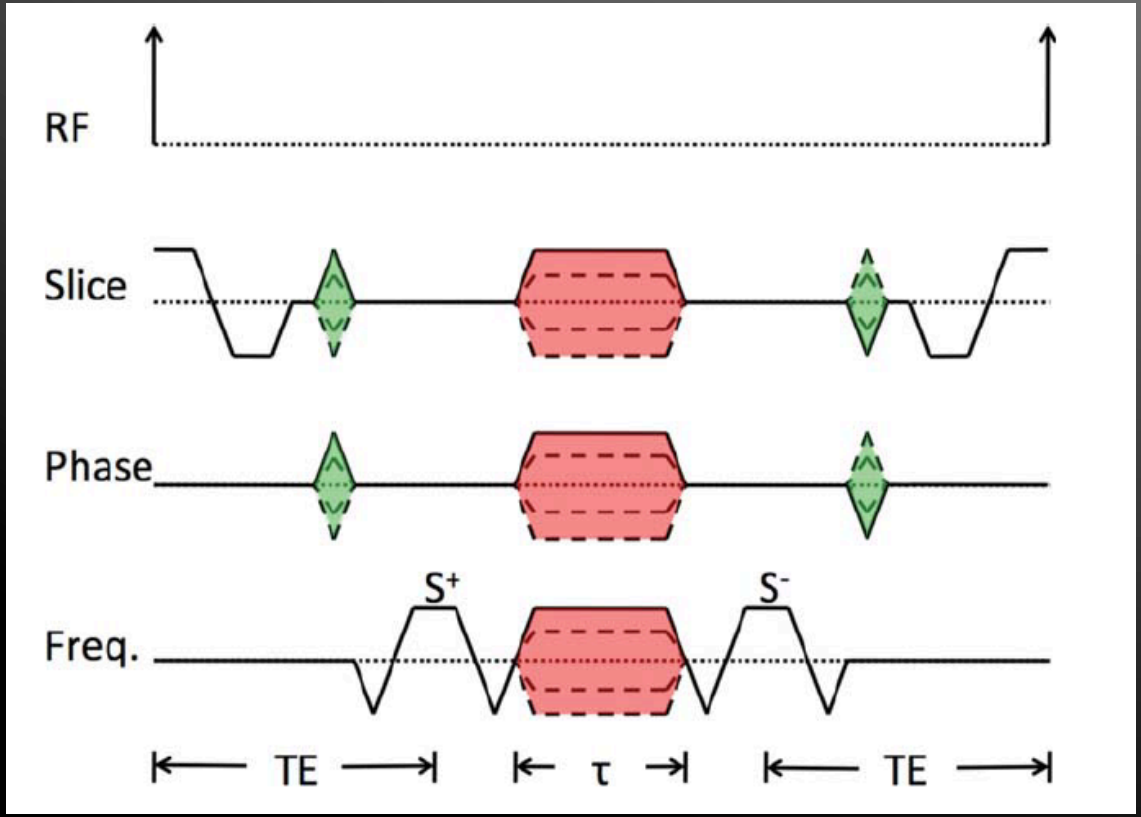

*Staroswiecki, et al., MRM, 2011

DESS

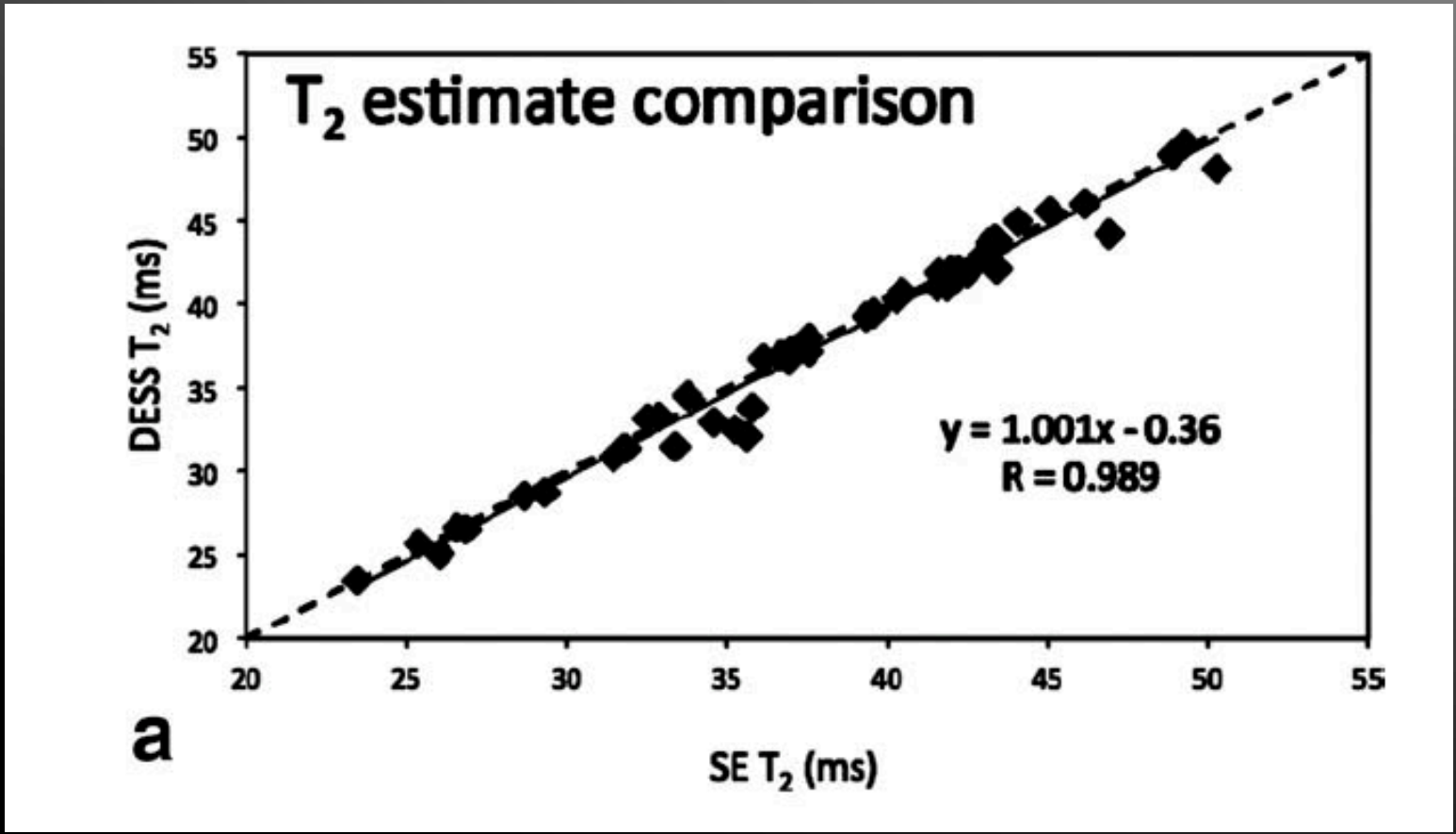

*Staroswiecki, et al., MRM, 2011

DESS in the Breast Current Status

- DESS also provides ADC Maps
- Implementation in the breast*
- Focus on ADC
- Implemented clinically, consenting patients

- T2-maps
- Exploratory
- Preliminary results

*Granlud, K.

DESS

- DESS T2-maps for 11 patients
- Measured T2 value
  - Muscle
  - Fibroglandular tissue
  - Benign lesions
  - Malignant lesions

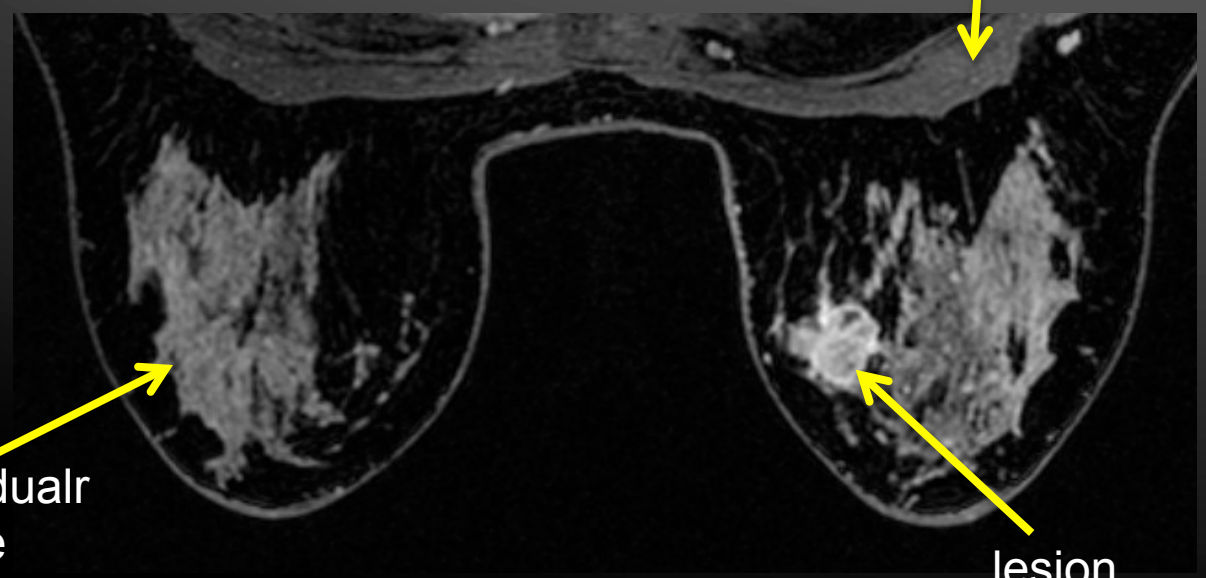

DESS

- DESS T2-maps for 11 patients
- Measured T2 value
  - Muscle
  - Fibroglandular tissue
  - Benign lesions
  - Malignant lesions
- Compared to literature T2 values (muscle and fibroglandular)
- Qualitative assessment of T2-maps

Lesions in 11 subject dataset

- 10 malignant (8 IDC, 1 ILC, 1 DCIS) lesions
- 3 benign (2 UDH, 1 ALH) lesions
- 3 benign (1 cyst, 2 hematomas) lesions

T2-mapping in the breast

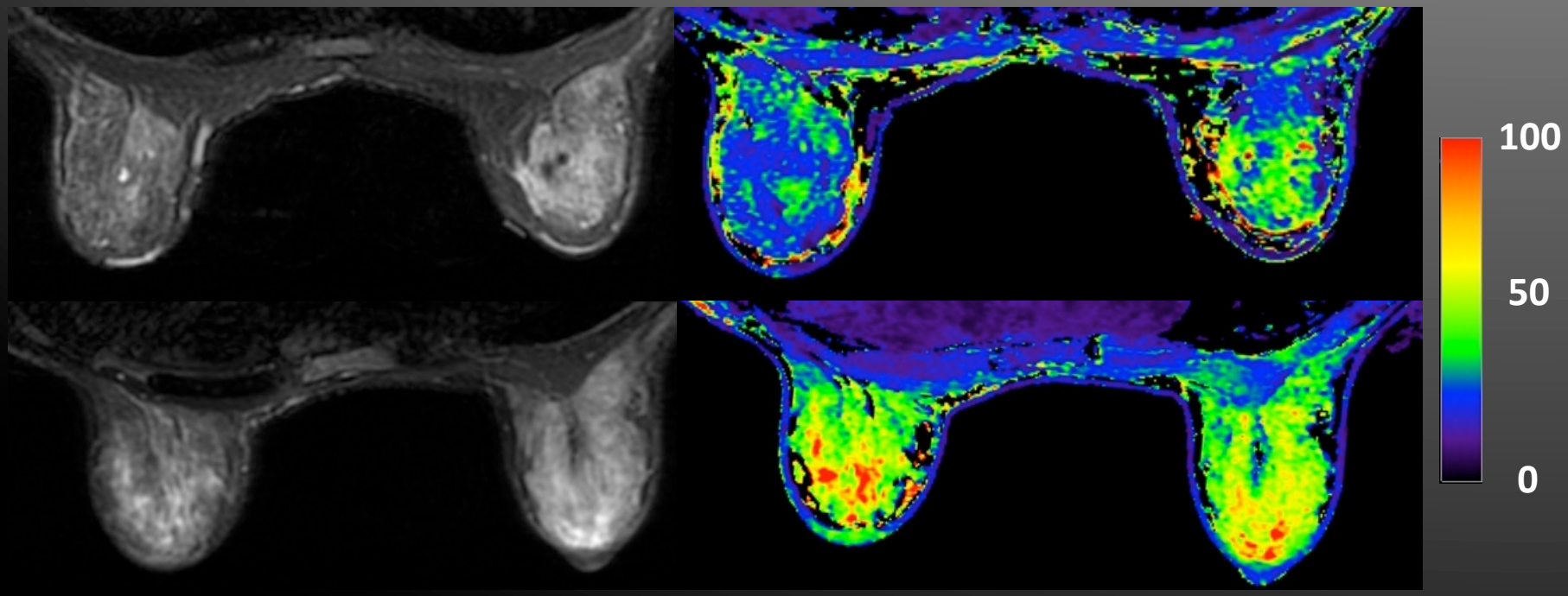

T2 (ms)

	Literature	DESS T2
Muscle	27 ± 2, 29 ± 4	24.4 ± 4
Fibroglandular	54.4 ± 9	44.2 ± 16

T2-mapping in the breast

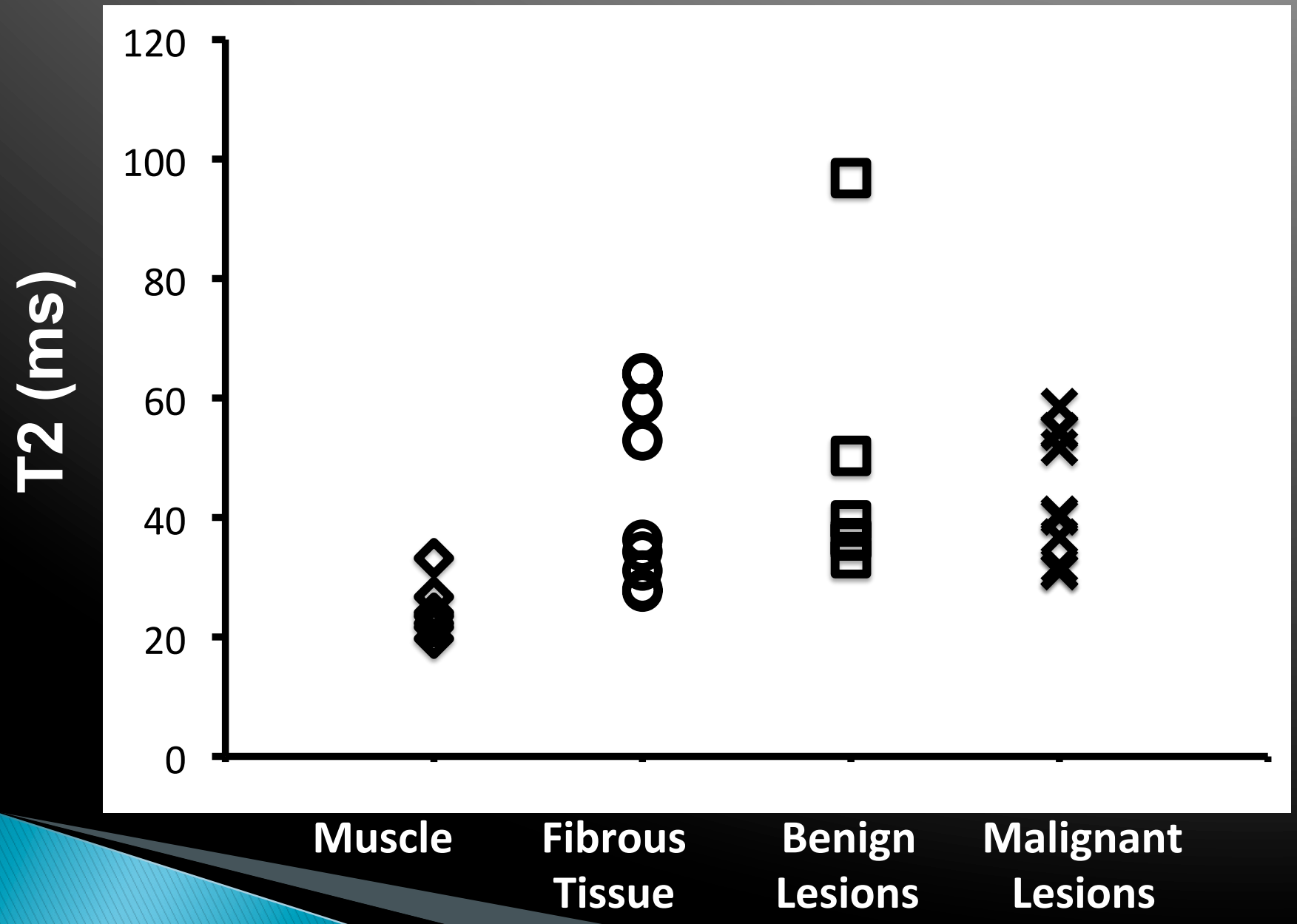

T2-mapping in Malignant Lesions

T2-weighted (FSE)

DESS T2-maps

IDC (1)

IDC (3)

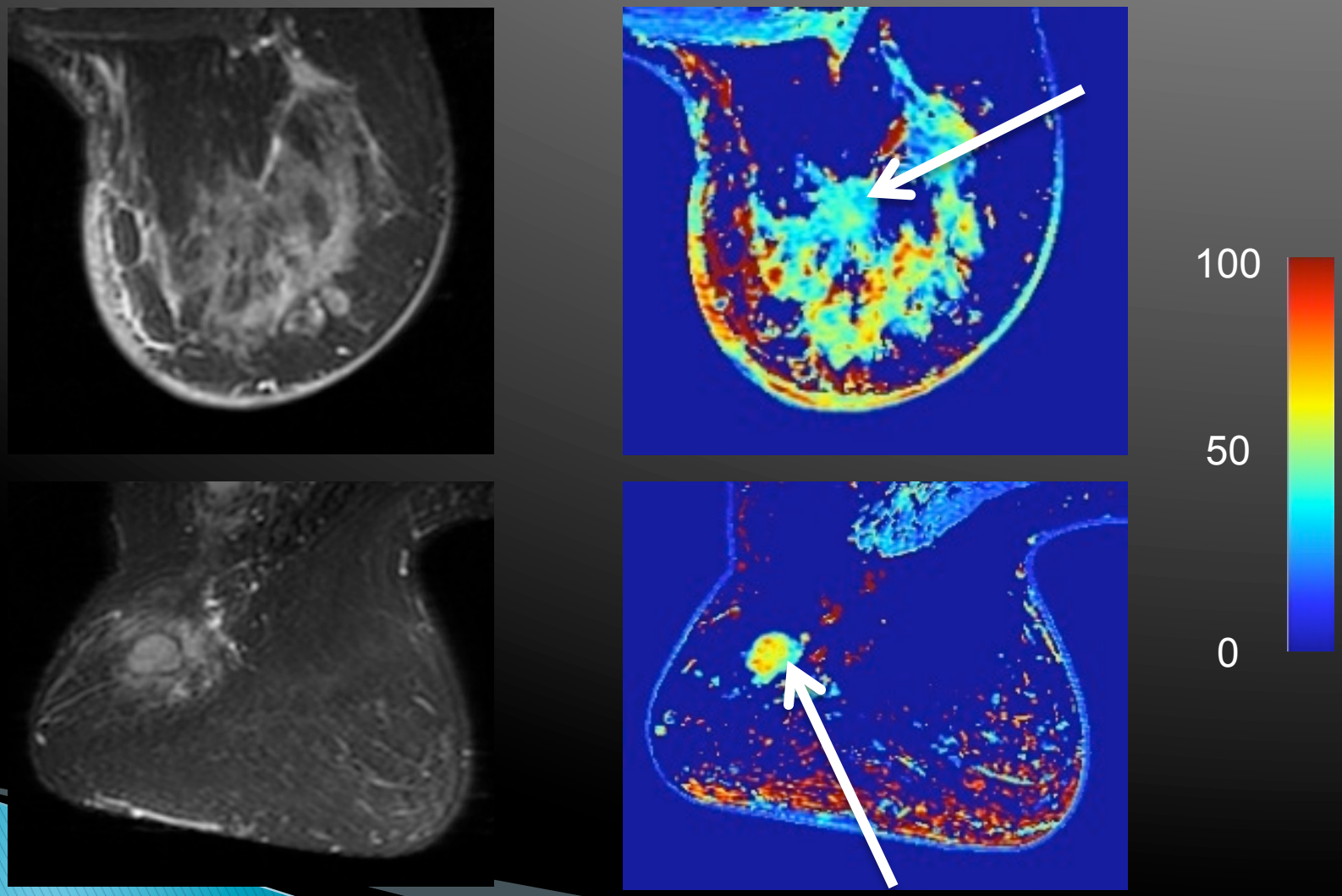

DESS T2-mapping in the Breast

- DESS T2 values correlated with spin echo values
- Investigation of T2-values in-vivo in the breast
- Preliminary results

  - Validation of T2-values in vivo in normal breast tissue
  - Defining hypothesis for T2-mapping in breast MRI

Clinical Motivation

- ✧ Improve lesion characterization with MRI
  - ✧ Evaluation of 3D T2-weighted Imaging
  - ✧ DESS T2-mapping in the breast

Source: American Cancer Society, 2009.

Acknowledgements

Brian Hargreaves

Anne Sawyer

Jafi Lipson

Bruce Daniel

Kevin Epperson

Jennifer Kao

Volunteers

Manoj Saranathan

Anderson Nnewihe

Kristin Granlund

Kyung Sung

Marc Alley

Bragi Sveinsson