Article

AMERICAN ORTHOPAEDIC FOOT & ANKLE SOCIETY

Foot & Ankle International®
1–6

DOI: 10.1177/1071100720959015
journals.sagepub.com/home/fai

Suture Tape Augmented Broström Procedure and Early Accelerated Rehabilitation

Kevin D. Martin, DO, FAAOS[1], Nolan N. Andres, DO[2], and William H. Robinson, DO[2]

Abstract

Background: Immediately following a lateral ligament reconstruction of the ankle, the strength of the repair is far less than that of the native anterior talofibular ligament (ATFL). Additionally, early functional rehabilitation has been shown to increase laxity of the repair. We hypothesized that a Broström procedure augmented with a suture-tape construct would allow early functional rehabilitation while maintaining patient reported outcomes within a military population.

Methods: This study is a retrospective study of 93 consecutive patients with chronic lateral ankle instability that were treated with a Broström procedure augmented with a suture-tape construct. Subjects were evaluated at 2, 6, and 12 weeks postoperatively, with yearly satisfaction reviews. Demographics and functional outcomes including Foot and Ankle Disability Index (FADI), visual analog scale (VAS), satisfaction score, and clinical measures including single-leg hop and single-leg heel raise were recorded. Our patients included 75 males and 18 females with a mean age of 30 ± 7 (range, 19-51) years; our mean follow-up was 19 (range, 3-48) months.

Results: The mean FADI score improved from 67 preoperatively to 87 and 90 at 6 and 12 weeks ($P < .001$), with 60 patients (65%) obtaining a score greater than 90. The mean VAS scores improved from 4.8 preoperatively to 1.4 and 1.3 at 6 and 12 weeks ($P < .001$). Eighty-two (96%) of the patients asked were able to complete a single-leg hop and single-leg heel raise at 6 weeks. The 12-, 24-, 36-, and 48-month satisfaction scores were 8.5, 9.8, 9.2, and 8.9, respectively. Demographics collected did not impact results.

Conclusion: This study suggests that a Broström procedure augmented with suture tape enabled early safe functional rehabilitation without subsequent failure. Our data also demonstrated a sustained high level of patient satisfaction while preventing reoccurrence within a high-demand military population.

Level of Evidence: Level IV, retrospective case series.

Keywords: lateral ankle instability, lateral ankle sprain, anterior talofibular ligament

More than 30 000 ankle sprains per day are reported in the United States, making up nearly 30% of all sports injuries.[2,7] Lower-extremity injuries cost the United States Army millions of dollars, reduced training efficiency, and detracted force strength.[10] The majority of these injuries involve the anterior talofibular ligament (ATFL) and go on to heal with nonoperative treatment.[9] The remaining 32% of sprains treated functionally go on to develop chronic pain, swelling, and recurrent instability.[11] The residual altered joint mechanics and cartilage contact stresses contribute to the development of posttraumatic osteoarthritis and long-term dysfunction.[23,24] Operative reconstruction is typically recommended after a period of functional rehabilitation has failed. It has shifted from nonanatomic tenodesis procedures to the more anatomic Broström reconstruction with modifications.[6]

The modified Broström procedure uses a direct ligament repair to the distal fibula with a variety of fixation techniques. Regardless of the fixation technique, the strength of the repair is limited by the extent of damage to the native tissue and the time required for ligament healing. A nonaugmented suture anchor Broström reconstruction has less than 50% of the native ligamentous strength immediately following the repair.[25] If early unprotected range of motion is initiated too

[1]Evans Army Community Hospital, Ft Carson, CO, USA
[2]Rocky Vista University College of Osteopathic Medicine, Parker, CO, USA

Corresponding Author:
Nolan N. Andres, DO, Rocky Vista University College of Osteopathic Medicine, 8401 S Chambers Rd, Parker, CO 80134, USA.
Email: nolan.andresdo@gmail.com

soon, the repair may develop associated lengthening consistent with failure.[12] These consequences must be weighed against the benefits of improved biologic collagen healing, tissue orientation, and cartilage preservation experienced with weightbearing range of motion.

In order to maximize the biological benefits of early range-of-motion exercises and weightbearing while protecting the repair, a suture-tape augmented Broström procedure has been suggested. Early biomechanical testing has shown that a suture-tape augmented Broström reconstruction has double the strength of the native ATFL.[25] Within our population of active duty service members, the incidence of ankle sprains are 5 times greater than that reported in a civilian population, and the cost of time away from duty and reinjury is substantial.[3,26] Thus, we hypothesized that a suture-tape augmented Broström procedure would allow early weightbearing range of motion while preserving the repair and preventing early failure in an active duty military population.

Methods

A retrospective medical record review was performed on a single orthopedic foot and ankle surgeon practicing within an active duty medical treatment facility. The chart review was limited to those patients who had undergone lateral ankle instability repair with a Broström reconstruction augmented with suture tape (InternalBrace; Arthrex, Naples, FL). Inclusion criteria consisted of age between 18 and 65 years, preoperative magnetic resonance imaging (MRI) demonstrating injury to ATFL, physical examination by the senior author detailing a positive anterior drawer, failure of a trial of nonoperative treatment, and postoperative completion of physical examination and functional evaluation at 6 and 12 weeks. Patients who underwent revision Broström procedures and any of the following were also included: peroneal debridement, superficial deltoid repair, and extensive arthroscopic debridement. Exclusion criteria were as follows: secondary procedures done at the time of repair including microfracture, cartilage allograft, posterior arthroscopic debridement, peroneal tendon repair, syndesmosis repair, and calcaneus osteotomies.

For each patient, the electronic medical record was reviewed for age, sex, height, weight, nicotine use, and body mass index (Table 1). Further operative details were evaluated within the scope of the inclusion and exclusion criteria including complications. Pre- and postoperative patient-reported outcome measures were gathered including the visual analog scale (VAS) and Foot and Ankle Disability Index (FADI). A modified single-leg hop test was performed at 6 weeks, which included subjects standing on 1 leg (operative) with the toe behind a marked line and jumping over the line without assistance. In our active duty military population, we did not feel a maximum jump distance would be safe because of the inherent competitive nature and a given order by a senior officer. Similarly, an unassisted single-leg heel raise test (ipsilateral knee fully extended) was completed and passed if 5 lifts could be completed. The functional evaluations along with the physical examination findings, including the anterior drawer, were performed by the senior author. The FADI was selected as the primary patient-reported outcome measure as it has been validated for ankle instability severity, and our clinic staff has access to a simplified score calculator.[8,14] A yearly follow-up satisfaction (stability) telephone call was made by a member of the research team not involved in patient care, using a 0-10 scale with 0 indicating not satisfied at all and 10 indicating completely satisfied.[5,19]

A total of 136 ankles were initially identified. Of those, 93 met inclusion criteria with 75 males and 18 females. The average age was 30 ± 7 years with a mean body mass index of 27 ± 4. Thirty (32%) of the patients used nicotine regularly. Two patients had staged bilateral procedures, and 6 patients underwent a simultaneous reconstruction of the anterior band of the superficial deltoid with a mini-open approach and suture anchor fixation.

Operative Procedure

All operative procedures were performed within a single military treatment facility by 1 surgeon. All patients underwent a diagnostic arthroscopy and debridement as needed. All patients received a similar oblique longitudinal incision from the posterior distal fibula toward the fourth metatarsal, and those with peroneal pathology had a slightly longer proximal limb. Patients that had evidence of peroneal pathology on the preoperative MRI and a positive clinical examination underwent a limited examination and debridement with the retinaculum only partially taken down, and those that required a formal repair were excluded.

Next, a 1-cm periosteal cuff of tissue was elevated from the tip of the fibula to 2 cm proximal, and the residual ATFL and calcaneofibular ligament (CFL) were sharply released. The distal fibula was then prepared with a rongeur and rasp to establish a bleeding bone for the repair site. The proximal band of the ATFL was sharply followed to the insertion on the lateral wall of the talus. Electrocautery was used to mark the site just off the articular cartilage margin, and the site was drilled and tapped. A 4.5-mm knotless anchor (SwiveLock; Arthrex) was inserted and a free needle was used to pass the suture-tape superficially to the ATFL. Two 2.4-mm suture anchors (SutureTak; Arthrex) were then inserted, one at 5 mm from the tip for the CFL, and one at 18 mm for the AFTL (Figure 1). The ATFL and CFL were then reapproximated to the fibula, followed by the suture tape being laid superficially to the ATFL and inserted 10 mm from the tip with a 3.5-mm knotless anchor. The periosteum flap was then imbricated to the inferior extensor

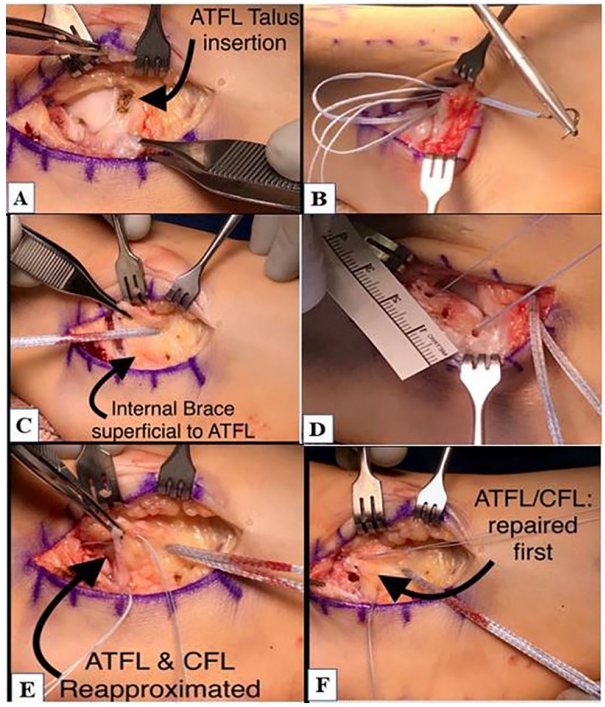

Figure 1. (A) Right lateral ankle incision marking the ATFL insertion on the lateral talar wall (left-proximal, right-distal). (B, C) Suture tape being passed through the ATFL allowing it to rest superficial to the ligament. (D) Demonstrating the anatomic insertion of the CFL (5 mm), ATFL inferior band (10 mm) and the ATFL superior band (18 mm). (E, F) Suture anchors are used to repair the ATFL and CFL to the fibula prior to inserting the suture tape. ATFL, anterior talofibular ligament; CFL, calcaneofibular ligament.

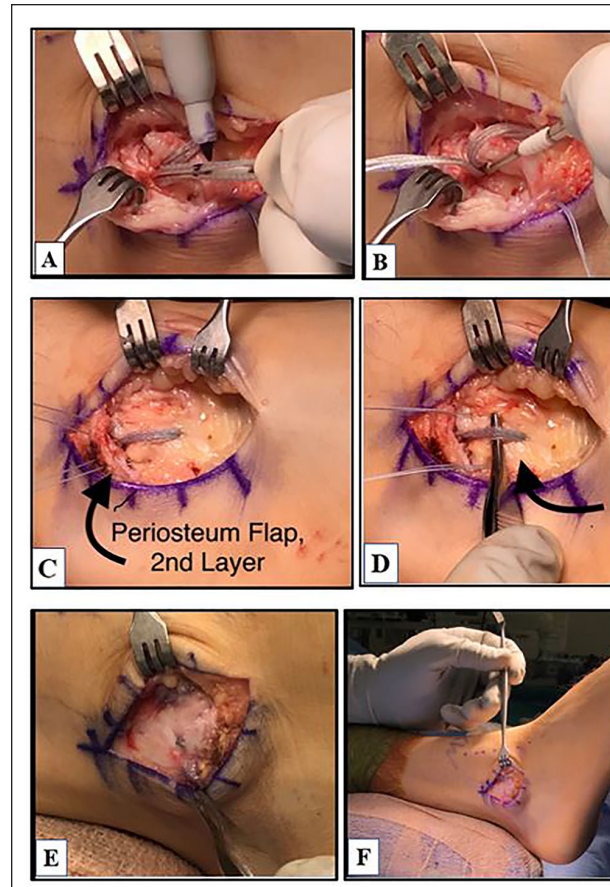

Figure 2. (A, B) Clinical image measuring the suture tape and insertion into the fibula with minimal malleting to prevent overtightening (right ankle, left: proximal, right: distal). (C, D) Demonstrating the suture tape in place without overtensioning the construct. (E, F) The periosteum flap is pulled over the repair and sutured to the inferior extensor retinaculum with absorbable suture, covering the suture tape.

retinaculum with absorbable suture covering the suture tape. The skin was closed with nonabsorbable suture, a local anesthetic was injected, and a posterior slab and U splint was then applied (Figure 2). Deep vein thrombosis prevention was maintained with 81 mg of aspirin twice daily for 10 days in all patients as our treatment facility is 1 mile above sea level.[22]

Postoperative Rehabilitation

The splint was maintained for 10-14 days with partial weightbearing, then patients were placed in a compression sock (10-15 mm Hg) and a postoperative boot. Weightbearing as tolerated (WBAT) was initiated in a postoperative boot and formal physical therapy started along with home resistance band strengthening. The boot was discontinued at 3-4 weeks or as soon as a nonantalgic gait could be maintained, followed by a simple ankle lace-up brace. Stationary recumbent biking and water therapy were strongly recommended and could be used as a pause in rehabilitation if pain and swelling persisted. At weeks 4-6, elliptical trainer and treadmill walking were initiated. Single-leg proprioception and heel raises were paramount, in combination with closed-chain lunges and squats. At week 6, a walk-to-run program and basic agility activities (jumping) were initiated if the patient could maintain a nonantalgic gait while performing a 20-minute treadmill-walk evaluation by physical therapy. Impact and agility activities were initially restricted and gradually introduced under the care of a therapist, and nearly all patients completed therapy within our treatment facility, with the same 2 therapists allowing for close observation and consistency. Return to full unrestricted military duty was restricted for 100 days in all patients because immediately on returning to duty, a soldier must be able to perform all activities including parachuting and marching while carrying 16 kg.

Table 1. Demographic Distribution of Patients Who Underwent Augmented Broström Procedure.

Characteristic	No. (%) of Patients or Mean ± SD (Range) (n = 93)
Males	75 (81)
Females	18 (19)
Tobacco users	30 (32)
Non–tobacco users	61 (66)
Tobacco use unknown	2 (2%)
Age	30 ± 7 (19-51)
Height (cm)	176 ± 9 (152-193)
Weight (kg)	85 ± 16 (50-148)
BMI	27 ± 4 (20-42)

Abbreviation: BMI, body mass index.

Table 2. Visual Analog Score and Foot and Ankle Disability Index Scores of Patients Who Underwent Augmented Broström Procedure.

Score	Time	Mean ± SD	Range
VAS	Preoperative	4.8 ± 1.5	0-8
	6 wk	1.4 ± 1.5	0-5
	12 wk	1.3 ± 1.5	0-5
FADI	Preoperative	67 ± 12	0-93
	6 wk	87 ± 9	54-100
	12 wk	90 ± 11	36-100

Abbreviations: FADI, Foot and Ankle Disability Index; VAS, visual analog score.

Statistical Analysis

For each patient, demographic and functional outcomes were included in the statistical analysis. In order to evaluate the single-leg hop and heel raise, pass/fail was converted into a binary variable. For normally distributed data, we used a 2-sample *t* test comparing outcome measures. Statistical significance was defined as $P < .05$. Outcomes of the patient questionnaires were analyzed using descriptive analysis.

Results

Patients had improvement in pain and function of their ankles, mean VAS and FADI significantly improved ($P < .001$) from before surgery to postoperative follow up (Table 2). VAS reporting inconsistencies have been reported in our patient population, so for consistency the score reported to the nursing staff rather than the surgeon was used throughout the review.[17,18] The single-leg hop test and single-leg heel raise was completed by 82 (96%) of all patients asked, and testing was conducted in similar order and fashion as described in previous literature.[5] The anterior drawer examination was reevaluated at all follow-up appointments by the senior author, which remained stable with a firm end point on all patients. The mean patient satisfaction scores were 8.5 at 12 months, 9.8 at 24 months, 9.2 at 36 months, and 8.9 at 48 months. No return trips to the operating room or revisions were observed, except for 1 patient who had moved away at 36 months revealed he had fallen into a hole and was pending a revision surgery for instability. Two patients described hyperesthesia over the superficial peroneal nerve, and 1 had cellulitis that resolved with a course of oral antibiotics. Four patients described a high dissatisfaction score secondary to localized pain but did not report back for further evaluation of their cases.

Discussion

Early functional rehabilitation following a Broström procedure has yet to be clearly defined for select patient populations within the literature. In the current study we were able to demonstrate early functional rehabilitation following a Broström reconstruction augmented with suture-tape in a military population was safe with high patient satisfaction. With the addition of suture tape acting as a check-ring to the native ATFL repair, we were able to avoid early elongation and laxity associated with instability.[20] The suture tape augmentation also provided consistent durability in the face of military duty, which has a 5 times greater risk of sprains and chronic ankle instability than the general population,[3] with only 1 reported failure over a 3-year period.

Following ATFL reconstruction, the surgeon must weigh the risks and benefits of early range-of-motion exercises and weightbearing. Immobilization reduces collagen transformation and alters cellular orientation, thereby reducing the elastic modulus and overall strength.[1] The construct itself apart from the biology of healing has to be able to withstand early mobilization. It has been demonstrated that nonaugmented suture anchor Broström reconstructions provide less than 50% of the native ATFL strength,[25] thus concluding that extended protection is needed. The reduced strength of a traditional Broström procedure has also been verified in multiple cadaveric models demonstrating inferior torque and angle of failure[21] while elongating with unprotected motion.[12] With the given body of literature, surgeons have utilized multiple nonanatomic reconstructions attempting to bolster the collagen and strength of the repair, but in doing so have led to overconstraint and poor results.[6,13,16]

Our current study was performed with the intent to critically evaluate suture-tape augmented Broström reconstructions with early functional rehabilitation within a military population. Our sample size (no. of ankles: present study, 93; previous study, 81)[5] and mean age (30:34) were similar, though our male-to-female ratio was inversed, with only 18 (19%) females in our study. At only

12 weeks postoperatively, 65 (70%) of our patients scored higher than 90 on the FADI, which is similar to their results with 79% of their patients above 90% on the FAAM. Our FADI score is also in keeping with previous findings[4] that obtained 89 on the FAAM while excluding laborers in a much lower demand population of all females. Although pain is not a hallmark of instability, our patients reported marked improvement in mean VAS from 4.8 preoperatively to 1.3 postoperatively, approaching that obtained by another study (0.8).[5] Durability of the repair is also worth noting, in our population of infantry service members completing 2-3 functional fitness tests annually and frequently carrying combat loads of 16-34 kg. Our satisfaction remained high at 9.8 at 24 months (n = 11), 9.2 at 36 months (n = 31), and 8.9 at 48 months (n = 9), with 1 failure requiring revision. Again, our findings are similar to another study which reported 9.1 with 1 failure 12 months postoperatively.[5]

With the 5:1 greater risk of ankle sprain and a young population, recent work showing a non-augmented Broström procedure can lead to up to 26% of patients giving up sport and 16% describing decreased activity,[15] improved techniques are needed. In our study 82 (96%) of patients asked could complete a single-leg hop and single-leg heel raise test only 6 weeks postoperatively, which without the suture-tape augmentation would have relied on early irregular ligament healing of the ATFL. Although we did not test maximum effort in order to calculate the limb symmetry index due to safety concerns, we remain strongly encouraged by these results. In fact, we have used them to reassure patients and therapists to rapidly advance physical demands. The early functional rehabilitation program has allowed our service members to initiate the walk-to-run program and agility drills approximately 4 weeks sooner than normal Broström reconstruction rehabilitation protocols.

Our study has limitations, the most noteworthy of which is that our population of military infantry service members may not be reproducible and makes comparisons difficult. Also, we acknowledge the retrospective nature of the study and its inherent flaws. The strengths include the following: a single surgeon completed all the cases, and because of the military setting nearly all subjects where rehabilitated by the same 2 physical therapists, which ensures constancy of the accelerated program. We also attempted to mitigate bias by having a nonmilitary team member not involved in patient care perform the chart review and perform all satisfaction follow-up surveys.

Conclusion

This study suggests that a Broström procedure augmented with suture tape can allow for early safe functional rehabilitation without subsequent laxity and failure. Our data also found a sustained high level of patient satisfaction while preventing recurrence within a demanding military population. The early accelerated rehabilitation also allowed our institution to return soldiers back to agility drills 4 weeks sooner than our previous protocols.

Declaration of Conflicting Interests

The author(s) declared the following potential conflicts of interest with respect to the research, authorship, and/or publication of this article: Kevin D. Martin, DO, FAAOS, reports personal fees from Arthrex, outside the submitted work. ICMJE forms for all authors are available online.

Funding

The author(s) received no financial support for the research, authorship, and/or publication of this article.

ORCID iDs

Kevin D. Martin, DO, FAAOS, https://orcid.org/0000-0003-4070-6510
Nolan N. Andres, DO, https://orcid.org/0000-0002-8343-1513

References

1. Ahtikoski AM, Koskinen SO, Virtanen P, Kovanen V, Takala TE. Regulation of synthesis of fibrillar collagens in rat skeletal muscle during immobilization in shortened and lengthened positions. *Acta Physiol Scand*. 2001;172(2):131-140.
2. Barker HB, Beynnon BD, Renström PA. Ankle injury risk factors in sports. *Sports Med*. 1997;23:69-74.
3. Cameron KL, Owens BD, DeBerardino TM. Incidence of ankle sprains among active-duty members of the United States Armed Services from 1998 through 2006. *J Athlet Train*. 2009;45(1):29-38.
4. Choa BK, Parka JK, Choia SM, SooHoob NF. A randomized comparison between lateral ligaments augmentation using suture-tape and modified Broström repair in young female patients with chronic ankle instability. *Foot Ankle Surg*. 2019;25:137-142.
5. Coetzee J, Ellington K, Ronan JA, Stone RM. Functional results of open Broström ankle ligament repair augmented with suture tape. *Foot Ankle Int*. 2018;39(3):304-310.
6. DiGiovanni CW, Brodsky A. Current concepts: lateral ankle instability. *Foot Ankle Int*. 2006;27(10):854-866.
7. Fong DT, Hong Y, Chan LK, Yung PS, Chan KM. A systematic review on ankle injury and ankle sprain in sports. *Sports Med*. 2007;37:73-94.
8. Hale S, Hertel J. Reliability and sensitivity of the Foot and Ankle Disability Index in subjects with chronic ankle instability. *J Athlet Train*. 2005;40:35-40.
9. Harrington KD. Degenerative arthritis of the ankle secondary to long-standing lateral ligament instability. *J Bone Joint Surg Am*. 1979;61(3):354-361.
10. Hauschild VD, Lee T, Barnes S, Forrest L, Hauret K, Jones BH. The etiology of injuries in US army initial entry training. *U.S. Army Med Depart J*. 2018;2-18, 22-29.

11. Hirose K, Murakami G, Minowa T, Kura H, Yamashita T. Lateral ligament injury of the ankle and associated articular cartilage degeneration in the talocrural joint: anatomic study using elderly cadavers. *J Orthop Sci*. 2004;9(1): 37-43.
12. Kirk KL, Campbell JT, Guyton GP, Parks BG, Schon LC. ATFL elongation after Broström procedure: a biomechanical investigation. *Foot Ankle Int*. 2008;29(11):1126-1130.
13. Korkala O, Sorvali T. Twenty year results of the Evans operation for lateral instability of the ankle. *Clin Orthop Relat Res*. 2002;405:195-198.
14. Kurer M., Gooding C. The Foot & Ankle Disability Index (FADI) Score. Orthopaedic Scores website. http://www.orthopaedicscore.com/scorepages/foot_and_ankle_disability_index_fadi.html.
15. Maffulli N, Del Buono A, Maffulli GD, et al. Isolated anterior talofibular ligament Broström repair for chronic lateral ankle instability: 9-year follow-up. *Am J Sports Med*. 2013;41(4):858-864.
16. Maffulli N, Ferran NA. Management of acute and chronic ankle instability. *J Am Acad Orthop Surg*. 2008;16(10): 608-615.
17. Martin RL, Burdett RG, Irrgang JJ. Development of the Foot and Ankle Disability Index (FADI). *J Orthop Sports Phys Ther*. 1999;29:A32-A33.
18. Martin RL, Irrgang JJ. A survey of self-reported outcome instruments for the foot and ankle. *J Orthop Sports Phys Ther*. 2007;37(2):72-84.
19. Moe RH, Grotle M, Kjeken I, et al. Effectiveness of an integrated multidisciplinary osteoarthritis outpatient program versus outpatient clinic as usual: a randomized controlled trial. *J Rheumatol*. 2016;43(2):411-418.
20. Omar M, Petri M, Dratzidis A, et al. Biomechanical comparison of fixation techniques for medial collateral ligament anatomical augmented repair. *Knee Surg Sports Traumatol Arthrosc*. 2014;24:3982-3987.
21. Schuh R, Benca E, Willegger M, et al. Comparison of Broström technique, suture anchor repair, and tape augmentation for reconstruction of the anterior talofibular ligament. *Knee Surg Sports Traumatol Arthrosc*. 2016;24:1101-1107.
22. Tyson JJ, Bjerke B, Genuario J, Noonan TJ. Thromboembolic events after arthroscopic knee surgery: increased risk at high altitude. *Orthop J Sports Med*. 2014;2(2)(suppl).
23. Valderrabano V, Hintermann B, Horisberger M, Fung TS. Ligamentous posttraumatic ankle osteoarthritis. *Am J Sports Med*. 2006;34(4):612-620.
24. Valderrabano V, Horisberger M, Russell I, Dougall H, Hintermann B. Etiology of ankle osteoarthritis. *Clin Orthop Relat Res*. 2009;467(7):1800-1806.
25. Waldrop NE, Wijdicks CA, Jansson KS, LaPrade RF, Clanton TO. Anatomic suture anchor versus the Broström technique for anterior talofibular ligament repair: a biomechanical comparison. *Am J Sports Med*. 2012;40(11):2590-2596.
26. Waterman B, Owens B, Davey S, Zacchilli M, Belmont P. The epidemiology of ankle sprains in the United States. *J Bone Joint Surg Am*. 2010;92:2279-2284.