STANFORD
SCHOOL OF MEDICINE

Stanford University Medical Center

Department of Radiology
Division of Nuclear Medicine and Molecular Imaging

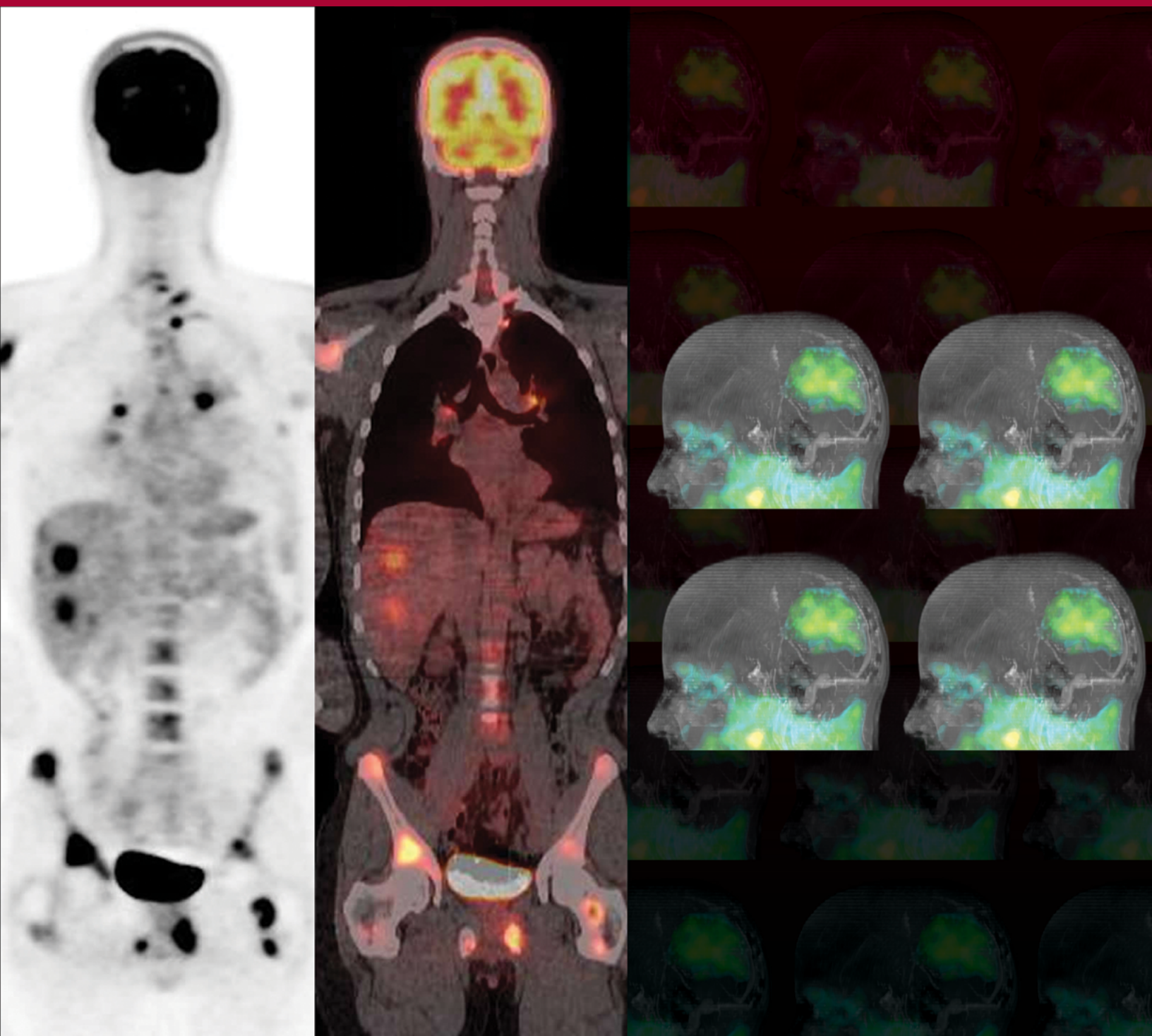

Nuclear Medicine Faculty and Staff

Stanford Faculty

Andrei Iagaru, MD
Section Co-Chief (Acting)
Assistant Professor of Radiology (Nuclear Medicine)
Residency Program Director

Andrew Quon, MD
Section Co-Chief (Acting)
Assistant Professor of Radiology
(Nuclear Medicine)
Fellowship Program Director

Sanjiv Sam Gambhir, MD, PhD
Chairman, Deparment of Radiology
Professor of Radiology and Bioengineering
Professor of Materials Science and Engineering (by courtesy)
Director, Molecular Imaging Program at Stanford (MIPS)

Michael L. Goris, MD, PhD
Professor Emeritus of Radiology (Nuclear Medicine)

Craig S. Levin, PhD
Professor of Radiology, Physics, and Electrical Engineering
Director, Molecular Imaging Instrumentation Laboratory
Core Member, Molecular Imaging Program at Stanford

I. Ross McDougall, MD, PhD
Professor of Radiology and Medicine,
Emeritus (Nuclear Medicine)

Erik Mittra, MD, PhD
Clinical Instructor of Radiology
(Nuclear Medicine)

Joseph Wu, MD, PhD
Associate Professor of Medicine (Cardiology) and Radiology

VA Faculty

George Segall, MD
Professor of Radiology (Nuclear Medicine)
Chief, Nuclear Medicine Service VA Palo Alto

Minal Vasanawala, MD
Clinical Assistant Professor of Radiology
(Nuclear Medicine)

Adjunct Clinical Faculty

Christine Keeling, MD
Clinical Associate Professor (Affiliated)
of Radiology
(Nuclear Medicine)

Jeffrey Tseng, MD
Clinical Assistant Professor (Affiliated)
of Radiology
(Nuclear Medicine)

Cyclotron Radiochemistry Facility

Frederick T. Chin, PhD
Instructor, Radiology
(Nuclear Medicine)
Head, Cyclotron Radiochemistry

Sandeep Apte, PhD
Postdoctoral Fellow

Amit Hetsron, MS
Radiochemistry
Research Assistant

Aileene Hoehne, PhD
Postdoctoral Fellow

Michelle L. James, PhD
Postdoctoral Fellow

So-Hee Kim, MS
Radiochemistry
Research Assistant

Zheng Miao, PhD
Postdoctoral Fellow



George Montoya
Cyclotron Production
Technician

Mohammed Namavari, PhD
Radiochemistry
Senior Scientist

Arutselvan Natarajan, PhD
Instructor, Radiology

Bin Shen, PhD
Postdoctoral Fellow

Murugesan Subbarayan, PhD
Radiochemistry Senior
Research Associate

Nuclear Medicine Technologists

VA PAHCS

Kent Hutchings
NMTTP Director

Julie Loero
CNMT

SUMC

Paulo Castaneda
CNMT

Christabel Chavez
CNMT

Elizabeth Farmer
CNMT

Christine Fujii
CNMT



Matthew Gabriele
CNMT

Nora Gurevich
CNMT

Shawna Kinsella
CNMT

Luan Nguyen
CNMT

Jayesh Patel
Technical Manager

Administration

Lindee Burton
Research Coordinator

Ming Chou
Division Manager

Sofia Gonzales
Residency and
Fellowship Coordinator

Elizabeth Gill
Administrative Associate

Sondra Horn
Finance Manager

Euodia Jonathan
Research Coordinator

Donna Niernberger
Administrative Associate

Mary Troyer
Administrative Associate

Patient Care

The Division of Nuclear Medicine and Molecular Imaging in the Department of Radiology is a diversified, active service performing numerous diagnostic and therapeutic procedures. The campus location in the Medical Center allows full usage of the Stanford University resources, including Physics, Electrical Engineering, Radiation Biology and the Linear Accelerator.

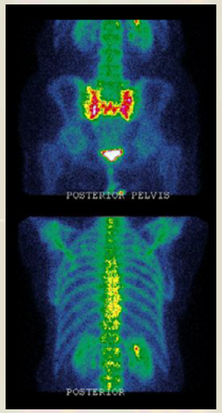

What is Nuclear Medicine?

Nuclear medicine involves the use of small amounts of radioactive materials (or tracers) to help diagnose and treat a variety of diseases. Nuclear medicine determines the cause of the medical problem based on the function of the organ, tissue or bone. This is how nuclear medicine differs from an x-ray, ultrasound or any other diagnostic test that determines the presence of disease based on structural appearance.

Millions of nuclear medicine tests are performed each year in the United States alone. Nuclear medicine tests (also known as scans, examinations, or procedures) are safe and painless. In a nuclear medicine test, the radioactive material is introduced into the body by injection, ingestion, or inhalation. Different tracers are used to study different parts of the body. The amount of tracer used is carefully selected to provide the least amount of radiation exposure to the patient while still ensuring an accurate test. A special camera (scintillation or gamma camera) is used to take pictures of your body. The camera does this by detecting the tracer in the organ, bone or tissue being imaged and then records this information on a computer screen or on film. Generally, nuclear medicine tests are not recommended for pregnant women because unborn babies have a greater sensitivity to radiation than children or adults. If you are pregnant or think that you are pregnant, your doctor may order a different type of diagnostic test.

What are the Benefits of Nuclear Medicine?

Nuclear medicine is a safe, painless, and cost-effective way of gathering information that may otherwise be unavailable or require a more expensive and risky diagnostic test. One unique aspect of a nuclear medicine test is its extreme sensitivity to abnormalities in an organ's function. As an integral part of patient care, nuclear medicine is used in the diagnosis, management, treatment and prevention of serious disease. Nuclear medicine imaging procedures often identify abnormalities very early in the progression of a disease before some medical problems are apparent with other diagnostic tests. This early detection allows a disease to be treated early in its course when there may be a better prognosis. Although nuclear medicine is commonly used for diagnostic purposes, it also has valuable therapeutic applications such as in the treatment of hyperthyroidism, thyroid cancer, blood imbalances, and bony pain from certain types of cancer.

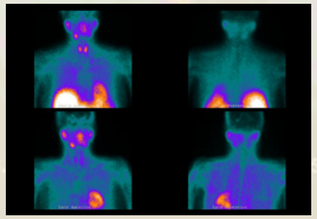

Is Nuclear Medicine Safe?

Nuclear medicine procedures are among the safest diagnostic imaging exams available. A patient only receives a small amount of a radiopharmaceutical, just enough to provide sufficient diagnostic information.

Although we do not think much about it, everyone is continually exposed to radiation from natural and manmade sources. For most people, natural background radiation from space, rocks, soil, and even carbon and potassium atoms in his or her own body, accounts for 85 percent of their annual exposure. Additional exposure is received from consumer products such as household smoke detectors, color television sets, and luminous dial clocks. The remainder is from x-rays and radioactive materials used for medical diagnosis and therapy. With most nuclear medicine procedures, the patient receives about the same amount of radiation as that acquired in a few months of normal living.

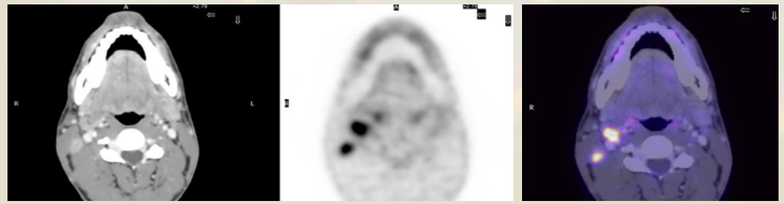

What is Positron Emission Tomography (PET)?

PET is a powerful diagnostic test that is having a major impact on the diagnosis and treatment of disease. Because disease is a biological process and PET is a biological imaging examination, PET can detect and stage most cancers, often before they are evident through other tests. PET can also give physicians important early information about heart disease and many neurological disorders, like Alzheimer's. A PET scan examines the body's chemistry. Most common medical tests, like CT and MR scans, only show details about the structure of your body. PET is different. It also provides information about function. With a single PET procedure, physicians can collect images of function throughout the entire body, uncovering abnormalities that might otherwise go undetected.

For example, a PET scan is the most accurate, non-invasive way to tell whether a tumor is benign or malignant, sparing patients expensive, often painful diagnostic surgeries and suggesting treatment options earlier in the course of the disease. And although cancer spreads silently in the body, PET can inspect all organs of the body for cancer in a single examination!

PET is able to detect extremely small cancerous tumors and very subtle changes of function in the brain and heart. This allows physicians to treat these diseases earlier and more accurately. The earlier the diagnosis, the better the chance for treatment.

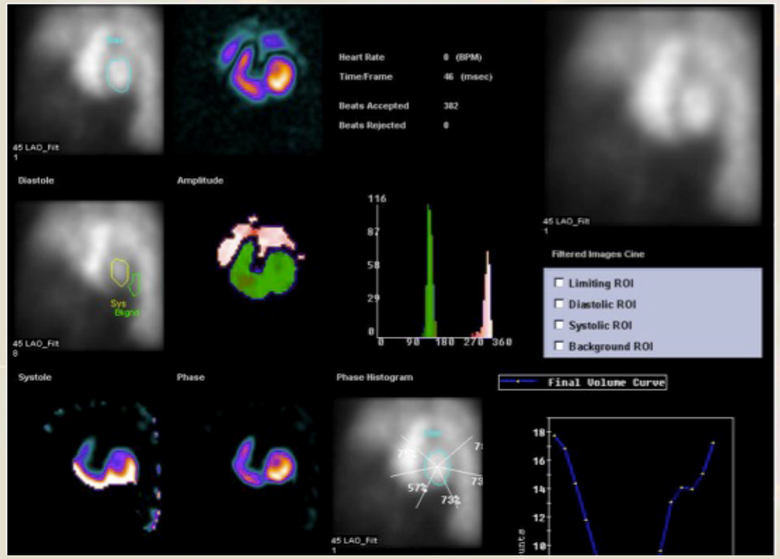

Educational Programs

http://nuclearmedicine.stanford.edu/education/

The Division of Nuclear Medicine and Molecular Imaging offers several programs for medical students and residents and fellows all of which feature a mixture of traditional didactics with strong clinical exposure. Our residents and students service three main hospital facilities: The VA Palo Alto, Lucile Packard Children's Hospital, and Stanford University Hospital. There are ample clinical research opportunities at the Medical Center and more basic science oriented projects can be found in the Molecular Imaging Program based at the Clark Center.

Nuclear Medicine Residency Program

Program Director: Andrei Iagaru, MD

The Division of Nuclear Medicine and Molecular Imaging is training the next generation of world-wide leaders in academic and clinical Nuclear Medicine. We offer a three year residency approved by the American Board of Nuclear Medicine and the Accreditation Council for Graduate Medical Education. The Nuclear Medicine Residency program combines training in basic nuclear instrumentation technology, molecular imaging, and clinical nuclear medicine. We offer a clinical program centered at Stanford University with a Nuclear Medicine satellite that includes the VA Hospital. Training in conventional Nuclear Medicine and PET/CT are provided. A strong basic science program in molecular imaging is also a unique feature of the program.

PET/CT Fellowship Program

Program Director: Andrew Quon, MD

The clinical fellowship focuses on all aspects of clinical PET/CT imaging and includes clinical research projects that evaluate emerging molecular imaging technologies related to PET. Clinical duties include helping with the PET/CT service and joint Nuclear Medicine/Radiology read-outs. Features include intensive training in the interpretation of FDG PET/CT, the formulations of imaging protocols, and the daily management of the PET/CT scanner. Training from both Radiology and Nuclear Medicine faculty allow for a unique learning experience not available in most programs. The fellowship lasts one year and is renewable at the end of each academic year.

Clerkships

Diagnostic Radiology and Nuclear Medicine Clerkship
This clerkship is designed to familiarize medical students with the interpretation of medical images and nuclear medicine studies. The clerkship consists of four weeks of combination seminar and lecture sessions of approximately 3-5 hours per day, with special emphasis on methods used in interpreting chest radiographs, cardiac series, abdominal films, bone films and routine nuclear medicine investigations. Introductory sessions concerning ultrasound, CT and MRI examinations, and mammography are also included. Emphasis of the clerkship is on correlating radiographic or nuclear medicine findings and clinical data in order to arrive at differential diagnoses. Indications for various examinations and radiographic and clinical methods of further exploration of suspected abnormalities are stressed.

Nuclear Medicine Clerkship
This clerkship acquaints students with the basic principles of nuclear medicine, the instrumentation used, the gamut of procedures available, and the judgments used to select specific diagnostic or therapeutic procedures and interpret results. The experience should be especially helpful for students planning a career in diagnostic radiology, nuclear medicine, cardiology, or oncology. The student experience includes instruction in radiologic physics, instrumentation, responsibility for selected isotopic procedures, daily teaching rounds for review of all cases studies, and special conferences.

Clinical Elective in Diagnostic Radiology & Nuclear Medicine
Provides an opportunity for a student in the clinical years to have a clinical experience in Diagnostic Radiology or Nuclear Medicine, quality and duration to be decided upon by the student and a faculty preceptor in the Department.

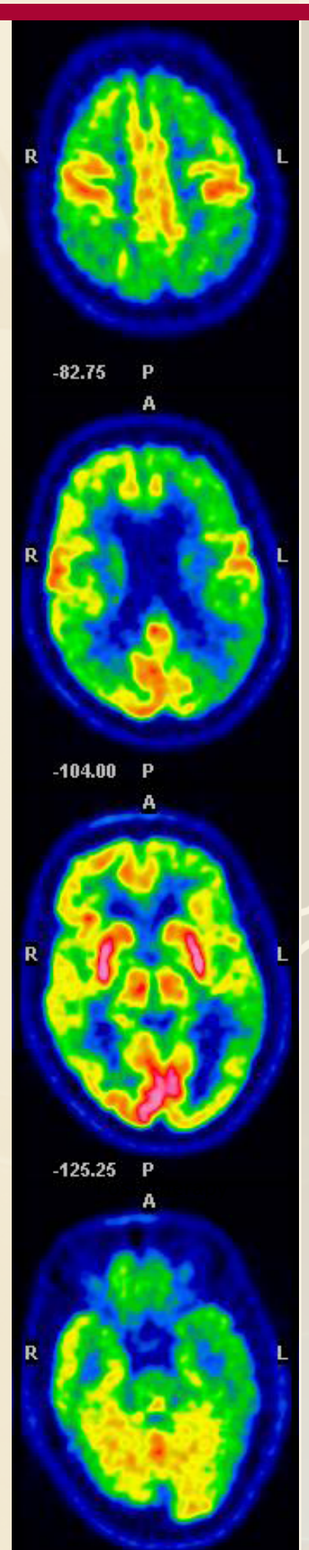

Research

Molecular Imaging Program at Stanford (MIPS)

http://mips.stanford.edu/

The Molecular Imaging Program at Stanford (MIPS) was established as an inter-disciplinary program to bring together scientists and physicians who share a common interest in developing and using state-of-the-art imaging technology and developing molecular imaging assays for studying intact biological systems. A multimodality approach using imaging technologies such as positron emission tomography (PET), single photon emission computed tomography (SPECT), digital autoradiography, magnetic resonance imaging (MRI), magnetic resonance spectroscopy (MRS), optical bioluminescence, optical fluorescence, and ultrasound are all technologies under active development and investigation. The goals of the program are to fundamentally change how biological research is performed with cells in their intact environment in living subjects and to develop new ways to diagnose diseases and monitor therapies in patients. Areas of active investigation are cancer research, microbiology/immunology, developmental biology and pharmacology.

The program consists of over 100 scientists and is directed by Sanjiv Sam Gambhir, MD, PhD

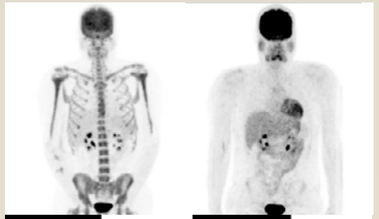

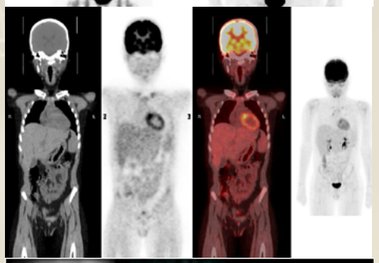

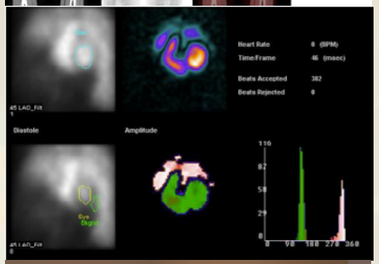

Multimodality Molecular Imaging Lab

Sanjiv Sam Gambhir, MD, PhD
http://mips.stanford.edu/research/mmil.html

This laboratory is developing imaging assays to monitor fundamental cellular/molecular events in living subjects including patients. Technologies such as micro positron emission tomography (microPET), bioluminescence optical imaging, fluorescence optical imaging, micro computerized axial tomography (microCAT), ultrasound, and photoacoustics are all being actively investigated in small animal models. Our goals are to marry fundamental advances in molecular/cell biology with those in biomedical imaging to advance the field of molecular imaging. We have a particular interest in cancer biology and gene therapy. Research in early cancer detection and pharmacological therapy assessment is also being performed.

Assays to interrogate cells for mRNA levels, cell surface antigens, intracellular proteins and protein-protein interactions are under active development. We are also extending many of these approaches for human clinical applications using optical and PET-CT technologies.

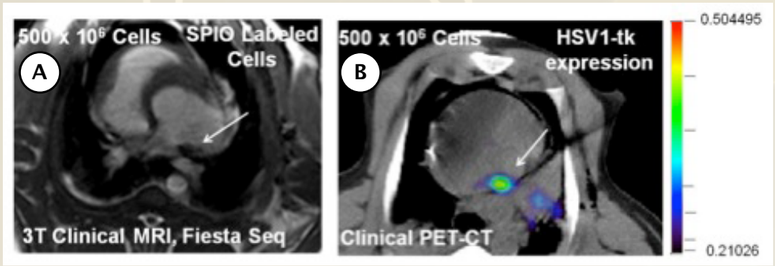

Figure 1 Multimodality Imaging of Mesenchymal Stem Cells in Swine Heart 500 x 10^6 Rat Mesenchymal stem cells were retrovirally labeled with triple fusion reporter gene (Firefly luciferase (Fluc), Green Fluorescent Protein (GFP), HSV-sr39tk), sorted 3 times independently for high expressing cells, labeled overnight with Superparamagnetic Iron Oxide Particles and injected posteriorly in the superior portion of the left ventricle of adult swine. (A) Clinical MRI imaging using FIESTA sequence and a 3T magnet demonstrates presence of dephased (dark) region (white arrow). (B) Clinical PET-CT imaging demonstrating cell injection that correlates (white arrow) with image in (A). Scale represents Standard Uptake Values (SUV). Cell signal from PET-CT correlates with cell number injected.





Research

Molecular Imaging Instrumentation Lab

Craig Levin, PhD
http://miil.stanford.edu

Dr. Levin's laboratory focuses on advancing instrumentation and algorithms for positron emission tomography (PET). The figure below depicts one of the lab's projects which is to develop the world's first 1 mm resolution clinical PET system which can focus in on spots and organs of interest. If successful, this system will be able to visualize and quantify a fewer number of diseased cells, with a goal to achieve earlier detection of diseases such as breast cancer. (a) The system is configured as two detector panels that collect and position incoming 511 keV photons with 1 mm resolution; (b) The thousands of miniscule scintillation detectors are read out with sensitive readout electronics integrated with an advanced data acquisition system; (c) The detector employs a "3-D positioning" scintillation detector concept that helps to realize ultra-high spatial resolution, high contrast resolution, and high photon sensitivity everywhere between the two panels; (d) Test results with individual detectors yield < 1 mm resolution, but the goal for the full system is 1 mm resolution.

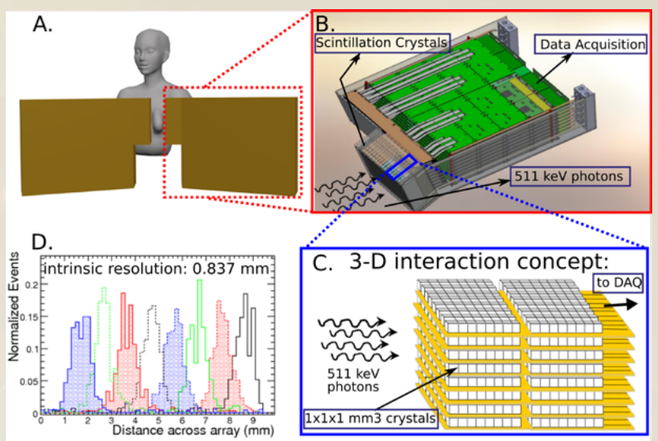

Equipment

Cyclotron Radiochemistry Facility

http://mips.stanford.edu/public/lucas.adp

The radiochemistry facility is located on the first floor of the Lucas Expansion building. The heart of the radiochemistry facility is a GE PETrace cyclotron, which is used for the production of radioisotopes for clinical and research use. Surrounding the cyclotron are an FDG production lab and research hot labs. The hot labs, fully equipped with hot cells and shielded fume hoods, are used for the production of research radiopharmaceuticals as well as to provide space for radiochemistry research to develop new radiopharmaceuticals. These radiopharmaceuticals are used to support both clinical and research PET studies at the Stanford University Medical Center and the Stanford Center for Innovation in In-Vivo Imaging (SCI³).

Philips Skylight

The Skylight dual head spect camera is a gantry free camera which creates an open floor design. This design allows for easier transfer of patients and in some cases, allows for imaging studies to be done in patient beds. At Stanford, we use the skylight as our primary cardiac camera and it is used for in-patient imaging.

GE Infinia Hawkeye SPECT/CT

The Infinia dual head spect camera is a combination whole body and spect gamma camera combined with a registered CT scanner. This feature allows for more precise organ and lesion localization. At Stanford, we use the Infinia as our primary oncology imaging camera.

Digirad (Mobile SPECT)

The Digirad mobile camera uses solid state technology to acquire images. It has a smaller field of view which allows more flexibility in imaging smaller organs in the body or imaging of pediatric patients. The portable feature of the camera allows imaging of critically ill patients at bedside. At Stanford, we use the flexibility of the Digirad camera to increase our productivity and offer greater patient comfort to our in-patients and smaller patients.

D-SPECT

The D-SPECT™ Cardiac Imaging System can complete a Gated SPECT study in only 2 minutes. This is a significant improvement over current technologies that require 12-20 minutes. This incredibly fast, high quality acquisition can be achieved through a novel camera technology. The seated position also allows for significantly greater patient comfort and compliance.

GE Discovery D600/D690

The GE PET/CT scanner combines two powerful diagnostic tools. Overlaying the PET scan data with the CT scan data allows physicians to quickly and more accurately diagnose, plan treatment and monitor treatment. At Stanford, we use PET/CT scanning for all three of these important functions.

Conferences

Nuclear Medicine Clinical Journal Club

Twice per month, 12:00 pm – 1:00 pm
Location: Nuclear Medicine Library, Room H2211

CME Radiology Grand Rounds

1st Tuesdays, 7:30 am - 8:30 am
3rd Thursdays, 5:30 pm - 6:30 pm
Clark Auditorium/LKSC/LPCH Auditorium

Nuclear Medicine Case Conference

Wednesdays, 12:00 pm
Location: Nuclear Medicine Reading Room

Basic Science Lectures

Thursdays, 7:30 am - 8:30 am
Location: Nuclear Medicine Library, Room H2211

Molecular Imaging Journal Club

Thursdays (twice per month), 12:00 pm - 1:00 pm
Location: Edwards Bldg, Room R358

Nuclear Medicine Core Lectures

Fridays, 7:30 am - 8:30 am
Location: Nuclear Medicine Library, Room H2211

Tumor Boards

Location: Cancer Center, Workroom A or B

Recent Clinical Awards

Year 2009

Dr. Joseph Wu received the 2009 Douglas P. Zipes Distinguished Young Scientist Award
Dr. Andrei Iagaru received the Alavi-Mandell Award from the Society of Nuclear Medicine
Drs. Andrei Iagaru, Erik Mittra and Michael Goris received the 2009 SNM Image of the Year
Drs. Craig Levin, Angela Foudray and Frezghi Habte authors of Top Ten Cited Papers in Physica Medica
Dr. Sam Gambhir received the 2009 RSNA Outstanding Research Award
Dr. Andrei Iagaru received a Developmental Cancer Research Award in Translational Science from Stanford's Cancer Center
Dr. Andrei Iagaru received the 2009 Scientist Award, Western Regional SNM Annual Meeting

Year 2010

Dr. Joseph Wu received the Presidential Early Career Award for Scientists and Engineers
Dr. Andrei Iagaru received the 2010 SNM/ACNM Mid-Winter Conference Best Essay Award
Dr. Andy Quon received the Society of Nuclear Medicine's Correlative Imaging Council Walter Wolf Young Investigator Award
Dr. Ross McDougall received the Albion Walter Hewlett Award

Year 2011

Dr. Andrei Iagaru received the Best Essay Award at the 2011 Mid-Winter SNM/ACNM Annual Meeting
Dr. Andrei Iagaru received the Best Presentation by a Young Professional at the 1st Sino-American Conference on Nuclear Medicine
Dr. Andrei Iagaru received the 2nd place Nuclear Oncology Council Young Investigator Award at the 58th SNM Annual Meeting
Dr. Andrew Quon received the 2011 SNM Image of the Year Award
Dr. Joseph Wu received the California Institute of Regenerative Medicine Basic Biology Award
Dr. Sam Gambhir received SNM's 2011 Georg Charles de Hevesy Nuclear Pioneer Award

Recent Clinical Publications 2008 - 2011

Mittra ES, Goris ML, Iagaru AH, Kardan A, Burton L, Berganos R, Chang E, Liu S, Shen B, Chin FT, Chen X, Gambhir SS. Pilot Pharmacokinetic and Dosimetric Studies of 18F-FPPRGD2: A PET Radiopharmaceutical Agent for Imaging {alpha}v{beta}3 Integrin Levels. Radiology. 2011; 260(1): 182-91.

Iagaru AH, Mittra ES, Gambhir SS. 18F FDG PET/CT in Cancers of the Head and Neck: What is the Definition of Whole-Body Scanning? Molecular Imaging and Biology. 2011;13(2): 362-7.

Zissen MH, Kunz P, Subbarayan M, Chin FT, Conti PS, Fisher GA, Quon A. 18F-5-fluorouracil Dynamic Positron Emission Tomography/Computed Tomography Shows Decreased Tracer Activity After Bevacizumab in Colorectal Metastases. Nuclear Medicine Communications. 2011; 32(5): 343-7.

Mittra ES, Iagaru AH, Leung AN. Case 166: Metastatic Left Pulmonary Artery Sarcoma. Radiology. 2011; 258(2): 645-8.

McDougall IR, Iagaru AH. Thyroid stunning: Fact or Fiction? Seminars in Nuclear Medicine. 2011; 41(2): 105-12.

Bahn Chair RS, Burch HB, Cooper DS, Garber JR, Greenlee MC, Klein I, Laurberg P, McDougall IR, Montori VM, Rivkees SA, Ross DS, Sosa JA, Stan MN. Hyperthyroidism and Other Causes of Thyrotoxicosis: Management Guidelines of the American Thyroid Association and American Association of Clinical Endocrinologists. Thyroid. 2011; 21: 593-647.

Sisson JC, Freitas J, McDougall IR, Dauer LT, Hurley JR, Brierley JD, Edinboro CH, Rosenthal D, Thomas MJ, Wexler JA, Asamoah E, Avram AM, Milas M, Greenlee C. Radiation Safety in the Treatment of Patients with Thyroid Diseases by Radioiodine (1)(3)(1)i: practice recommendations of the american thyroid association. Thyroid. 2011; 21; 335-346.

Do BH, Mari C, Tseng JR, Quon A, Rosenberg J, Biswal S. Pattern of 18F-FDG Uptake in the Spinal Cord in Patients with Non-Central Nervous System Malignancy. Spine (Phila Pa 1976). 2011[Epub ahead of print].

Chennupati SK, Quon A, Kamaya A, Pai RK, La T, Krakow TE, Graves E, Koong AC, Chang DT. Positron Emission Tomography for Predicting Pathologic Response After Neoadjuvant Chemoradiotherapy for Locally Advanced Rectal Cancer. American Journal of Clinical Oncology. 2011 [Epub ahead of print].

Chin FT, Shen B, Liu S, Berganos RA, Chang E, Mittra ES, Chen X, Gambhir SS. First Experience with Clinical-Grade [(18)F] FPP(RGD) (2): An Automated Multi-step Radiosynthesis for Clinical PET Studies. Molecular Imaging and Biology. 2011[Epub ahead of print].

Iagaru AH, Mittra ES, Dick DW, Gambhir SS. Prospective Evaluation of (99m)Tc MDP Scintigraphy, (18)F NaF PET/CT, and (18)F FDG PET/CT for Detection of Skeletal Metastases. Molecular Imaging and Biology. 2011 [Epub ahead of print].

Murphy JD, Chisholm KM, Daly ME, Wiegner EA, Truong D, Iagaru AH, Maxim PG, Loo BW Jr, Graves EE, Kaplan MJ, Kong C, Le QT. Correlation Between Metabolic Tumor Volume and Pathologic Tumor Volume in Squamous Cell Carcinoma of the Oral Cavity. Radiotherapy & Oncology. 2011[Epub ahead of print].

Lee P, Bazan JG, Lavori PW, Weerasuriya DK, Quon A, Le QT, Wakelee HA, Graves EE, Loo BW Jr. Metabolic Tumor Volume is an Independent Prognostic Factor in Patients Treated Definitively for Non-Small-Cell Lung Cancer. Clinical Lung Cancer. 2011 [Epub ahead of print].

Iagaru AH, Mittra ES, Ganjoo K, Knox SJ, Goris ML. 131I-Tositumomab (Bexxar®) vs. 90Y-Ibritumomab (Zevalin®) Therapy of Refractory/Relapsed Non-Hodgkin Lymphoma. Molecular Imaging and Biology. 2010; 12(2): 198-203.

Mittra ES, Iagaru AH. 18F FDG PET and PET/CT for Evaluating Primary Bone Tumors. PET Clinic. 2010; 5(3): 327-40.

Kao D, Witteles R, Quon A, Wu J, Gambhir SS, Fowler M. Rosiglitazone Increases Myocardial Glucose Metabolism in Insulin-Resistant Cardiomyopathy. Journal of the American College of Cardiology. 2010; 55(9): 926-927.

Mansouri MA, Iagaru AH. F-18 FDG PET/CT Demonstration of Lymphohistiocytic Meningitis. Clinical Nuclear Medicine. 2010; 35(8): 633-4.

Lin F, Iagaru AH. Current Concepts and Future Directions in Radioimmunotherapy. Current Drug Discovery Technologies. 2010; 7(4): 253-62.

Schellenberg D, Quon A, Minn AY, Graves EE, Kunz P, Ford JM, Fisher GA, Goodman KA, Koong AC, Chang DT. 18Fluorodeoxyglucose PET is Prognostic of Progression-Free and Overall Survival in Locally Advanced Pancreas Cancer Treated with Stereotactic Radiotherapy. International Journal of Radiation Oncology*Biology*Physics. 2010; 77(5): 1420-5.

Segall GM. Therapy Response Evaluation with Positron Emission Tomography-Computed Tomography. Seminars in Ultrasound, CT and MR. 2010; 31(6): 490-5.

Segall GM, Delbeke D, Stabin MG, Even-Sapir E, Fair J, Sajdak R, Smith GT; SNM. SNM Practice Guideline for Sodium 18F-fluoride PET/CT Bone Scans 1.0. Journal of Nuclear Medicine. 2010; 51(11): 1813-20.

Renier C, Yao C, Goris ML, Ghosh M, Katznelson L, Nowles K, Gambhir SS, Wapnir I. Endogenous NIS Expression in Triple Negative Breast Cancers. Annals of Surgical Oncology. 2009; 16(4): 962-968.

Iagaru AH, Gambhir SS, Goris ML. Tumor Metabolic Phenotypes on [18F] FDG PET. Journal of Nuclear Medicine. 2009; 50(6): 1011-1012.

Iagaru AH, Mittra ES, Goris ML, Gambhir SS. Combined [18F]-FDG and Fluoride Approach in PET/CT Imaging: Is There a Clinical Future? Journal of Nuclear Medicine. 2009; 50(6): 1011.

Yerushalmi D, Mullick R, Quon A, Fahrig R, Pelc N, Fann J, Gambhir SS. Simulation Virtual PET/CT 3-D Bronchoscopy Imaging Using a Physical Porcine Lung-heart Phantom. Molecular Imaging and Biology. 2009; 11(4): 275-282.

Mittra ES, El-Maghraby T, Rodriguez C, Quon A, McDougall I, Gambhir SS, Iagaru AH. Efficacy of [18F] FDG PET/CT in the Evaluation of Patients with Recurrent Cervical Carcinoma. European Journal of Nuclear Medicine and Molecular Imaging. 2009; 36:1952-1959.

Iagaru AH, Kundu R, Jadvar H, Nagle D. Evaluation by 18F-FDG-PET of Patients with Anal Squamous Cell Carcinoma. Hellenic Journal of Nuclear Medicine. 2009; 12(1): 26-9.

Zissen MH, Quon A. Focal Fat Mimicking Multiple Hepatic Metastases on FDG PET/CT Imaging. European Journal of Nuclear Medicine and Molecular Imaging. 2009; 36(9): 1527.

Kim J, Quon A, Humke E, Ford JM, Koong AC. Detection of Solitary Humeral Metastasis From Pancreatic Adenocarcinoma with F-18 FDG PET/CT. Clinical Nuclear Medicine. 2009 May; 34(5): 312-3.

Recent Clinical Publications 2008 - 2011

Chang DT, Schellenberg D, Shen J, Kim J, Goodman KA, Fisher GA, Ford JM, Desser T, Quon A, Koong AC. Stereotactic Radiotherapy for Unresectable Adenocarcinoma of the Pancreas. Cancer. 2009; 115(3): 665-72.

Goris ML, Robinson TE. Sampling Density for the Quantitative Evaluation of Air Trapping. Pediatric Radiology. 2009; 39(3): 221-5.

Renier C, Yao C, Goris ML, Ghosh M, Katznelson L, Nowles K, Gambhir SS, Wapnir I. Endogenous NIS Expression in Triple-Negative Breast Cancers. Annals of Surgical Oncology. 2009; 16(4): 962-8.

Robinson TE, Trapnell BC, Goris ML, Quittell LM, Cornfield DN. Quantitative Analysis of Longitudinal Response to Aerosolized Granulocyte-Macrophage Colony-Stimulating Factor in Two Adolescents with Autoimmune Pulmonary Alveolar Proteinosis. Chest. 2009; 135(3): 842-8.

Iagaru AH, Mittra ES, Yaghoubi SS, Dick DW, Quon A, Goris ML, Gambhir SS. Novel Strategy for a Cocktail 18F-fluoride and 18F-FDG PET/CT Scan for Evaluation of Malignancy: Results of the Pilot-Phase Study. Journal of Nuclear Medicine. 2009; 50(4): 501-5.

Louie JD, Kothary N, Kuo WT, Hwang GL, Hofmann LV, Goris ML, Iagaru AH, Sze DY. Incorporating Cone-Beam CT Into the Treatment Planning for Yttrium-90 Radioembolization. Journal of Vascular and Interventional Radiology. 2009; 20(5): 606-13.

McDougall IR. The Case for Obtaining a Diagnostic Whole-Body Scan Prior to Iodine 131 Treatment of Differentiated Thyroid Cancer. Thyroid. 2009; 19(8): 811-3.

Mittra ES, McDougall IR. Cutaneous Graft-versus-Host Disease on Tc-99m Leukocyte Scintigraphy. Clinical Nuclear Medicine. 2009; 34(12): 894-5.

Mittra ES, Quon A. Positron Emission Tomography/Computed Tomography: The Current Technology and Applications. Radiologic Clinics of North America. 2009; 47(1): 147-60.

Iagaru AH, Masamed R, Chawla S, Menendez L, Fedenko A, Conti PS. 18F FDG PET and PET/CT Evaluation of Response to Neoadjuvant Chemotherapy in Musculoskeletal and Soft-Tissue Sarcomas. Clinical Nuclear Medicine. 2008; 33(1): 8-13.

Iagaru AH, Goris ML, Gambhir SS. Perspectives of Molecular Imaging and Radioimmunotherapy in Lymphoma. Radiologic Clinics of North America. 2008; 46(2): 243-252.

Iagaru AH, Gambhir SS, Goris ML. 90Y-Ibritumomab (Zevalin®) Therapy in Refractory Non-Hodgkin's Lymphoma: Observations from 111In-Ibritumomab Pre-Treatment Imaging. Journal of Nuclear Medicine. 2008; 49(11): 1809-1812.

Iagaru AH, Mittra ES, McDougall IR, Quon A, Gambhir SS. 18F FDG PET/CT Evaluation of Patients with Ovarian Carcinoma. Nuclear Medicine Communications. 2008; 29(12): 1046-51.

Quon A, Chang S, Chin F, Kamaya A, Dick D, Loo Jr. B, Gambhir SS, Koong A. Initial Evaluation of [18F] Fluorothymidine (FLT) PET/CT Scanning for Primary Pancreatic Cancer. European Journal of Nuclear Medicine and Molecular Imaging. 2008; 35(3): 527-531.

Iagaru AH, Wang Y, Mari C, Quon A, Goris ML, Horning S, Gambhir SS. (18)F-FDG-PET/CT Evaluation of Response to Treatment in Lymphoma: When Is The Optimal Time For the First Re-evaluation Scan? Hellenic Journal of Nuclear Medicine. 2008; 11(3): 153-6.

Mittra ES, Niederkohr RD, Rodriguez C, El-Maghraby T, McDougall IR. Uncommon causes of thyrotoxicosis. Journal of Nuclear Medicine. 2008; 49(2):265-78.

Iagaru AH, Goris ML. Rhabdomyosarcoma Diffusely Metastatic to the Bone Marrow: Suspicious Findings on 99mTc-MDP Bone Scintigraphy Confirmed by (18)F-18 FDG PET/CT and Bone Marrow Biopsy. European Journal of Nuclear Medicine and Molecular Imaging. 2008; 35(9):1746.

Segall GM. A New Paradigm to Increase Utilization of PET/CT. Journal of Nuclear Medicine. 2008; 49(6): 53N-56N.

Segall GM. Session 3: Strategies to Engage Referring Physicians and Increase Utilization of Clinical Molecular Imaging. Journal of Nuclear Medicine. 2008; 49(6): 52N-53N.

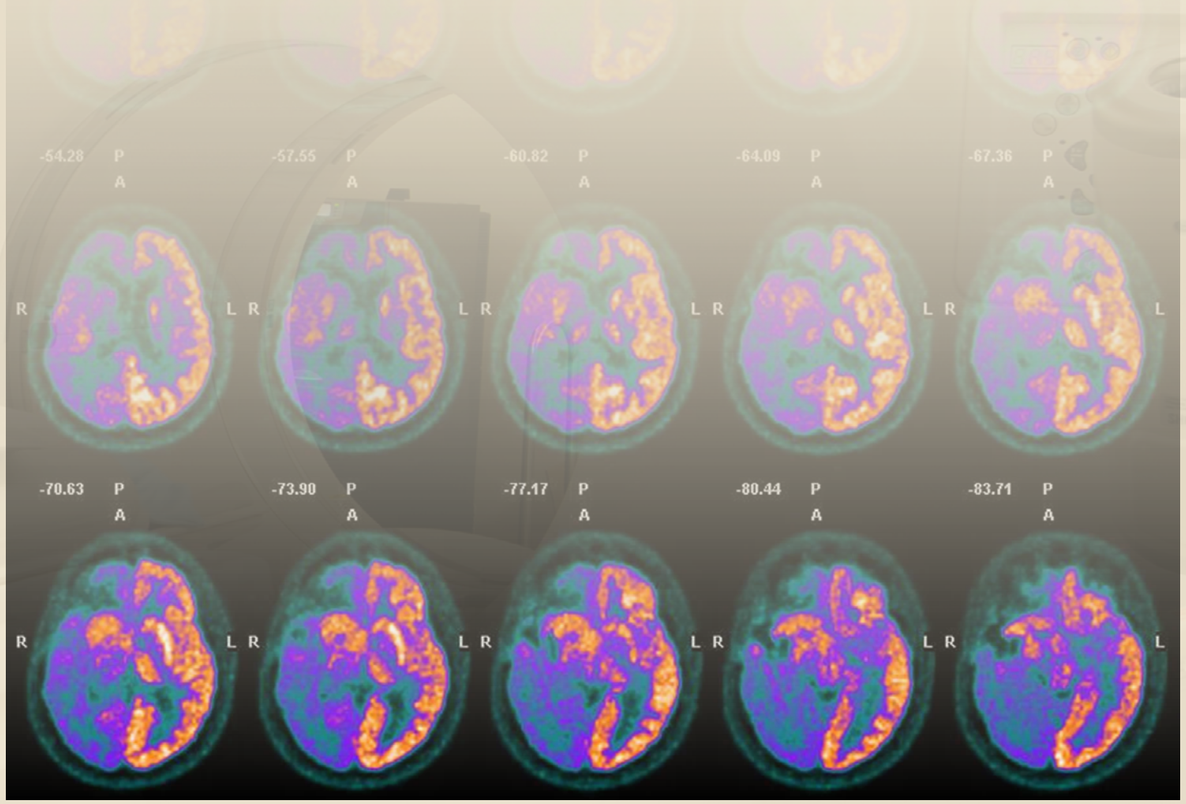

STANFORD NUCLEAR MEDICINE
300 Pasteur Drive, Stanford, CA 94305
Nuclear Medicine and Molecular Imaging Clinic: (650) 723-6855

http://nuclearmedicine.stanford.edu/