T1 Mapping and ECV Estimates at 3T in Pediatric Subjects with Duchenne Muscular Dystrophy and Healthy Controls

Nyasha G. Maforo[1,2], Patrick Magrath[1,3], Kévin Moulin[5], Jiaxin Shao[1], Kavya Umachandran[3], Grace Kim[1], Pierangelo Renella[1], Nancy Halnon[4], Holden Wu[1,2,3], and Daniel B. Ennis[5]

[1] Department of Radiological Sciences, UCLA, Los Angeles, CA, United States
[2]Physics and Biology in Medicine IDP, UCLA, Los Angeles, CA, United States
[3]Department of Bioengineering, UCLA, Los Angeles, CA, United States
[4]Department of Pediatrics (Cardiology), UCLA, Los Angeles, CA, United States
[5]Department of Radiology, Stanford University, Stanford, CA, United States

UCLA
Magnetic Resonance Research Labs

Disclosures

I have nothing to disclose

Duchenne Muscular Dystrophy (DMD)

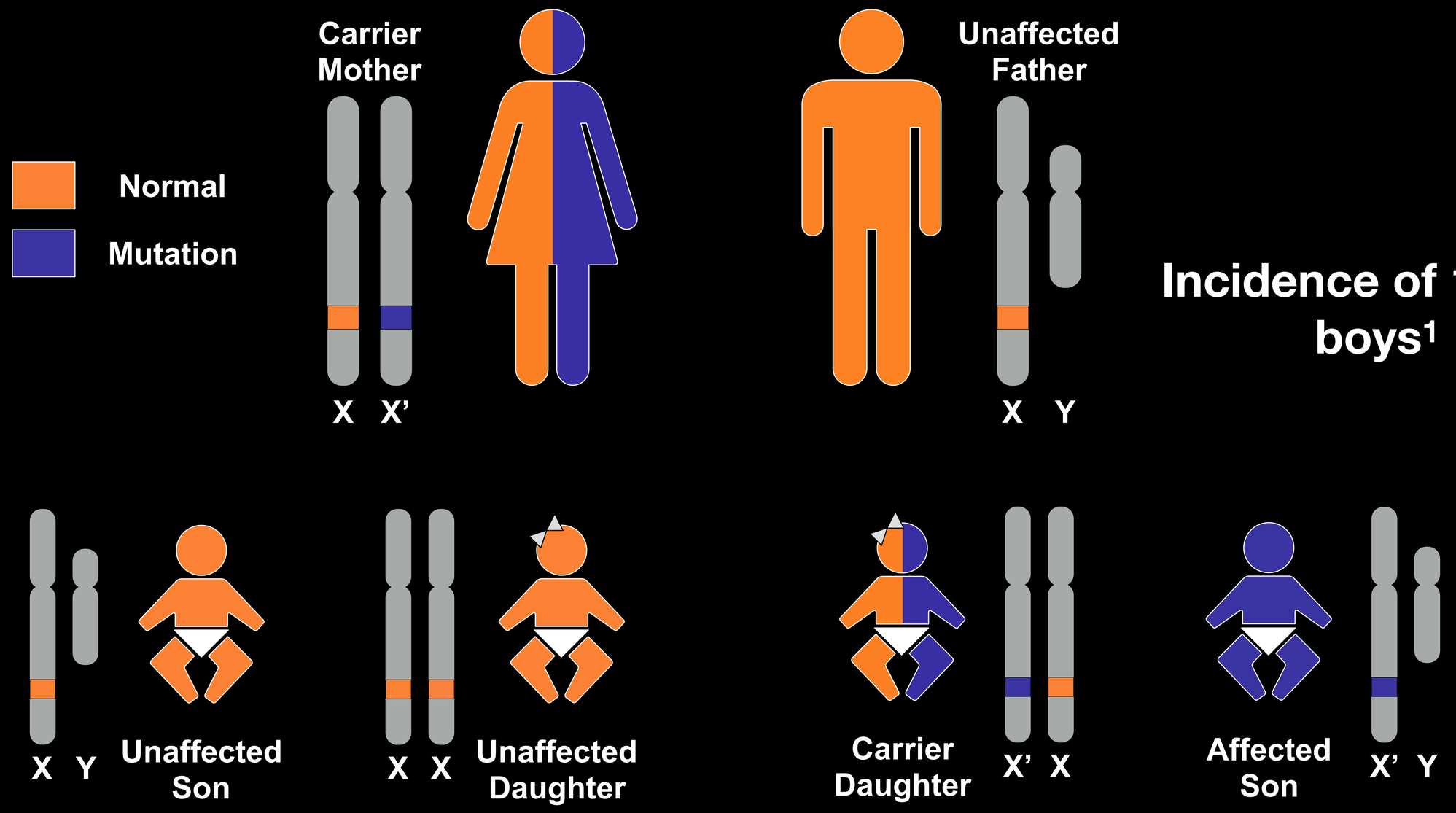

Incidence of 1:3500 boys[1]

UCLA Magnetic Resonance Research Labs

[1] McNally EM et al., Circulation (2015)

Duchenne Muscular Dystrophy (DMD)

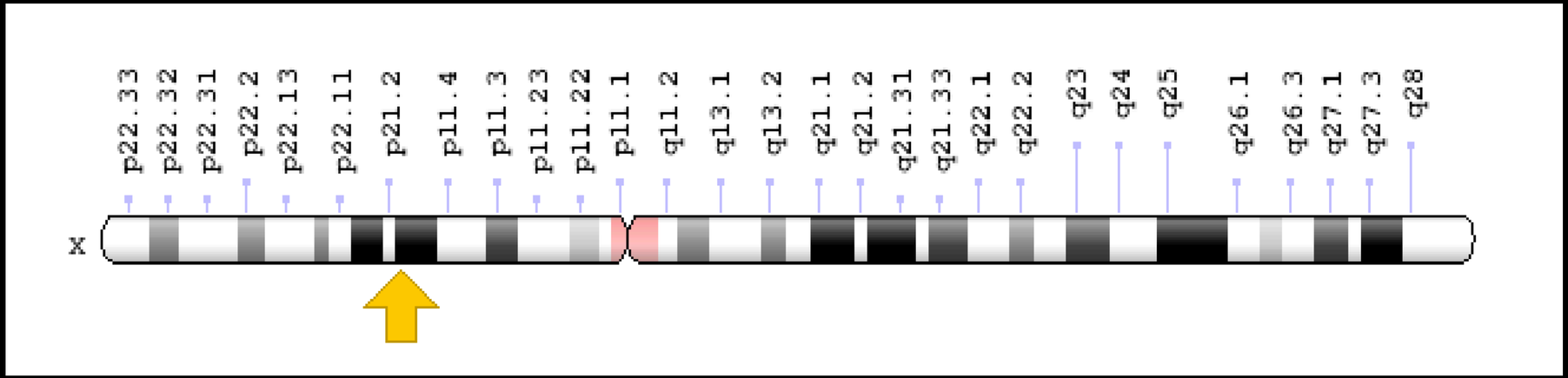

DMD gene is the largest known human gene - 2e6 basepairs

> 2,000 mutations in the DMD gene have been identified[2]

The genotype is variable, therefore the phenotype is variable.

UCLA
Magnetic Resonance Research Labs

[2] NCBI Gene [https://www.ncbi.nlm.nih.gov/gene/1756]

Duchenne Muscular Dystrophy (DMD)

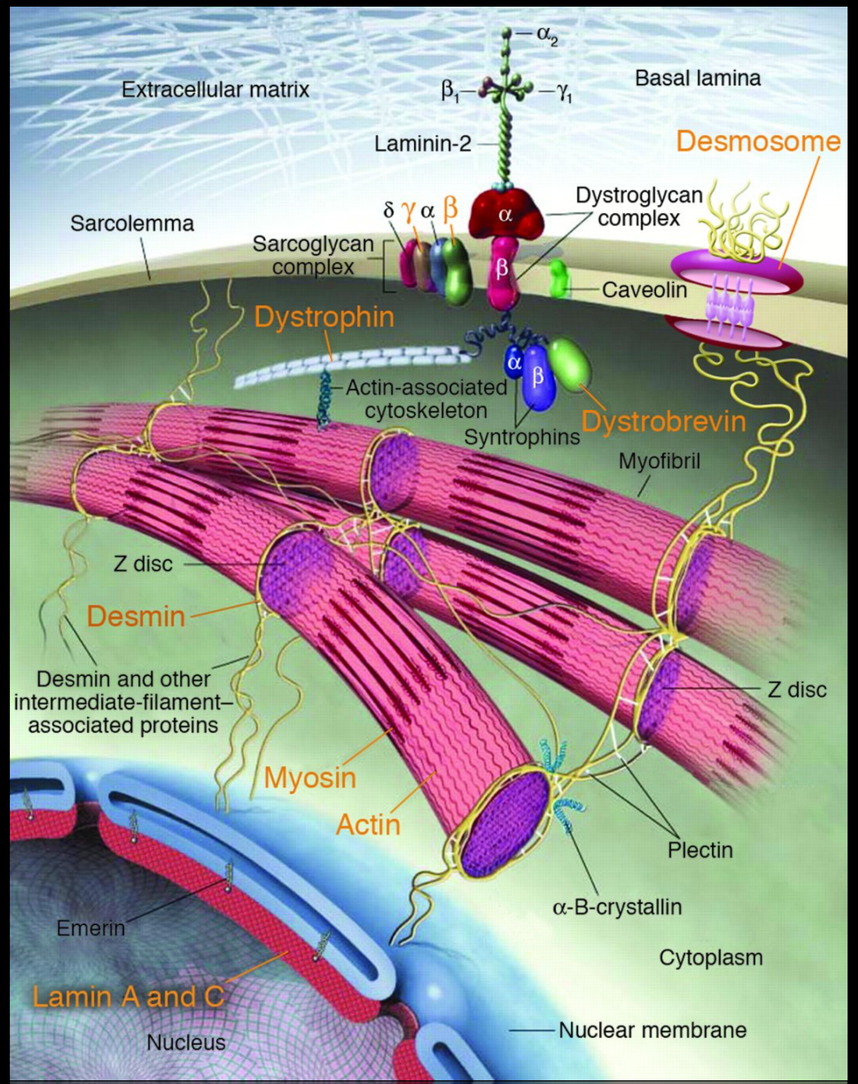

Dystrophin Protein

- Links sarcomere and extracellular matrix
- Mutation disrupts link to extracellular matrix
    - Causing tears in cellular membrane during myocyte contraction

UCLA
Magnetic Resonance Research Labs

DMD - Histology

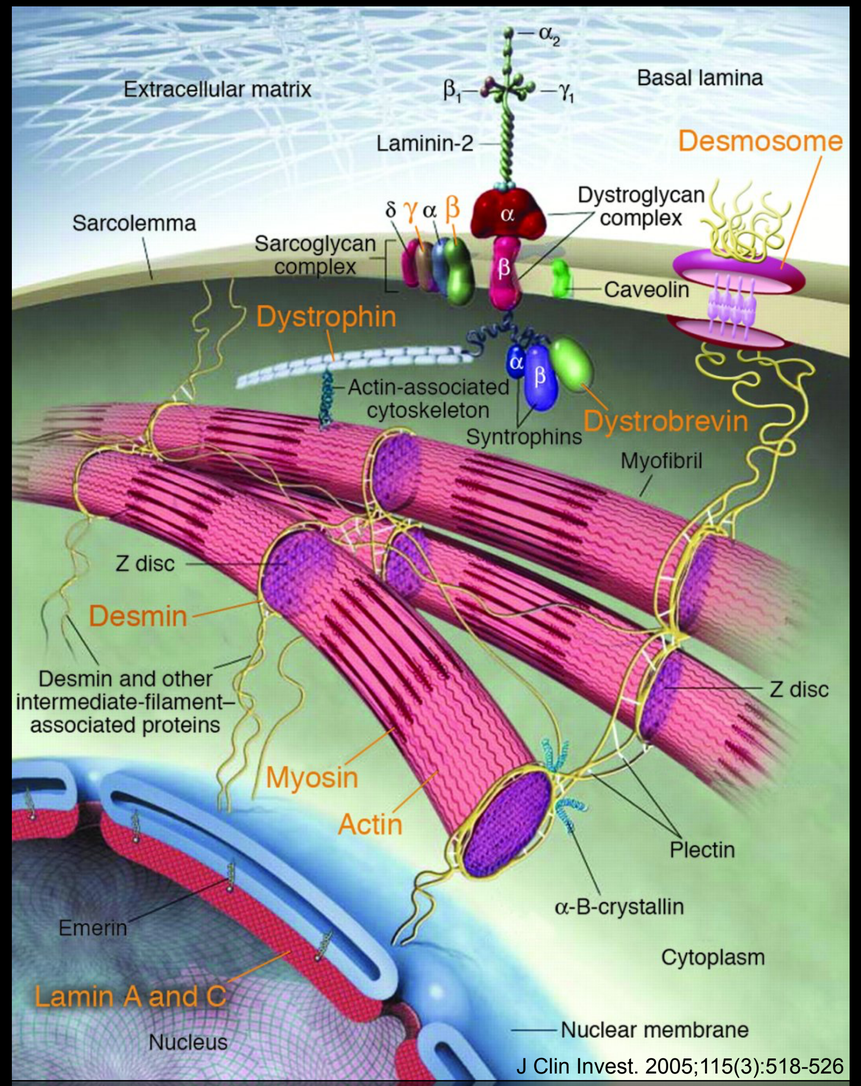

J Clin Invest. 2005;115(3):518-526

DMD Muscle

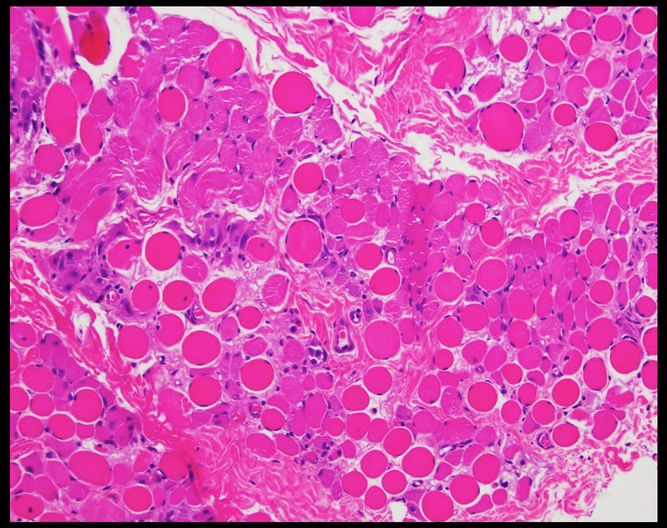

- Myofiber size variation
- Fatty replacement, myofiber splitting, and hypertrophy
- Atrophic fibers and fibrofatty replacement

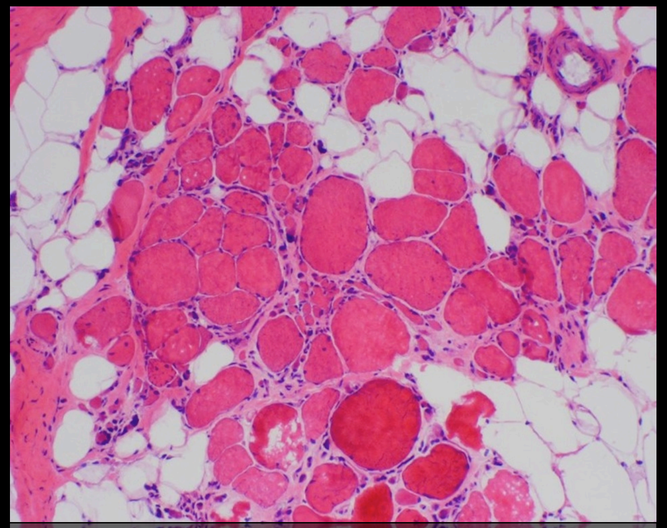

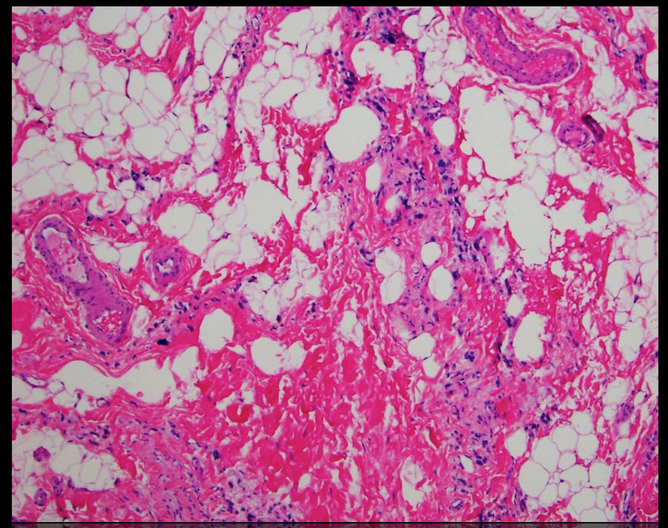

Hiser, W. Duchenne muscular dystrophy. PathologyOutlines.com website.

DMD - Progression

Skeletal Muscle → Respiratory Muscle → Cardiac Muscle →

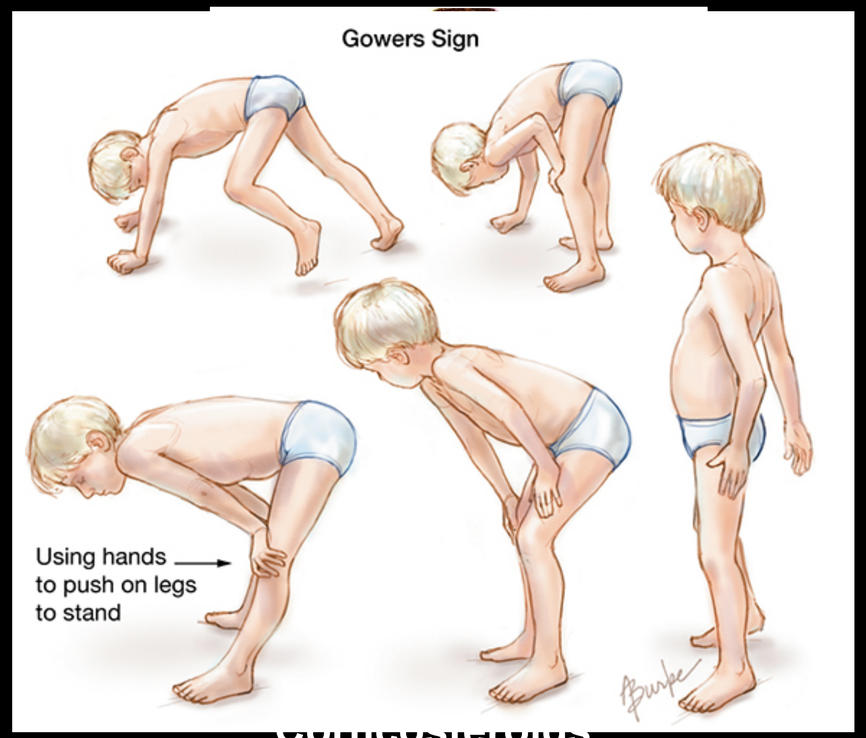

Corticosteroids

Airway Clearance
Muscle Training
Ventilation

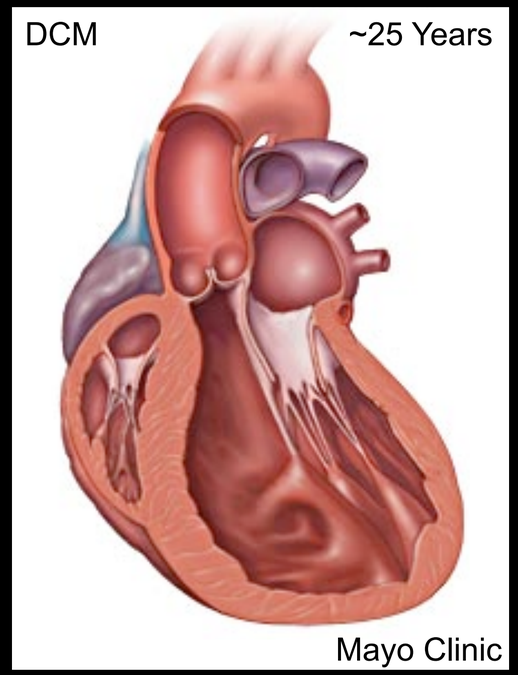

ACE Inhibitors
ß-blockers
Resynchronization

DMD - Role of CMR

Imaging shows that there is clearly disease in the myocardium long before onset of clinical symptoms[4].

Short Axis CINE

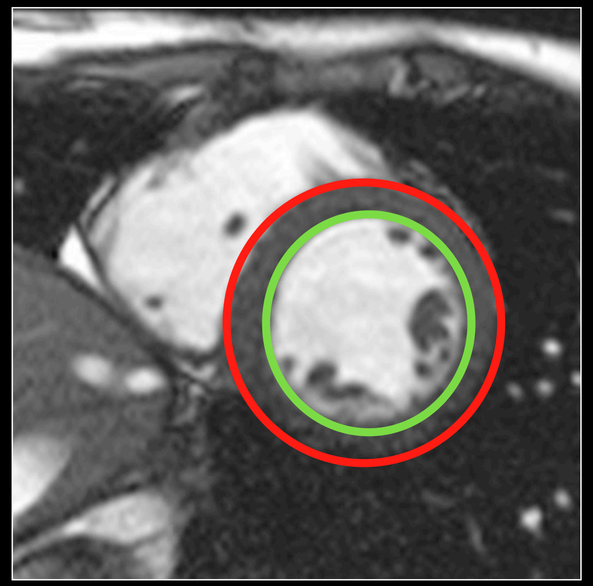

EF >> Reduced EF

LGE Imaging

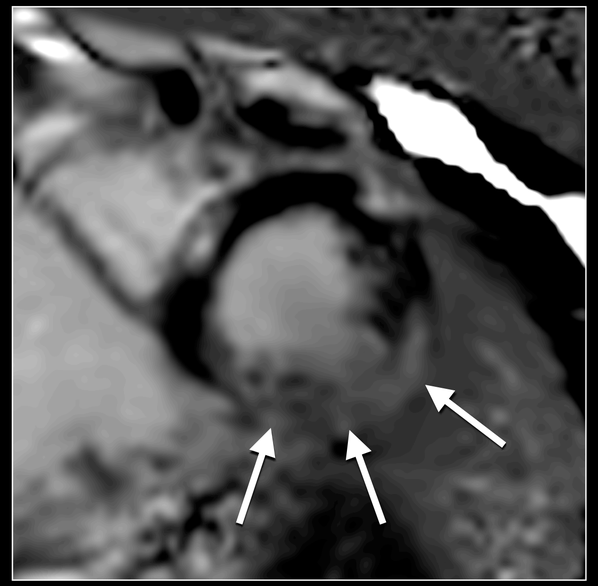

Enhancement >> Scar

The genotypic/phenotypic variations blur the line of cardiac involvement

Important to determine biomarkers **most sensitive** to cardiac involvement in DMD

Often noted as late outcomes in DMD.

UCLA Magnetic Resonance Research Labs

[4] Bushby et al., Lancet Neurol. (2010)

T1 Mapping in DMD at 1.5T

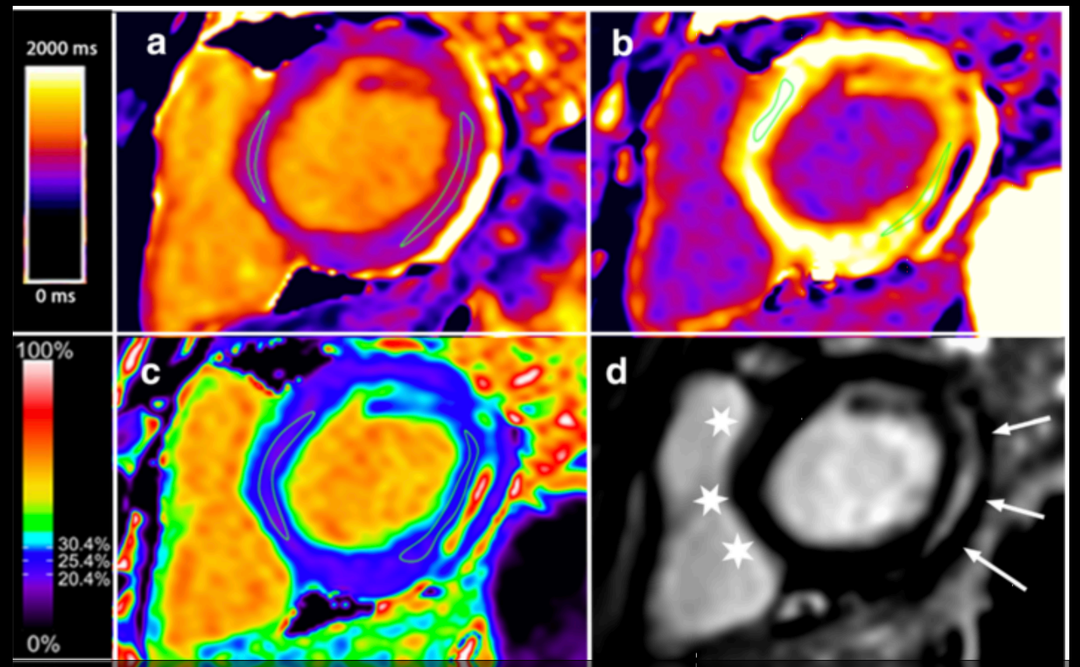

Mavrogeni et al, JCMR 2016

Pre-contrast T1 is a non-invasive measure of myocardial remodeling and potential early indicator of cardiac disease.

T1 measurements in boys with DMD acquired at 1.5T may identify myocardial changes and assess disease severity [5].

Extracellular volume (ECV) can be calculated and used to quantify diffuse fibrosis[6].

	Native T1 (ms)
	Lateral
DMD	1075.1(71.8)
CONTROL	978.2(36.4)
p	0.000

[5] Mavrogeni et al., JCMR (2016)

[6] Jerosch-Herold et al., Am. J. Physiol. Heart Circ. (2008)

Objective

To characterize differences in global and septal myocardium between boys with DMD and healthy controls at 3T. Pre-contrast T1, post-contrast T1, and ECV estimates.

UCLA
Magnetic Resonance Research Labs

Results: Demographics

	DMD (**N=26**) Median (IQR)	Control (**N=17**) Median (IQR)	Mann-Whitney *P* value
Age (years)	13(5.0)	13(4.0)	>0.05
Height (cm)	134(26.0)	165(20.3)	<0.01
Weight (kg)	50(26.3)	51.3(15.3)	0.61
Body mass index (kg/m^2)	25.9(9.5)	18.2(3.38)	<0.01
Heart rate (bpm)	87(24)	69(30)	0.02
Hematocrit (%)	43.5(3.6)	-	-

UCLA
Magnetic Resonance Research Labs

Methods - DMD MRI EXAM at 3T

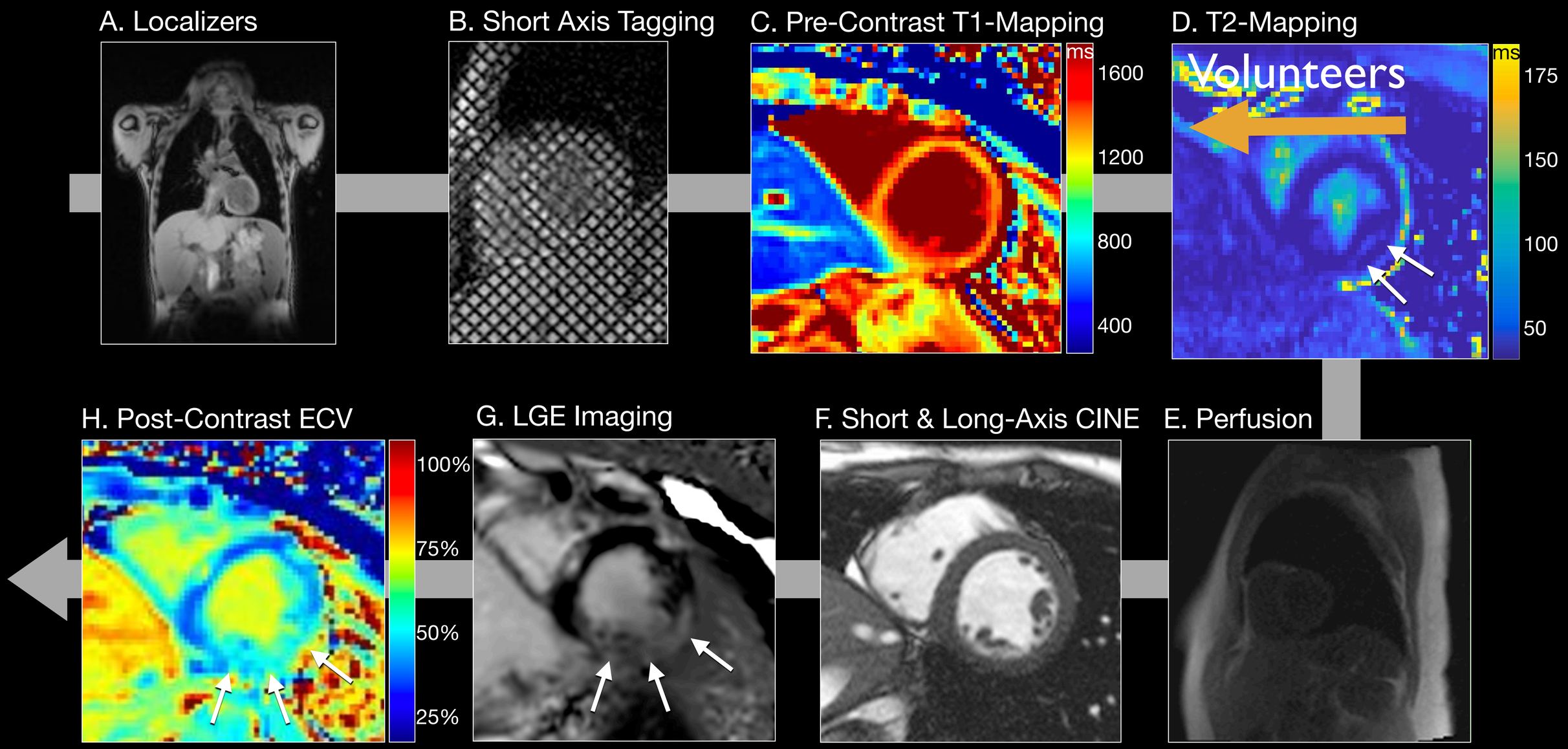

Magrath P. *et al*., Biomarkers in Medicine (2018).

Methods - Acquisition Parameters

Sequence Parameter	MOLLI HR < 90	MOLLI HR > 90
FOV (mm)	360 x 270	360 x 270
Matrix (mm^2)	192x164	192x164
Resolution (mm^3)	2x2x8	2x2x8
Slice thickness (mm)	8	8
TE (ms)	1.12	1.01
TR (ms)	2.7	2.44
Flip angle (∘)	20	20

Methods - Data Analysis

CMR

Patients
Pre- & Post-contrast T1
ECV

Volunteers
Pre-contrast

Single mid-ventricular slice

ROI Selection

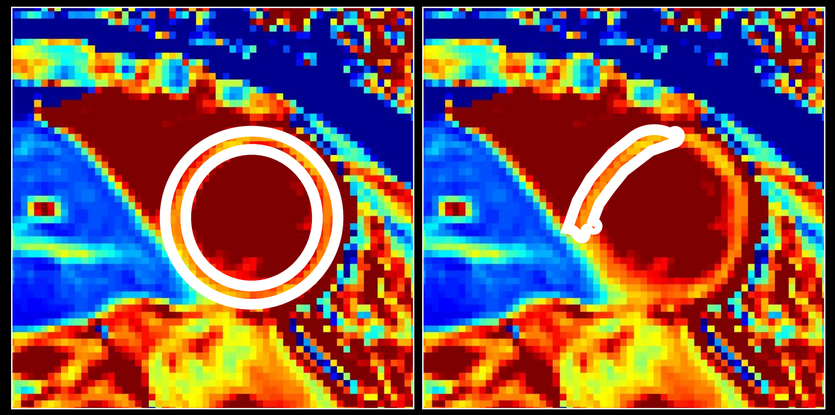

Global Septal

Extract summary statistics

UCLA
Magnetic Resonance Research Labs

Methods - Data Analysis

CMR

Patients
Pre- & Post-contrast
T1

Single mid-ventricular slice

Pre-Contrast

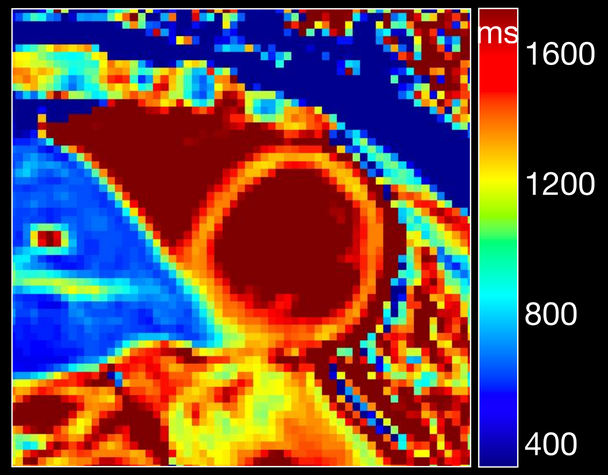

ROI Selection

Register Pre+Post
Blood pool T1
Hematocrit

Post-Contrast ECV

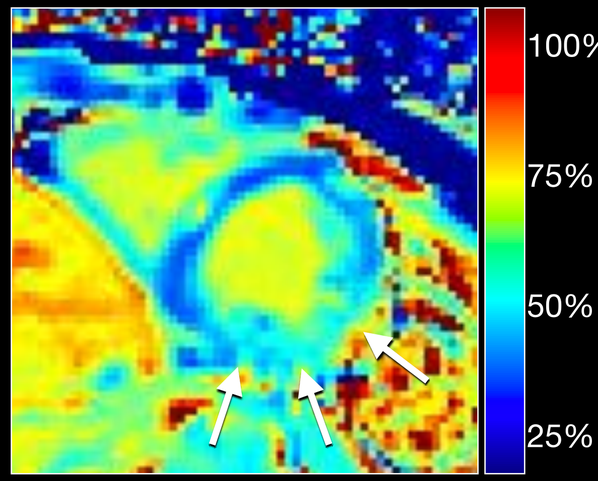

Extract summary statistics
Report Median (IQR)

UCLA
Magnetic Resonance Research Labs

Results - Increased Pre-contrast T1 in DMD Subjects

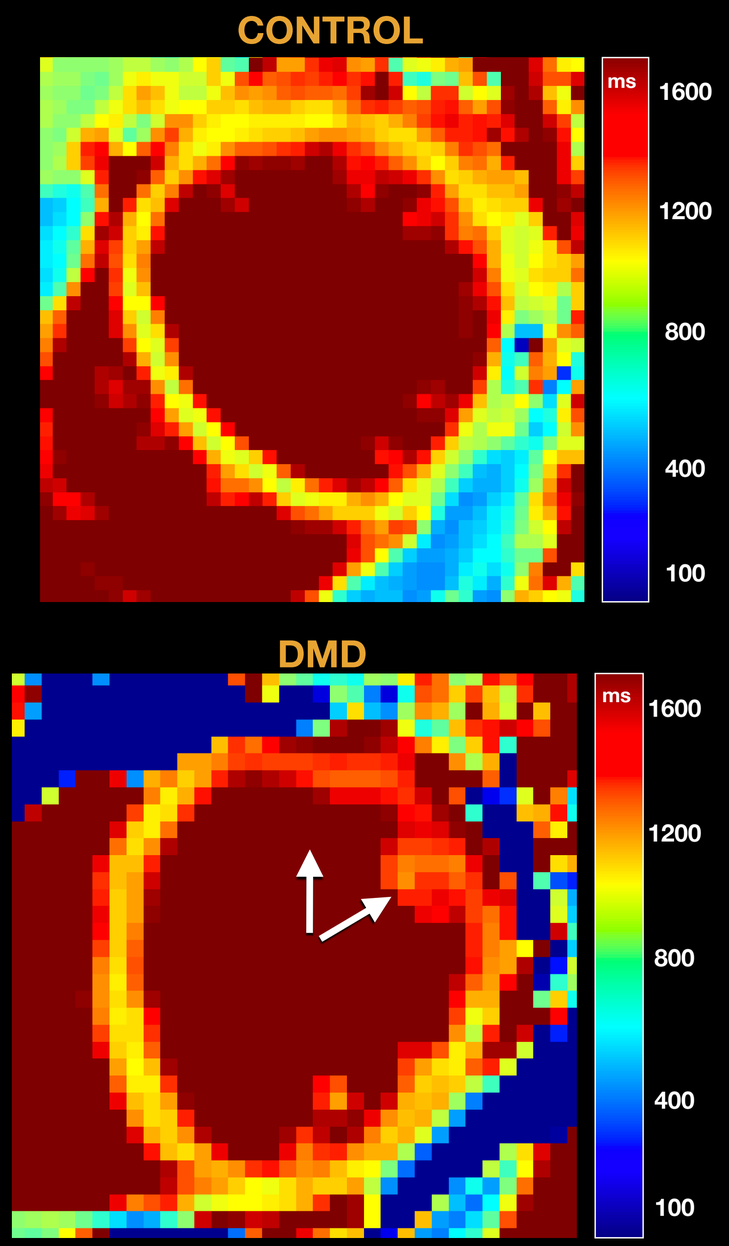

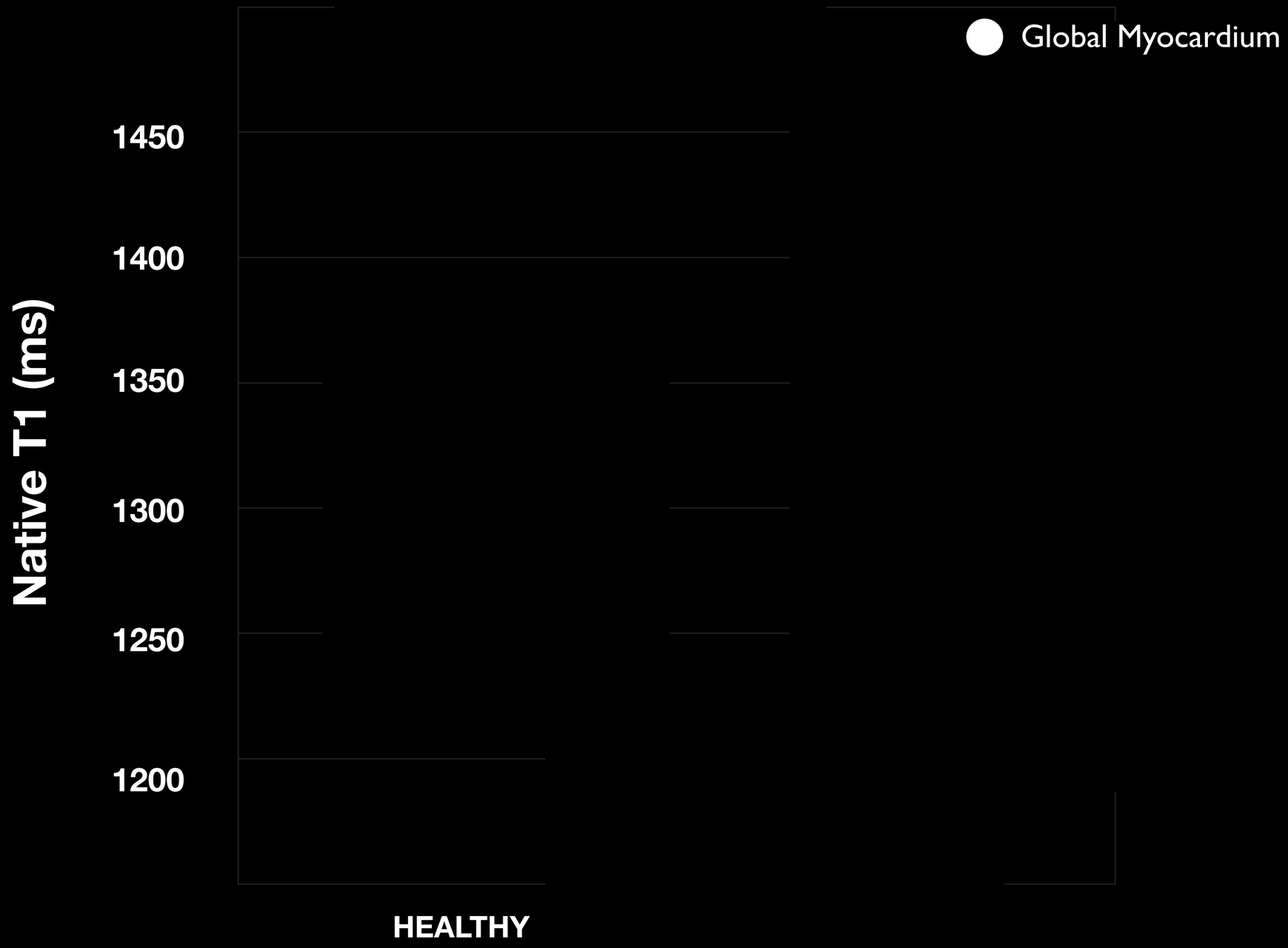

Results - Decreased Pre-contrast T1 in Septal Region

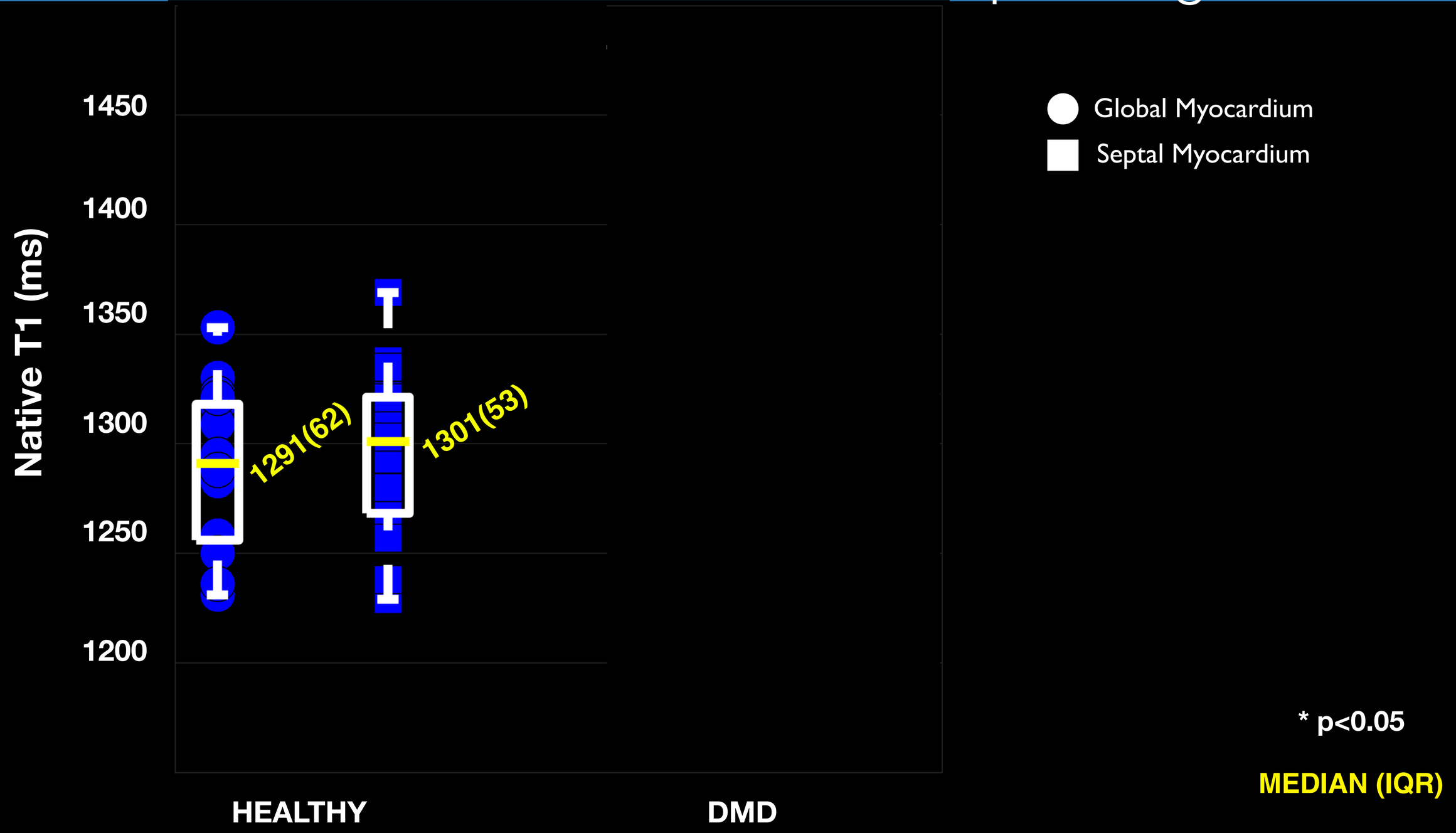

Results - Decreased Pre-contrast T1 in Septal Region

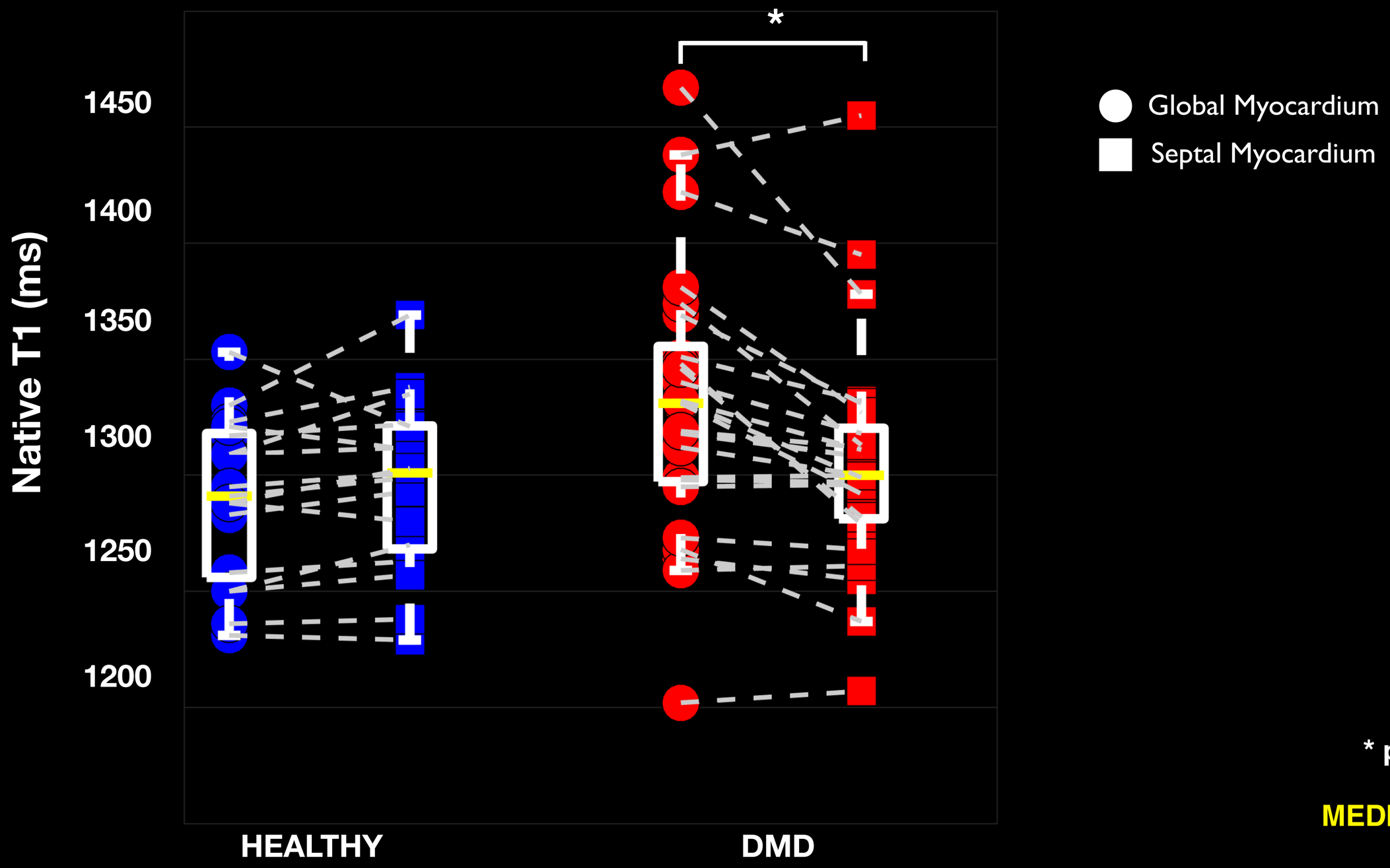

* p<0.05

MEDIAN (IQR)

Results - Increased Post-contrast T1 in DMD Septum

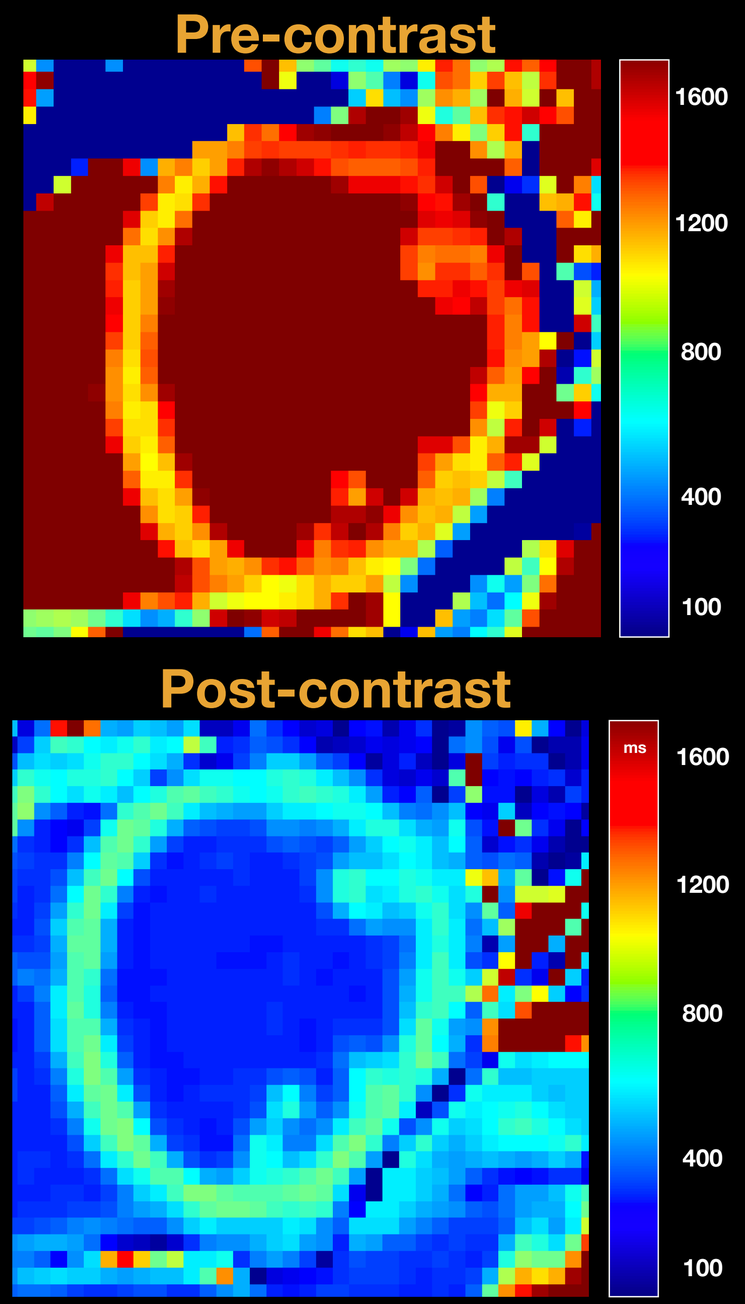

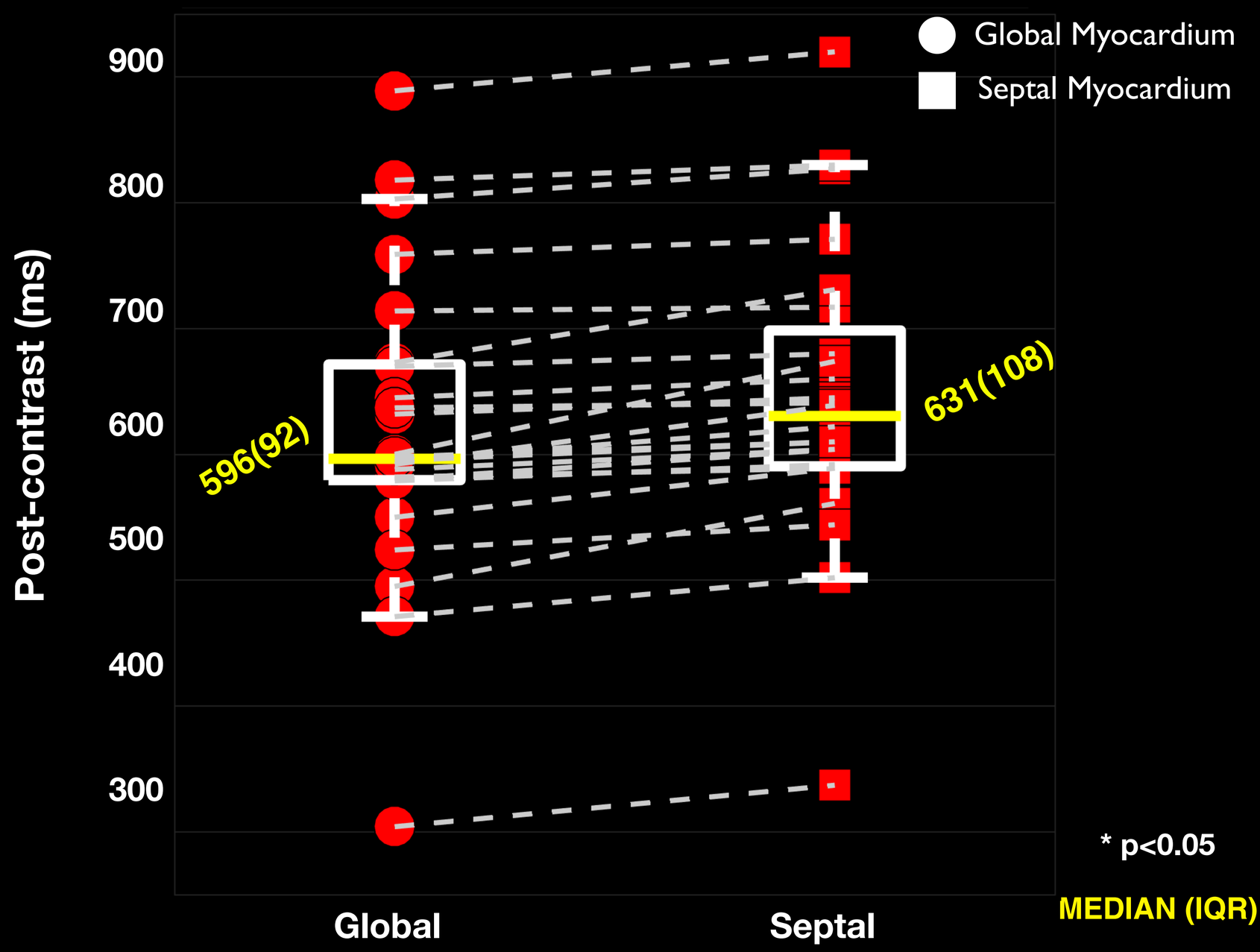

Results: Decreased ECV in DMD Septum

ECV Map

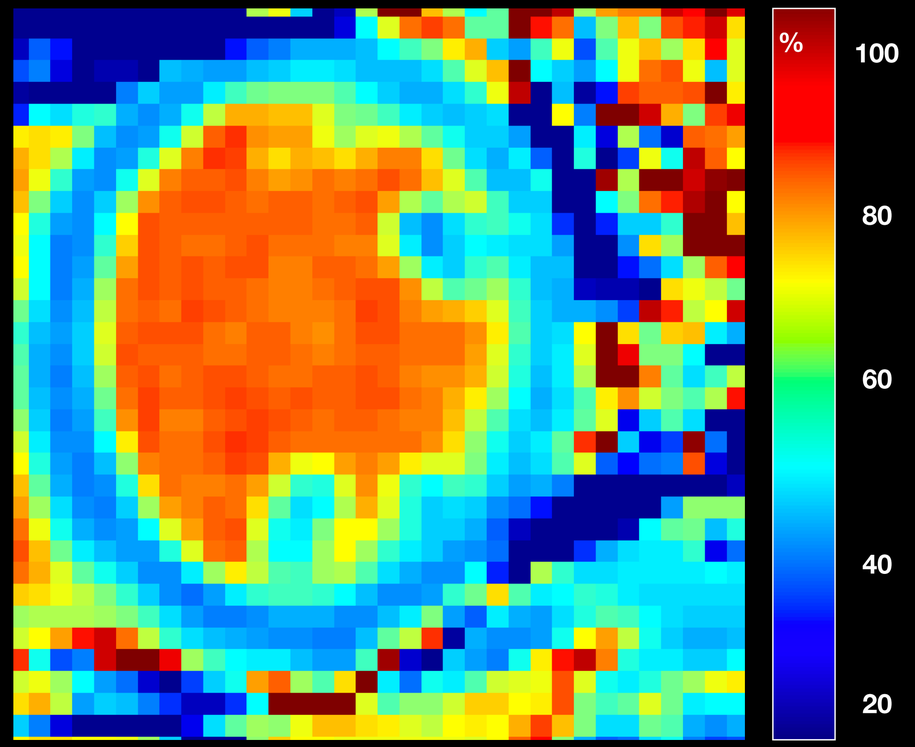

Previously reported ECV values[5] :

DMD: 31.3(6.7)

CONTROL: 24.4(3.5)

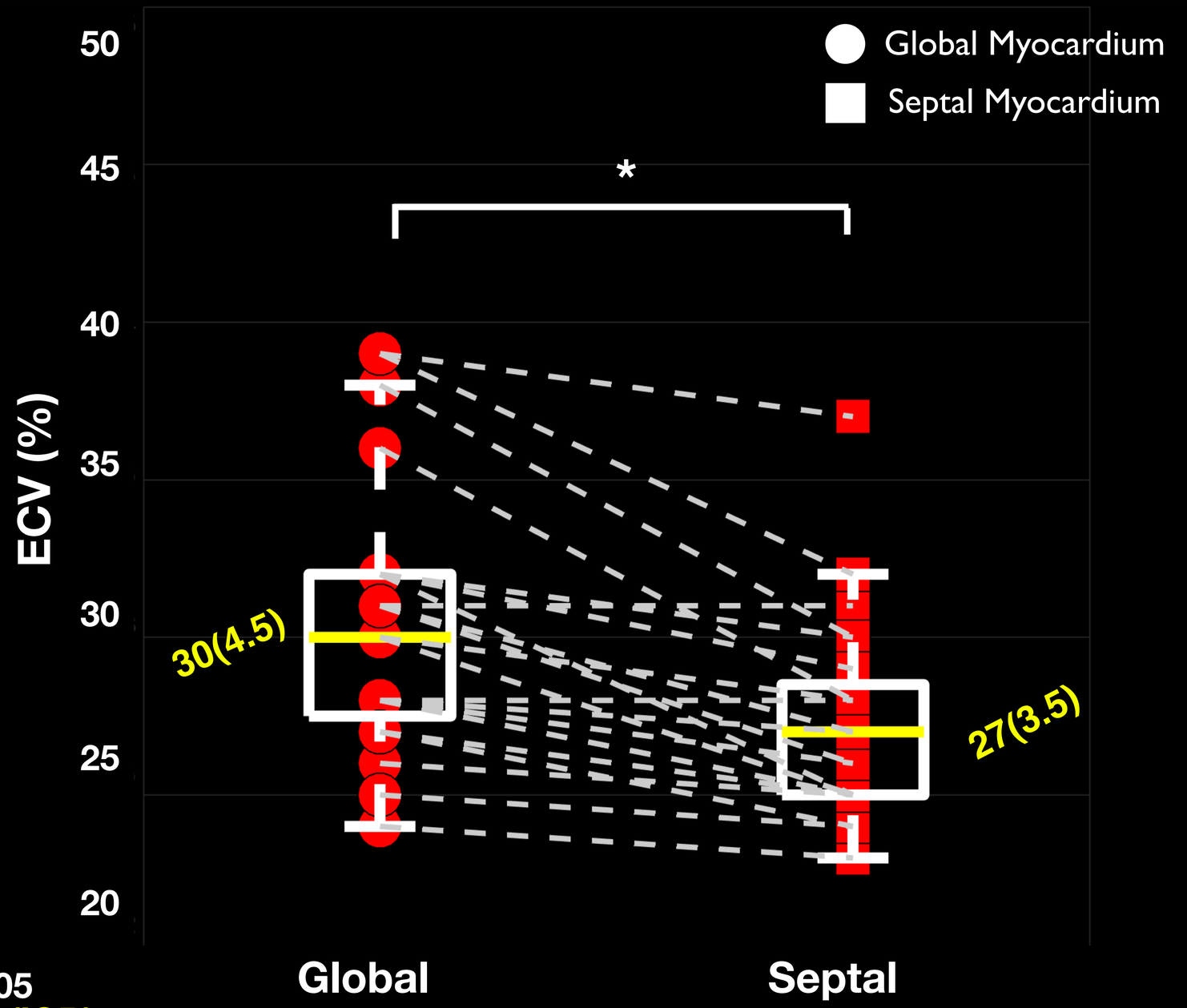

* p<0.05

MEDIAN (IQR)

[5] Mavrogeni et al., JCMR (2016)

Discussion - Variable Disease Progression

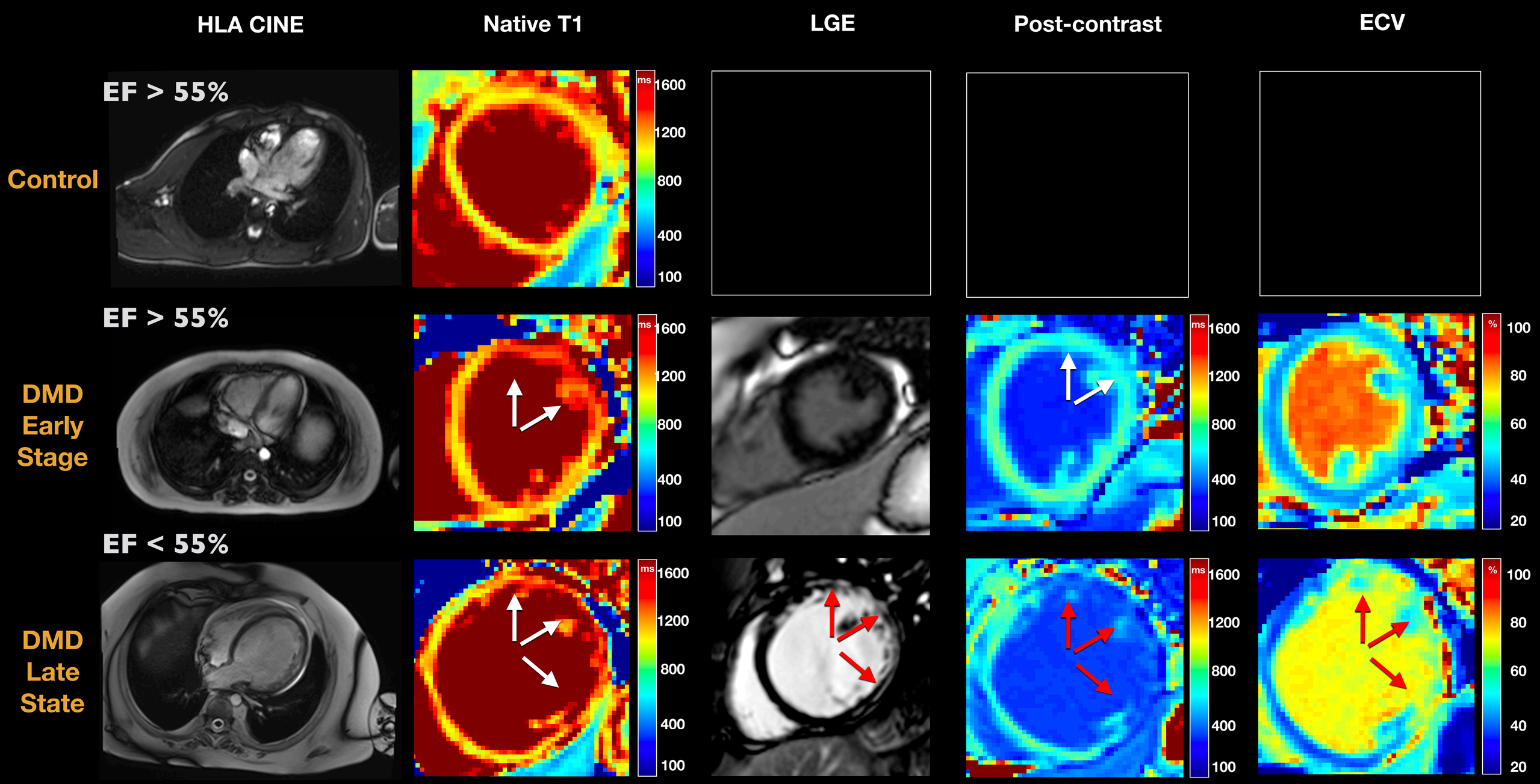

Discussion & Conclusions

- Boys with DMD present with significantly elevated pre-contrast T_1 compared to healthy boys.
  - As expected 3T T_1 values here are elevated relative to previously reported 1.5T values for DMD and healthy groups.
- Post-contrast T1 and ECV estimates are reported here for boys with DMD at 3T for the first time
- Global Myocardial values more elevated compared to the septum for DMD boys.

UCLA
Magnetic Resonance Research Labs

Acknowledgements

Funding support from:

NIH RO1 HL131975 to DBE

NSF DGE 1650604 to NGM

Research Team

Pierangelo Renella, MD
Nancy Halnon, MD
Ashley Prosper, MD
Stanley Nelson, PhD
Holden Wu, PhD
Daniel B. Ennis, PhD
Jiaxin Shao, PhD
Zhaohuan Zhang
Kavya Umachandran

Technologists

Glen
Nick
Sergio
Terry
Arnulfo

Ennis Lab @ Stanford | VA

UCLA
Magnetic Resonance Research Labs